U.S. Department
of Transportation
**National Highway
Traffic Safety
Administration**

DOT HS 808 157

July 1992

Final Report

The Medical Consequences of Car Crashes: An Automobile Crash Trauma Study

Volume: II

This document is available to the public from the National Technical Information Service, Springfield, Virginia 22161.

This publication is distributed by the U.S. Department of Transportation, National Highway Traffic Safety Administration, in the interest of information exchange. The opinions, findings and conclusions expressed in this publication are those of the author(s) and not necessarily those of the Department of Transportation or the National Highway Traffic Safety Administration. The United States Government assumes no liability for its contents or use thereof. If trade or manufacturers' name or products are mentioned, it is because they are considered essential to the object of the publication and should not be construed as an endorsement. The United States Government does not endorse products or manufacturers.

Technical Report Documentation Page

1. Report No. DOT HS 808 157	2. Government Accession No.	3. Recipient's Catalog No.
4. Title and Subtitle The Medical Consequences of Car Crashes: An Automobile Crash Trauma Study		5. Report Date July 15, 1992
		6. Performing Organization Code 52-600203(EIN)
7. Author(s) Siegel J, Dischinger P		8. Performing Organization Report No. FINAL REPORT
9. Performing Organization Name and Address Maryland Institute for Emergency Medical Services Systems 22 South Greene Street Baltimore, MD 21201		10. Work Unit No. (TRAIS)
		11. Contract or Grant No. DTNH 22-88-C-07007
12. Sponsoring Agency Name and Address Department of Transportation National Highway Traffic Safety Administration Washington, DC 20590		13. Type of Report and Period Covered Final 10/01/88 - 12/31/91
		14. Sponsoring Agency Code NAD-30

15. Supplementary Notes

16. Abstract

The objective of this multi-disciplinary study was to characterize the causes and consequences of injuries to vehicle occupants admitted to a trauma center as a result of high-speed crashes. The study includes data on 145 patients admitted to MIEMSS as a result of 128 crashes. Patients with an injury severity score (ISS) of at least 16 were eligible for inclusion. Detailed information was obtained on injury diagnoses, operative procedures and complications; in addition, photographs of injuries were taken by a trauma surgeon. Details of pre-hospital care were obtained from interviews with field providers. The study social worker obtained background information on the patient, the family, and any pre-crash "stressors" which might have played a role in the crash. Financial information on the charges for hospital care and professional fees were also obtained for each case. For patients with head injuries, data were obtained by a speech pathologist. Finally, for fatalities, autopsy reports were obtained from the Office of the Chief Medical Examiner.

Specific aims, methods, findings, and conclusions of the study are presented in Volume 1 of the Final Report. Timeline narratives for each of the study cases are presented in Volumes 2, 3, and 4, representing years 1, 2, and 3 respectively.

17. Key Words Trauma, Car Crashes, Biomechanics, Intrusion, Contact Points, Extrication, Psychosocial factors		18. Distribution Statement Document is available to the U.S. Public through the National Technical Information Service, Springfield, Virginia 22161	
19. Security Classif. (of this report) Unclassified	20. Security Classif. (of this page) Unclassified	21. No. of Pages	22. Price

Form DOT F 1700.7 (8-72) Reproduction of form and completed page is authorized

THE MEDICAL CONSEQUENCES OF CAR CRASHES: An Automobile Crash Trauma Study

List of Authors, Their Organizations, and Contracts for the Final Report of the Study

This Automobile Crash Trauma Study is multidisciplinary; the full set of study participants, their organizations and contract numbers are as follows:

MIEMSS:

John H. Siegel, M.D.* (Principal Investigator, Trauma Surgeon)
Patricia C. Dischinger, Ph.D. (Co-Principal Investigator, Epidemiologist)
Brad M. Cushing, M.D. (Trauma Surgeon)
Stephanie Mason-Gonzalez, M.D. (Trauma Surgeon)
Kathleen Read, M.S.W. (Social Worker)
Richard M. Robinson, M.S. (Speech Pathologist, Cognitive/ Communicative Assessment)
Karen Parkison, M.S. (Pre-Hospital Data Coordinator)
Shirin Goodarzi, M.S. (Statistician)
Shahid Shafi, M.D., MPH (Health Care Economics Analyst)
John D. Dailey, M.P.A. then Wendie J. Hill, M.P.A., Roger Glick, B.S. (Medical Data Coordination)
Shiu Ho, M.S. (Programmer Analyst)
Ron M. Kropp, M.P.H. (Administrator)

OFFICE OF THE CHIEF MEDICAL EXAMINER

John E. Smialek, M.D. (Chief Medical Examiner, State of Maryland)
Barry Heatfield, Ph.D. (Pathologist)

DYNAMIC SCIENCE, INC.

Frances D. Bents (Manager, Crash Investigation Team)
"Doc" Livingston (Crash Reconstructionist)
Jerry Jackson (Crash Reconstructionist)
Tina Catalfano (Research Assistant)

STATCOM, INC.

David A. Downing (Manager, Crash Comparisons)

GESAC, INC.

N. Rangarajan, Ph.D. (Manager, Occupant Motion Computer Simulation)
Pariq Shams, Ph.D.

NHTSA

Carl C. Clark, Ph.D. then Jeffrey Marcus Ph.D., then Nopporn Khaewpong, Ph.D. (Contract Officer's Technical Representative)

Contract Numbers:

MIEMSS: Contract DTNH22-88-C-07007
Dynamic Science: Contract DTNH22-88-C-07015
Statcom, Inc.: Contract DTNH22-88-C-07237 (contract by NHTSA for Year 1 only)
GESAC, Inc: Subcontract of Contract DTNH22-88-C-07237 (contract by NHTSA for Year 1 only)

Titles and Current Addresses of Investigators:

John H. Siegel, M.D.
Director, New Jersey Trauma Center
Chairman: Department of Anatomy, Cell Biology, and Injury Life Sciences
New Jersey Medical School UMDNJ
Trauma Center [E245]
150 Bergen Street,
Newark, New Jersey 07103 (201-456-4004)

Patricia C. Dischinger, Ph.D.
Epidemiologist, National Study Center for Trauma/EMS
Maryland Institute for Emergency Medical Services Systems (MIEMSS)
University of Maryland at Baltimore,
22 South Greene St.
Baltimore, Maryland 21201 (410-328-4246)

John E. Smialek, M.D.
Chief Medical Examiner, State of Maryland

Fran D. Bents
Manager, Crash Investigation Team
Dynamic Science, Inc., an Exodyne Company
524 College Parkway, Suite C
Annapolis, Maryland 21401 (301-858-7028)

David A. Downing
Manager, Crash Comparisons
Statcom, Inc.
7925 Westpark Drive
McLean, Virginia 22102 (703-893-5959)

N. Rangarajan, Ph.D.
Manager, Occupant Motion Computer Simulation
GESAC, Inc.
8607 Second Avenue, Suite 306
Silver Spring, Maryland 20910 (301-585-7166)

Carl C. Clark, Ph.D.
Safety Systems Company
23 Seminole Ave.
Baltimore, Maryland 21228-5638 (301-747-1396)

Jeffrey H. Marcus, Ph.D.
Manager, Protection and Survival Laboratory
Civil Aeromedical Institute (CAMI)
Federal Aviation Administration,
U.S. Department of Transportation
AAM-630
Mike Monroney Aeronautical Center
P.O. Box 25082
Oklahoma City, Oklahoma 73125 (405-680-5500)

TIMELINES

(Note: year 1 includes cases with sequential numbers 001-037; year 2 includes numbers 038-100; year 3 includes 101-145.)

YEAR #1 (VOLUME I)

SEQ NUM	NHTSANO
001	414
002	088
003	110
004	484
005	365
006	368
007	418
008	169
009	272
010	052
011	038
012	366
013	199
014	124
015	361
016	251
017	226
018	427
019	400
020	004
021	117
022	102
023	342
024	091
025	466
026	160
027	126
028	420
029	312
030	064
031	054
032	107
033	080
034	156
035	486
036	129
037	356

Note: Cases were assigned a random 3-digit number (NHTSANO) to insure confidentiality. This listing shows the NHTSANO with their corresponding sequential numbers, indicating the order of the cases entered into the study.

The index to selected characteristics of study cases presented on the following pages contains the sequential number only.

INDEX OF CASES BY SELECTED CHARACTERISTICS

I. Type of Injury
II. Crash Mechanisms
III. Drug and/or Alcohol Use
IV. Age of Subject
V. Type of Vehicle

I. TYPE OF INJURY:

Brain Injury

002 004 008 013 014 016 019 020 021 023 024 025 026 028 030 031
034 039 042 046 048 051 055 059 060 061 062 064 065 066 069 070
073 074 075 076 077 078 083 084 088 089 092 096 102 103 104 105
107 108 109 114 115 119 120 121 122 124 125 126 129 130 131 132
133 135 138 141 143 145

Lower Extremity Fracture

001 002 004 006 007 010 011 014 018 021 022 023 026 027 028 029
030 033 035 036 037 039 042 044 045 047 048 049 053 056 058 060
061 062 065 067 068 069 070 071 076 077 080 083 084 086 087 092
093 094 096 097 098 105 107 111 112 113 117 122 123 130 132 137
139 140 141 142 143 144

Pelvis Fracture

003 004 005 007 013 014 017 019 025 027 033 039 040 042 043 044
046 052 053 054 060 064 067 071 073 084 088 094 095 105 106 107
110 111 113 114 120 121 123 124 127 130 132 133 138 139 142 143
144 145

Liver, Spleen or Bowel Injury

002 004 005 006 009 012 013 014 021 024 026 027 032 035 037 038
046 050 052 054 057 058 063 070 075 077 082 084 085 086 088 090
094 095 096 099 106 113 114 116 122 124 134 137 143 144 145

Spinal cord / Column

003 010 015 016 019 045 051 056 065 066 067
072 074 083 085 086 088 091 097 102 118 128

Thorax/Chest or Heart Injury

001 003 004 005 007 009 010 011 013 014 017 018 019 023 024 025
027 029 030 032 036 038 039 040 041 042 043 044 045 046 049 051
052 054 055 056 057 058 059 062 063 065 066 069 070 074 075 077
080 081 083 084 085 087 088 089 090 091 093 095 096 097 098 099
101 102 106 107 110 113 114 116 117 119 121 123 124 132 133 134
135 137 138 139 141 142 145

Death

006 013 014 020 024 031 039 043 045 048 052 053
058 059 062 068 072 075 083 084 089 091 093 096
098 102 103 104 107 109 117 121 123 126 133 135
138 139 142

II. CRASH MECHANISMS

Point of Impact and Occupant:

FRONTAL CRASH, DRIVER

004 006 007 009 011 012 015 019 020 021 022 023 029
031 033 034 035 036 037 040 041 043 047 048 049 052
053 056 058 062 064 065 066 068 069 070 073 076 077
079 080 081 085 086 087 092 103 107 108 112 113 122
123 124 133 135 136 140 143

FRONTAL CRASH, PASSENGER

008 018 027 028 038 045 050 078 082 083 093 098 121
134 137 139 141

LATERAL CRASH, DRIVER

002 003 005 013 014 016 030 032 039 042 044 054 057
059 060 061 063 084 094 095 100 101 104 109 110 114
116 119 131 138 142

LATERAL CRASH, PASSENGER

001 017 024 025 046 096 097 099 105 111 115 132 144
145

ROLLOVER, OCCUPANT=UNK

127 128

ROLLOVER, DRIVER

010 051 074 088 091 117 120 130

ROLLOVER, PASSENGER

055 067 075 102 118 129

OTHER TYPE OF CRASH, OCCUPANT=UNK

125

OTHER TYPE OF CRASH, DRIVER

026 071 072 090

OTHER TYPE OF CRASH, PASSENGER

089 106 126

Air Bag Use

079 101

Point of Impact and Ejection/Extrication

FRONTAL CRASH, EJECTED

023 041 045 066 077 108

FRONTAL CRASH, EXTRICATED

004 006 007 008 011 015 018 019 020 021 022 028 029
031 033 035 036 037 038 047 049 050 052 053 056 058
062 064 065 068 069 070 073 076 078 080 081 082 083
086 087 092 093 098 103 107 112 113 122 123 134 135
136 137 139 140 141 143

FRONTAL CRASH, OTHER

009 012 027 034 040 043 048 079 085 121 124 133

LATERAL CRASH, EJECTED

001 005 017 116 119

LATERAL CRASH, EXTRICATED

002 003 013 014 016 024 025 030 039 042 044 046 054
060 061 063 084 094 095 096 099 100 105 109 110 111
114 115 131 132 138 142 145

LATERAL CRASH, OTHER

032 057 059 097 101 104 144

ROLLOVER, EJECTED

010 051 055 067 074 088 091 117 120 127 128

ROLLOVER, EXTRICATED

075 102 118 129 130

OTHER CRASH, EXTRICATED

026 071 072 089 106 126

OTHER CRASH, NEITHER EXTRICATED NOR EJECTED

090 125

III. DRUG AND/OR ALCOHOL USE

003 005 007 010 013 015 019 022 023 040 042 044 048 051 053 055
059 061 064 066 067 071 073 076 077 080 085 087 090 091 092 098
101 102 104 108 112 116 117 120 125 127 128 129 130 131 132 136
140 142

IV. AGE OF SUBJECT

Age	Sequential Number										
14	045	093									
15	024	025	050	057	109	115	141				
16	039	083	110	111	138						
17	001	042	046	077	103	118					
18	020	034	037	066	095	096	121	126	130	144	145
19	008	051	067	080	094	098	136				
20	003	009	010	014	027	054	058	062	116	129	139
21	060	101									
22	071	125									
23	120										
24	004	026	076	123							
26	012	013	017	088	127						
27	090	143									
28	030	102	132								
29	005	041	063	092							
30	035	064	112	113							
31	023	086	104	122	128						
32	002	069	089	131							
33	056	097									
35	055	079	087	140							

Age	Sequential Number			
36	018	073	108	
37	019			
38	007	044	070	117
40	011	022	061	082
41	031			
42	038	065	137	
43	078	099	114	
44	021	036	100	
45	006	015	052	068
50	047			
52	133			
54	016	032	040	
57	033			
59	105			
60	048	049		
61	029	053	134	
62	084			
64	074	075	107	
66	091			
67	085			
68	106	135		
69	124			
70	119			
72	081			
75	072			
77	028	142		
85	059			
89	043			

V. TYPE OF VEHICLE

CRASH NUM**	NHTSANO	SEQ NUM	CASE*	VEH NUM	MAKE	MODEL	MODEL YEAR
4	4	20	1	1	9)PLYMOUTH	SUNDANCE	88
4	4	20	.	2	85)TB/KENWORTH	TRK/BUS MED/HEAVY-COE/HIGH ENTRY	84
17	17	45	1	1	20)CHEVROLET	CAVALIER	88
38	38	11	1	1	20)CHEVROLET	S-10 BLAZER	87
38	38	11	.	2	22)PONTIAC	BONNEVILLE/CATALINA/PARISIENNE	85
38	38	11	.	3	6)CHRYSLER	NEW YORKER/NEWPORT/5TH AVE	87
48	48	46	1	1	18)BUICK	LESABRE/CENTURION/WILDCAT	90
48	48	46	.	2	23)GMC	JIMMY	89
52	52	10	1	1	37)HONDA	ACCORD	87
80	80	33	1	1	20)CHEVROLET	CELEBRITY	84
88	88	2	1	1	7)DODGE	OMNI/CHARGER(83 ON)	85
88	88	2	.	2	12)FORD	ESCORT/EXP	85
102	102	22	1	1	48)SUBARU	DL/FE/G/GF/GL/GLF/STD	87
107	107	32	1	1	6)CHRYSLER	NEW YORKER/NEWPORT/5TH AVE	85
107	107	32	.	2	20)CHEVROLET	C-SERIES PICKUP	88
110	110	3	1	1	30)VOLKSWAGEN	GOLF	87
117	117	21	1	1	41)MAZDA	MAZDA PICKUP	87
117	117	21	.	2	20)CHEVROLET	CORVETTE	85
124	124	14	1	1	12)FORD	RANGER	85
124	124	14	.	2	12)FORD	MEDIUM/HEAVY CBE	84
124	124	14	.	3	35)NISSAN/DATSUN	DATSUN/NISSAN PICKUP	82
124	124	14	.	4	20)CHEVROLET	CORVETTE	77
124	124	14	.	5	2)JEEP	CHEROKEE	87
124	124	14	.	6	52)MITSUBISHI	CORDIA	87
124	124	14	.	7	12)FORD	FIESTA	88
126	126	27	1	1	30)VOLKSWAGEN	VANAGON/CAMPER	68
126	126	27	.	2	21)OLDSMOBILE	CUTLASS(RWD-ONLY)	79
129	129	36	1	1	37)HONDA	ACCORD	88
129	129	36	.	2	23)GMC	G-SERIES VAN	87
156	156	34	1	1	37)HONDA	CIVIC/CRX	79
156	156	34	.	2	22)PONTIAC	FIREBIRD/TRANS AM	84
160	160	26	1	1	12)FORD	TEMPO	88
160	160	26	.	2	7)DODGE	CARVAN	89
199	199	13	1	1	35)NISSAN/DATSUN	STANZA	89
199	199	13	.	2	34)BMW	3-SERIES	87
226	226	17	1	1	20)CHEVROLET	CHEVELLE/MALIBU	81
226	226	17	.	2	12)FORD	MUSTANG/MUSTANG II	69
230	230	49	1	1	20)CHEVROLET	CAVALIER	87
230	230	49	.	2	87)TB/PETERBILT	TRK/BUS MED/HEAVY-COE/HIGH ENTRY	78
251	251	16	1	1	49)TOYOTA	CELICA	80
251	251	16	.	2	20)CHEVROLET	C-SERIES PICKUP	85
267	267	40	1	1	12)FORD	LTD/CUSTOM/GALAXIE (ALL SIZES)	88
272	272	9	1	1	55)HYUNDAI	EXCEL	87

CRASH NUM**	NHTSANO	SEQ NUM	CASE*	VEH NUM	MAKE	MODEL	MODEL YEAR
272	272	9	.	2	20)CHEVROLET	NOVA	73
302	302	38	1	1	12)FORD	LTD/CUSTOM/GALAXIE (ALL SIZES)	88
302	302	38	.	2	22)PONTIAC	FIREBIRD/TRANS AM	76
302	302	38	.	3	72)MC/HARLEY-DAVIDSON	MC/HARLEY-DAVISON 750CC+	76
302	302	38	.	4	72)MC/HARLEY-DAVIDSON	MC/HARLEY-DAVISON 750CC+	65
312	312	29	1	1	19)CADILLAC	DEVILLE/FLEETWOOD	88
312	312	29	.	2	2)JEEP	CHEROKEE	89
328	328	50	1	1	20)CHEVROLET	CAVALIER	84
333	333	42	1	1	49)TOYOTA	COROLLA	82
342	342	23	1	1	35)NISSAN/DATSUN	PULSAR	87
342	342	23	.	2	12)FORD	F-SERIES PICKUP	83
343	343	43	1	1	12)FORD	LTD/CUSTOM/GALAXIE (ALL SIZES)	86
350	350	44	1	1	9)PLYMOUTH	VOLARE'	77
350	350	44	.	2	21)OLDSMOBILE	TORONADO	82
356	356	37	1	1	37)HONDA	CIVIC/CRX	83
356	356	37	.	2	20)CHEVROLET	C-SERIES PICKUP	72
361	361	15	1	1	14)MERCURY	MARQUIS/MONTEREY	79
365	365	5	1	1	20)CHEVROLET	CAMARO	87
366	366	12	1	1	7)DODGE	OMNI/CHARGER(83 ON)	85
366	366	12	.	2	22)PONTIAC	FIREBIRD/TRANS AM	75
366	366	12	.	3	20)CHEVROLET	MONTE CARLO	86
366	366	12	.	4	14)MERCURY	CAPRI-DOMESTIC	79
368	368	6	1	1	13)LINCOLN	VERSAILLES	79
368	368	6	.	2	18)BUICK	RIVIERA	84
368	368	6	.	3	41)MAZDA	626	81
394	394	41	1	1	20)CHEVROLET	ASTRO VAN	85
400	400	19	1	1	30)VOLKSWAGEN	JETTA	86
400	400	19	.	2	20)CHEVROLET	BUS	69
414	414	1	1	1	7)DODGE	DAYTONA	88
420	420	28	1	1	12)FORD	ESCORT/EXP	89
427	427	18	1	1	20)CHEVROLET	CHEVELLE/MALIBU	67
473	473	39	1	1	22)PONTIAC	BONNEVILLE/CATALINA/PARISIENNE	88
484	484	4	1	1	9)PLYMOUTH	SAPPARO	82
484	484	4	.	2	22)PONTIAC	FIREBIRD/TRANS AM	82
484	484	4	.	3	53)SUZUKI	SAMURAI	87
486	486	35	1	1	35)NISSAN/DATSUN	310	79
486	486	35	.	2	20)CHEVROLET	OTHER MED/HEAVY TRUCK	82
486	486	35	.	3	20)CHEVROLET	CAVALIER	84
508	508	80	1	1	12)FORD	MUSTANG/MUSTANG II	86
508	508	80	.	2	85)TB/KENWORTH	UNK	89
510	510	91	1	1	19)CADILLAC	ALLANTE'	88
513	513	97	1	1	42)MER. BENZ	300 SE/380/450 SE	87
513	513	97	.	2	85)TB/KENWORTH	TRK/BUS MED/HEAVY-CBE	80
524	524	51	1	1	49)TOYOTA	4-RUNNER	85
525	525	54	1	1	14)MERCURY	TOPAZ	87
543	543	87	1	1	7)DODGE	POLARA/MONACO ROYAL MONACO	73
554	554	88	1	1	20)CHEVROLET	NOVA/GEO PRIZM	90

CRASH NUM**	NHTSANO	SEQ NUM	CASE*	VEH NUM	MAKE	MODLE	MODEL YEAR
555	555	62	1	1	37)HONDA	PRELUDE	89
555	555	62	.	2	49)TOYOTA	PICKUP	89
559	559	72	1	1	14)MERCURY	MARQUIS/MONTEREY	89
570	570	84	1	1	20)CHEVROLET	CHEVETTE	82
570	570	84	.	2	20)CHEVROLET	CAMARO	85
579	579	85	1	1	12)FORD	THUNDERBIRD (ALL SIZES)	86
585	585	94	1	1	7)DODGE	COLT (EXCLUDES VISTA)	85
585	585	94	.	2	12)FORD	F-SERIES PICKUP	86
586	586	59	1	1	20)CHEVROLET	NOVA/GEO PRIZ	87
586	586	59	.	2	2)JEEP	CHEROKEE	87
587	587	60	1	1	48)SUBARU	DL/FE/G/GF/GL/GLF/STD	86
587	587	60	.	2	22)PONTIAC	J2000/2000/SUNBIRD	83
590	590	68	1	1	48)SUBARU	DL/FE/G/GF/GL/GLF/STD	83
590	590	68	.	2	7)DODGE	DAKOTA	87
590	590	68	.	3	14)MERCURY	MARQUIS/MONTEREY	85
592	592	56	1	1	35)NISSAN/DATSUN	STANZA	89
592	592	56	.	2	1)AMERICAN MOTORS	EAGLE	82
592	592	56	.	3	19)CADILLAC	DEVILLE/FLEETWOOD	85
595	595	58	1	1	20)CHEVROLET	CHEVETTE	76
595	595	58	.	2	12)FORD	F-SERIES PICKUP	88
601	601	57	1	1	12)FORD	MUSTANG/MUSTANG II	86
601	601	57	.	2	20)CHEVROLET	C-SERIES PICKUP	79
609	609	76	1	1	12)FORD	F-SERIES PICKUP	89
609	609	76	.	2	86)TB/MACK	TRK/BUS MED/HEAVY-CBE	85
619	619	65	1	1	12)FORD	TEMPO	87
619	619	65	.	2	21)OLDSMOBILE	CUTLASS(RWD-ONLY)	80
642	642	73	1	1	20)CHEVROLET	CAVALIER	82
642	642	73	.	2	23)GMC	MEDIUM/HEAVY CBE	90
650	650	98	1	1	14)MERCURY	COUGAR/XRT	87
666	666	64	1	1	20)CHEVROLET	BERETTA/CORSICA	89
667	667	63	1	1	37)HONDA	ACCORD	88
673	673	55	1	1	12)FORD	RANGER	83
673	673	55	.	2	12)FORD	LTD/CUSTOM/GALAXIE (ALL SIZES)	85
677	677	71	1	1	21)OLDSMOBILE	CUTLASS(RWD-ONLY)	70
680	680	61	1	1	12)FORD	E-SERIES VANS	89
685	685	83	1	1	41)MAZDA	RX7	80
702	702	121	1	1	7)DODGE	OMNI/CHARGER(83 ON)	86
710	710	138	1	1	37)HONDA	ACCORD	82
710	710	138	.	2	12)FORD	F-SERIES PICKUP	88
719	719	136	1	1	55)HYUNDAI	UNK	91
720	720	116	1	1	30)VOLKSWAGEN	SCIROCCO	85
734	734	110	1	1	49)TOYOTA	CELICA	79
734	734	110	.	2	12)FORD	TEMPO	90
748	748	120	1	1	20)CHEVROLET	CAMARO	89
751	751	123	1	1	12)FORD	RANGER	87
751	751	123	.	2	20)CHEVROLET	SUBURBAN	77
753	753	101	1	1	12)FORD	TAURUS	90

CRASH NUM**	NHTSANO	SEQ NUM	CASE*	VEH NUM	MAKE	MODLE	MODEL YEAR
759	759	139	1	1	12)FORD	TEMPO	89
767	767	119	1	1	20)CHEVROLET	CITATION	80
767	767	119	.	2	18)BUICK	SOMERSET/SKYLARK	86
773	773	118	1	1	2)JEEP	CHEROKEE	88
783	783	104	.	1	34)BMW	3-SERIES	86
783	783	104	.	2	54)ACURA	LEGEND	86
789	789	113	1	1	20)CHEVROLET	G-SERIES VAN	89
789	789	113	.	2	86)TB/MACK	TRK/BUS MED/HEAVY-OTHER	88
795	795	117	1	1	49)TOYOTA	SUPRA	79
802	802	131	1	1	21)OLDSMOBILE	CUTLASS (FWD)	90
802	802	131	.	2	86)TB/MACK	TRK/BUS MED/HEAVY-COE/HIGH ENTRY	89
802	802	131	.	3	12)FORD	MEDIUM/HEAVY CBE	89
808	808	111	1	1	49)TOYOTA	CELICA	79
808	808	111	.	2	12)FORD	TEMPO	90
809	809	133	1	1	20)CHEVROLET	ASTRO VAN	90
809	809	133	.	2	89)TB/OTHER	OTHER VEHICLE	77
820	820	132	1	1	18)BUICK	SKYHAWK	80
820	820	132	.	2	7)DODGE	D-SERIES VANS	84
822	822	145	1	1	49)TOYOTA	CELICA	90
822	822	145	.	2	35)NISSAN/DATSUN	1200/240/ SX	80
823	823	108	1	1	12)FORD	FAIRMONT	78
823	823	108	.	2	86)TB/MACK	UNK	69
842	842	134	1	1	20)CHEVROLET	SPECTRUM/GEO STORM	85
842	842	134	.	2	48)SUBARU	DL/FE/G/GF/GL/GLF/STD	81
861	861	137	1	1	55)HYUNDAI	SONATA	90
861	861	137	.	2	13)LINCOLN	CONTINENTAL/TOWN CAR	88
861	861	137	.	3	99)UNK	UNK	99
873	873	126	1	1	37)HONDA	CIVIC/CRX	83
873	873	126	.	2	53)SUZUKI	SAMURAI	88
878	878	130	1	1	35)NISSAN/DATSUN	Z-CAR, ZX	79
883	883	102	1	1	20)CHEVROLET	S-10 BLAZER	88
883	883	102	.	2	21)OLDSMOBILE	DELTA 88	85
884	884	141	1	1	7)DODGE	DART	71
885	885	129	1	1	18)BUICK	SOMERSET/SKYLARK	86
887	887	122	1	1	7)DODGE	DART	74
887	887	122	.	2	7)DODGE	DAKOTA	91
906	906	109	1	1	20)CHEVROLET	NOVA/GEO PRIZ	86
909	909	135	1	1	22)PONTIAC	J2000/2000/SUNBIRD	90
909	909	135	.	2	12)FORD	E-SERIES VANS	88
910	910	112	1	1	30)VOLKSWAGEN	SCIROCCO	81
924	924	142	1	1	20)CHEVROLET	CELEBRITY	86
924	924	142	.	2	12)FORD	PROBE	90
924	924	142	.	3	89)TB/OTHER	OTHER BUS	81
928	928	105	1	1	21)OLDSMOBILE	CALAIS	86
928	928	105	.	2	21)OLDSMOBILE	NINETY-EIGHT	86
952	952	103	1	1	20)CHEVROLET	CELEBRITY	85
952	952	103	.	2	20)CHEVROLET	C-SERIES PICKUP	81

CRASH NUM**	NHTSANO	SEQ NUM	CASE*	VEH NUM	MAKE	MODLE	MODEL YEAR
957	957	125	.	1	12)FORD	MUSTANG/MUSTANG II	81
969	969	144	1	1	20)CHEVROLET	CHEVETTE	80
969	969	144	.	2	30)VOLKSWAGEN	FOX	90
969	969	144	.	3	20)CHEVROLET	SPECTRUM/GEO STORM	88
974	974	124	1	1	20)CHEVROLET	MONTE CARLO	87
975	975	140	1	1	20)CHEVROLET	CAMARO	88
980	980	106	1	1	35)NISSAN/DATSUN	STANZA	90
982	982	143	1	1	2)JEEP	CHEROKEE	90
982	982	143	.	2	49)TOYOTA	TERCEL	84
988	988	107	1	1	20)CHEVROLET	SPECTRUM/GEOSTORM	85
988	988	107	.	2	6)CHRYSLER	LEBARON	84
988	988	107	.	3	32)AUDI	5000	84
54064	54	31	1	1	12)FORD	LTD/CUSTOM/GALAXIE (ALL SIZES)	85
54064	64	30	1	1	21)OLDSMOBILE	DELTA 88	80
122162	122	48	1	1	13)LINCOLN	CONTINENTAL/TOWN CAR	86
122162	162	47	1	1	20)CHEVROLET	C-SERIES PICKUP	88
122162	122	48	.	2	35)NISSAN/DATSUN	DATSUN/NISSAN PICKUP	87
169418	169	8	1	1	20)CHEVROLET	CELEBRITY	87
169418	418	7	1	1	20)CHEVROLET	CELEBRITY	87
466091	91	24	1	1	12)FORD	ESCORT/EXP	86
466091	466	25	1	1	12)FORD	ESCORT/EXP	86
466091	91	24	.	2	84)TB/HARVESTER-NA	MED/HEAVY-CBE	75
502503	502	75	1	1	37)HONDA	ACCORD	89
502503	503	74	1	1	37)HONDA	ACCORD	89
515602	515	70	1	1	20)CHEVROLET	IMPALA/CAPRICE	85
515602	602	69	1	1	37)HONDA	ACCORD	84
515602	515	70	.	3	12)FORD	F-SERIES PICKUP	89
515602	602	69	.	4	13)LINCOLN	CONTINENTAL/TOWN CAR	87
536627	536	95	1	1	12)FORD	ESCORT/EXP	82
536627	627	96	.	2	9)PLYMOUTH	VOYAGER (MINIVAN)	85
542675	542	90	1	1	37)HONDA	PRELUDE	89
542675	675	89	1	1	37)HONDA	PRELUDE	89
548643	548	53	1	1	21)OLDSMOBILE	DELTA 88	78
548643	643	52	1	1	12)FORD	LTD/CUSTOM/GALAXIE (ALL SIZES)	80
560598	560	92	1	1	12)FORD	LTD/CUSTOM/GALAXIE (ALL SIZES)	76
560598	598	93	1	1	49)TOYOTA	CAMRY	87
560598	560	92	.	3	54)ACURA	INTEGRA	88
560598	598	93	.	4	20)CHEVROLET	CELEBRITY	86
566583	566	79	1	1	12)FORD	CROWN VICTORIA	90
566583	583	78	1	1	19)CADILLAC	DEVILLE/FLEETWOOD	87
566583	566	79	.	3	99)UNK	UNK	99
593698	593	100	1	1	7)DODGE	COLT (EXCLUDES VISTA)	87
593698	698	99	.	2	20)CHEVROLET	CELEBRITY	84
599620	599	86	1	1	37)HONDA	ACCORD	81
599620	620	77	1	1	49)TOYOTA	COROLLA	84
599620	599	86	.	3	20)CHEVROLET	S-10	86
599620	620	77	.	4	12)FORD	LTD/CUSTOM/GALAXIE (ALL SIZES)	86

CRASH NUM**	NHTSANO	SEQ NUM	CASE*	VEH NUM	MAKE	MODEL	MODEL YEAR
599620	620	77	.	5	20)CHEVROLET	ASTRO VAN	88
613639	613	67	1	1	12)FORD	RANGER	88
613639	639	66	1	1	12)FORD	RANGER	88
615616	615	82	1	1	7)DODGE	OMNI/CHARGER(83 ON)	90
615616	616	81	.	2	12)FORD	TAURUS	89
821886	821	115	1	1	49)TOYOTA	TERCEL	87
821886	886	114	.	2	20)CHEVROLET	OTHER MED/HEAVY TRUCK	86
919956	919	128	1	1	12)FORD	THUNDERBIRD (ALL SIZES)	78
919956	956	127	1	1	12)FORD	THUNDERBIRD (ALL SIZES)	78

* 1 - Study case
. - Not a study case but vehicle involved in preceding case crash

** If Crash Number and NHTSANO are the same, only one person from that crash was included in the study. If Crash Number coincides with multiple NHTSANO's, then multiple persons from the same crash were included in the study.

SUMMARY, CASE 414 (001)

This was a single vehicle accident which occurred on a cloudy weekday afternoon and involved a 1988 Dodge Daytona Pacifica 3-door coupe with 3 occupants. The vehicle was westbound on a 2 lane asphalt highway, went out of control, rotated clockwise into a broadside skid, ran off the road into a corn field, and impacted a 9 inch utility pole at the left A pillar. The pole shattered on impact and the vehicle vaulted to the left rolling 8 quarter turns about the longitudinal axis. The driver was ejected and killed, the right front passenger was not ejected and was transported to a hospital with incapacitating injuries, and the left rear occupant was ejected and suffered lacerations to the forehead along with fractures to the right femur, fibula, and tibia.

BODY CONTACTS AND INJURIES TABLE-CASE 414
17 year old male, left rear occupant, ejected

OIC/AIS CODE	ICD-9	CONTACTS OR INJURIES	CONTACT POINT
2HULI1 251100	873.0	Scalp Laceration	Glass/WFrame
2FSLI1 251100	873.42	Mult. Forehead Laceration Partial Thickness < 5cm	Glass/WFrame
2HWKB2 251100	854.06	Closed Head Injury with Positive loss of consc.	Glass/WFrame
2CRAI1 841100	911.0	Right Chest Abrasion	Ground
2MUAI1 842100	911.0	Abdomen Abrasion	Ground?
2TRFS3 403206	820.31	Right Femur Fracture -Intertrochanteric	Seatback??
2LRFS3 403106	823.82	Right Distal Tibia Fracture	Seatback??
2LRFS2 403106	823.82	Right Distal Fibula Fracture	Seatback??
Unknown if Injured		Head Contact-mud,hair,blood	Left Side Panel
Unknown if Injured		Abraded Fabric, Blood	Interior Roof

PSYCHOSOCIAL TIMELINE-CASE 414

Initial Interview

This is a 17-year-old male who is 6 weeks post-trauma following a motor vehicle accident. Patient was a passenger in a car driven by a 24-year-old unemployed friend who received SSI due to past history of substance abuse. The driver of car was killed. The third occupant of the car had been recently suspended from school, and both he and the driver had been drinking beer prior to the accident. Patient was picked up by friends after school and was enroute to patient's part-time job through the Job Corps Program, where the patient did custodial work at minimum wage. Patient is currently a senior in high school, expecting to graduate in June, and is reported to be an average to above-average student. Patient is the oldest of 5

children living at home with his mother, who is a single parent. Family income is approximately $25,000 annually. Patient is covered through commercial health insurance. He has not returned to work or school. Patient is described as a popular young man with a large support system, friendly and outgoing.

T + 3 Month Follow-Up Interview

The patient was unable to return to school until T + 78 days due to ambulation restrictions. In spite of homebound schooling, the patient was not able to keep up with school studies and was both depressed and upset about the possibility of not graduating with his class. Although the patient is more cautious and aware of safety, he has not yet returned to driving. To the family, the patient has exhibited episodes of anger, depression and irritability within normal bounds of coping and continues to receive support from his peers.

T + 6 Month Follow-Up Interview

The patient was not permitted to graduate with his senior high school class. He has since exhibited hostile acting-out behavior, increased drinking, and is generally depressed, refusing to talk about his feelings and given to frequent angry outbursts. The patient does not want to go to summer school and a family conflict has arisen regarding the patient's attitude and his lack of goals. A referral to vocational rehabiliation has been recommended.

CRASH TIME LINE, CASE 414:

T - 5 seconds: The vehicle involved in this collision, a 1988 Dodge Daytona Pacifica 3-door, was westbound in a right hand curve at an estimated speed of 80 to 85 miles per hour (mph). The roadway is a 2 lane highway in northeastern Maryland and is bordered on both sides by corn fields which are now cleared. Each lane is approximately 11 feet wide with a solid white line marking the outer edge and an approximate 4 foot wide shoulder to the outside of the white line. The road is of asphalt construction and has a total width of approximately 30 feet. The portion of road where this collision occurred is straight and has a negative 3% vertical slope. The lanes are divided by double yellow lines. The speed limit is 35 mph. The collision occurred on an overcast weekday afternoon with dry pavement and high visibility. As the vehicle exited the right hand curve, the driver, a 24 year old male, lost control as the vehicle began a clockwise rotation. The driver was not utilizing the lap/torso restraint and the vehicle was not fitted with passive airbag components. There was a 14 year old male in the right front seat and a 17 year old male in the left rear seat. Neither of these occupants were using the available active restraints.

T - 1.9 seconds: At this point, the vehicle had rotated enough to begin transferring lateral skid marks to the pavement.

The estimated coefficient of friction was .65. Forces acting on the 3 occupants would have been pulling their bodies to the left side of the vehicle interior. This force would grow stronger as the vehicle's clockwise rotation increased into a full broadside slide. After an approximate 120 feet of lateral skidding on the highway, and 114.5 additional feet in the corn field to the north of the highway, the vehicle was facing north and traveling west at a speed of approximately 60 to 65 mph. The driver could have had no control over the vehicle trajectory and all three occupants were being forced into the left side of the vehicle interior.

T - 0: The vehicle impacted a 9 inch diameter wooden utility pole at the left A pillar. The utility pole shattered during impact, producing a sharp and narrow direct contact pattern. At maximum engagement the left A pillar was intruded 21.6 inches laterally, the left side floor pan was intruded 20.4 inches laterally, the left door panel had 11.6 inches of lateral intrusion and due to latch/door structure failure was forced open. The left roof siderail was intruded 11.3 inches laterally. These intrusions all occurred at the driver's seat position. The driver's seat back intruded longitudinally 6 inches into the left rear occupant's position. This jammed the driver seat into the rear seat. Maximum crush at sill level was 22.5 inches.

T +.05 to 1.0 second: Since estimated speed change at impact was approximately 28.3 mph, the occupants were forced toward the left interior surface of the vehicle at considerable speeds. The driver's head was forced into the left roof side rail. Hair was deposited on the side rail fabric and the fabric itself showed signs of abrasion. The driver also left tissue deposits on the left door window frame. These skin fragments were arranged in a sweeping type pattern across the top of the window frame. Since the driver's door was already open, this pattern suggests that the driver was ejected at a time immediately following maximum engagement of the vehicle and the pole. The left rear passenger's head was forced into the small triangular fixed glass to his left. A deposit of hair was found in the jagged edges of this window frame and blood deposits around the frame and down the left rear interior panel indicate that this occupant remained inside the vehicle initially after contacting the glass. Since the utility pole shattered at impact, and maximum crush was located close to the actual vehicle center of gravity, rotational forces as a result of the impact were not noted. Instead, the vehicle vaulted to the left and proceeded to roll about the longitudinal axis. The rear hatch came open, the right A pillar had lateral intrusion of 6.4 inches and vertical intrusion of 4.9 inches. There was 4.9 inches of vertical intrusion to the right roof side rail also. There was a mixture of blood, hair, and mud on the interior rear left side which suggests that the head of the left rear occupant contacted the ground as his head went through the small triangular side glass. This mixture deposited on the left side interior by the occupant as the vehicle rolled. As this occupant exited the vehicle through the

rear hatch, he contacted the roof and left a blood deposit on the fabric. The rear seat lap belt was not utilized. No contact points were found from the occupant seated in the right front position although no evidence of lap/torso restraint usage was found either. He was not reported as being ejected.

T + 2.8 seconds: The vehicle came to rest facing north after it had completed a rollover of 8 quarter turns at an approximate distance of 120 feet from impact with the pole. Final rest position was 354.6 feet west and 78.9 feet north of the first skid marks documented.

T + 10 minutes: The Maryland State Police were notified that the accident had occurred.

T + 18 minutes: The Maryland State Police arrived at the scene.

PREHOSPITAL AND HOSPITAL TIMELINE-CASE 414

T+2min: Ambulance receives call to respond.

T+6min: Ambulance arrives at scene. Assessment reveals a pulse of 110, a blood pressure of 140/110, a respiratory rate of 22, and a Glasgow Coma Score of 15. Care provided includes the insertion of an IV, provision of oxygen and spinal immobilization by cervical collar and backboard.

T+38min: Patient leaves the crash scene by helicopter enroute to MIEMSS/Shock Trauma.

T+70min: Patient arrives at the MIEMSS admitting area. Initial physiologic assessment reveals a blood pressure of 160/94, a heart rate of 91, a respiratory rate of 20, and a Glasgow Coma Score of 15. The patient's ISS = 19. The toxicologic screen reveals negative results. The following clinical care is provided:

-Evaluation by a MIEMSS trauma team,
-Fluid resuscitation,
-Full diagnostic evaluation including x-rays of the cervical spine, chest and pelvis. In addition to the toxicology screen, an arterial blood gas, a CBC (complete blood count), an SMA-6 (regular blood chemistry), and a UA (urinalysis).

Injuries noted include:

-Anterior scalp contusion
-Right forehead contusion and laceration
-Right anterior upper chest contusion
-Midline abdominal wall contusion
-Right femur fracture (comminuted, intertrochanteric)
-Closed right tibia and fibula fractures in the distal third of the lower leg.

Operative procedures include:

-Open reduction with internal fixation of the right femur and intramedullary rodding of the right tibia.

No complications reported during the acute care phase for this

patient.
T+24hours - 7days: Patient spends 4 days in intensive care and 3 days in intermediate care.
T+7days: Patient discharged to home ambulating only with crutches.

BIODYNAMICS ANALYSIS FOR THE AUTOMOBILE CRASH TRAUMA STUDY

CRASH COMPARASON
Case #414

Introduction:

An original search on this case on the Crash Test Vehicle Data Base did not turn up very much. There were two contributing factors to this: the newness of the vehicle (1988) and the uniqueness of the accident conditions. The only Dodge Daytona in the data base was a head-on crash at 30 MPH.

After discussions with the simulation part of the team, a set of query parameters were set up using vehicle weight, point of impact, speed, and a range of angles for the impact (e.g. 240-310 degrees). Test data base searches were then searched on these.

The very violence and multistage incidence of this accident makes it difficult to acquire data for since the crash test program does not conduct tests at these extremes. It is further not anticipated that the search of the NASS and FARS data bases will yield much since it is not probable that this kind of event occurs very often or that it occurs in sufficient numbers to yield exactly the same results. Head-on or side collisions at 25-40 MPH would be far more productive of analytic data.

Search Characteristics and Data Yield:

In order to obtain data from the vehicle data base we needed to expand several search criteria. The weight of the vehicle was roughly 2800 lbs. so we expanded the search to include vehicles between 2000 and 3500 lbs. The impact angle of 270 degrees was expanded to include all impacts between 225 and 315 degrees. The results of this query provided 13 cases for consideration. They are shown below in Table 414-1.

Table 414-1 Results of Initial Query

UEST#	VEHICLE MAKE/MODEL	WEIGHT	IMP.SPEED	IMP.ANGL.	BARRIER
442	1976 VOLKS. RABBIT	2013 LBS.	30.4 mph	270 deg.	Lumin
749	1981 VOLKS. RABBIT	2590 LBS.	20.1 mph	315 deg.	Pole
755	1981 VOLKS. RABBIT	2580 LBS.	19.9 mph	315 deg.	Pole
762	1981 VOLKS. RABBIT	2600 LBS.	25.0 mph	315 deg.	Pole
768	1977 VOLKS. RABBIT	2615 LBS.	25.0 mph	315 deg.	Pole
1105	1980 PLYM. CHAMP	2010 LBS.	29.4 mph	270 deg.	Lumin
1106	1980 DODGE COLT	2010 LBS.	28.6 mph	270 deg.	Lumin
1107	1981 DODGE COLT	2010 LBS.	30.5 mph	270 deg.	Lumin
1108	1980 PLYM. CHAMP	2010 LBS.	29.7 mph	270 deg.	Lumin
1109	1981 PLYM. CHAMP	2010 LBS.	29.5 mph	270 deg.	Lumin
1224	1980 PLYM. CHAMP	2010 LBS.	29.3 mph	270 deg.	Lumin
1225	1980 DODGE COLT	2010 LBS.	28.9 mph	270 deg.	Lumin
1226	1981 PLYM. CHAMP	2010 LBS.	29.6 mph	270 deg.	Lumin

Closer examination of these cases shows that some involve breakaway devices and thus are not comparable to this case. Case number 1224 did not involve a breakaway device and so seemed to be best suited. Analysis of the instrumentation data in Figures 414-1 and 2 displayed a delta V of about 28mph though at alower speed (half that of the actual case) and a deceleration of about 34-36 Gs at the 50 millisecond point. A check of the crush pattern also turned up similarities. As a result of the comparisons, the simulation team decided to use Case number 1224.

Comparison of curves:

The instrumentation in case 1224 failed in most cases. There were, however, two curves produced which give some data as the pulse. One of them, a left lower rib accelerometer, is shown in Figure 414-1 below. On the y-axis, it shows a rather severe change in velocity for this side impact crash test. This corrresponds to the probable motions that resulted in inter-occupant contact and some of the injuries in the actual vehicle. As a further indicator of pulse, the curve for the vehicle COG for case 1225 was looked at and here again a rather severe change in velocity is seen. The test case, with its delta V of 28mph, was estimated by the simulation engineer to have a maximum deceleration of 35 gs at 50 msec, about the same as the actual case. This, together with a similar crush pattern, led to use of this case in estimating the simulation model parameters.

Crash Test Occupant Injuries:

In test case 1224, the only occupant was an unrestrained driver dummy, again a similarity to this case. The dummy incurred injuries of HIC 2191 and CSI 190 in this crash test. The head

injury was obviously the most severe and was caused by contact with the vehicle side door frame. The chest injury was caused by the generic category of "Other". It is interesting to note that the HIC in the test case was much more severe than that shown by the simulation model (HIC 590) while the CSI was greater by a relatively lesser amount (430 to 190). Further, the head injury in both the test case and the simulation seemed more severe than the actual case. This points to the fact that lack of a belt restraint and the ejection out the back window may have led to an avoidance of more serious head and chest injury. The driver dummy had no where to go but up against the door frame.

Significance of the Crash:

The fact that the occupant was unrestrained is not particularly unusual. About 39% of all occupants involved in accidents do not wear restraints. Of these, approximately 29% will sustain AIS 1 or greater injury and about 1% AIS 3. This tracks with the case occupant. 57% of rear seat occupants are unrestrained. He had a pretty good chance of being injured. What is surprising is that he wasn't more seriously injured. In 45% of the cases of an ejection the injury severity will be AIS 3 or more. Also, 62% of all cases of ejection are fatalities. This man was lucky.

In general. this is a pretty typical case. Passenger cars account for 65% of all fatal accidents and the majority (70%) of these accidents occur in rural areas at speeds in excess of 55MPH. Level curving roadways are the second most frequent location for fatal accidents. Only straight and level are higher in incidence. An incidence of collision with a fixed object (in this case a utility pole) as the first harmful event occurs 29% of the time in fatal accidents.

The fact that this person was unbelted combined with the fact that the car was a hatchback may have saved him worse injury. Since the motion forced him back and up after the initial impact with the pole, he went right out the rear window and probably escaped more severe injuries from bouncing around the interior during the rollover portion of the accident. Ejection should have given him greater injuries but did not. This could be due to his probably being ejected early and at a low point with respect to the ground.

PSYCHOSOCIAL FOLLOW-UP - CASE 414

6 Months

Seventeen (17)-year-old white male, senior in high school at time of injuries, returned to school 78 days post-trauma with minimal restrictions. In spite of homebound schooling, patient

was not able to keep up with school studies and was depressed and upset about possibility of not graduating with class. Although patient is more cautious and aware of safety, he has not yet returned to driving. Patient has exhibited episodes of anger, depression and irritability with increased drinking behavior. Referral to vocational rehabilitation recommended.

1 Year

Patient is mildly disabled, in that injury prevented completion of high school education and occurred at an important developmental stage, greatly impacting his career options. At one (1) year post-trauma, this 18-year-old single male is currently working as a carpenter's assistant. He had hoped to obtain construction work but still having difficulties due to orthopedic problems.

Patient did not complete high school after he learned he was short credits to graduate, refusing to go to summer school. He continues to be more withdrawn socially, not seeing friends as frequently nor dating. Although family notes some problems with memory, patient feels it is primarily short-term memory. Angry outbursts and irritability persist. Patient did not follow through with vocational rehabilitation.

CRASH AND INJURY PREVENTION IDEAS - CASE 414

This accident has several human factors which possibly could have been modified by continuing education. The driver was a 24-year-old male apparently trying to impress his 14 and 17-year-old male passengers with his car and his ability to drive it. Restricting vehicle speeds and electronic gravity sensing devices coupled with deceleration devices to automatically deploy when unusual side forces exist may have slowed this vehicle's broadside slide which covered 234.5 feet and resulted in a collision with a utility pole and rollover to final rest. The installation of door hardware air cushion restraint systems and automatic seat belts probably would have contained everyone within the passenger compartment and the injuries associated with ejection may have been reduced or eliminated.

PREVENTION COMMENTS - CASE 414

This accident occurred to a driver with a history of substance abuse, who was thought to be drinking at the time. There was an excessive rate of speed on a narrow road which had a rise prior to the area of the loss of control. As far as we can determine, the car may have lifted off the road with the driver losing control and rotating laterally into a pole. The driver was killed, the front seat passenger was transported to a community hospital, and the left rear occupant (case occupant)

sustained injuries to his scalp and forehead, a closed right tibia-fibula fracture about 20cm above the floor (distal 1/3), and a comminuted right intertrochanteric femur fracture.

In terms of prevention-we need stricter alcohol laws which mandate license revocation and alcohol control programs are needed since this driver had a previous alcohol conviction; also improved educational programs and stricter enforcement of the laws are necessary. Secondly, the rate of speed was excessive and the road did not appear to be marked with regards to the curve. Another useful preventative measure is that the area be marked by a sign that states the number of fatalities that have occurred; i.e., "this curve has killed four drivers". This is done in some countries in Europe.

With regards to our patient (Case 414), the intrusion of the front seat caught the rear passenger's leg resulting in a fracture. There is very poor protection against backward intrusion of the front seat in severe accidents. Efforts at design which would prevent the seat from moving beyond the assigned position would certainly be useful, since that was the mechanism of the major injury. Seatbelts in the rear seat, especially with a three point restriction would probably have prevented the upper chest contusion and possibly also would have prevented the patient from leaving the car thereby sustaining his forehead contusion and laceration. Finally, the car is a hatchback which means that the back roof and structures are close to the position in which the patient was sitting, and this has to be taken into account when designing features for protection. It also appeared that the hatchback sprung open so that a better locking mechanism plus the addition of safety glass in the hatch might go a long way in preventing injury. The standards for safety glass in the hatchbacks should be the same as the standards for the front since they are a common place of ejection and laceration. We might also add additional bolstering behind the front seats as this would give extra cushioning. Also, if there was a ratchet mechanism for the front seat instead of it being on a glide, one might have a mechanical block to the posterior motion. Finally, if the car had had a breathalyzer ignition system, the driver who was killed would not have been able to drive at all.

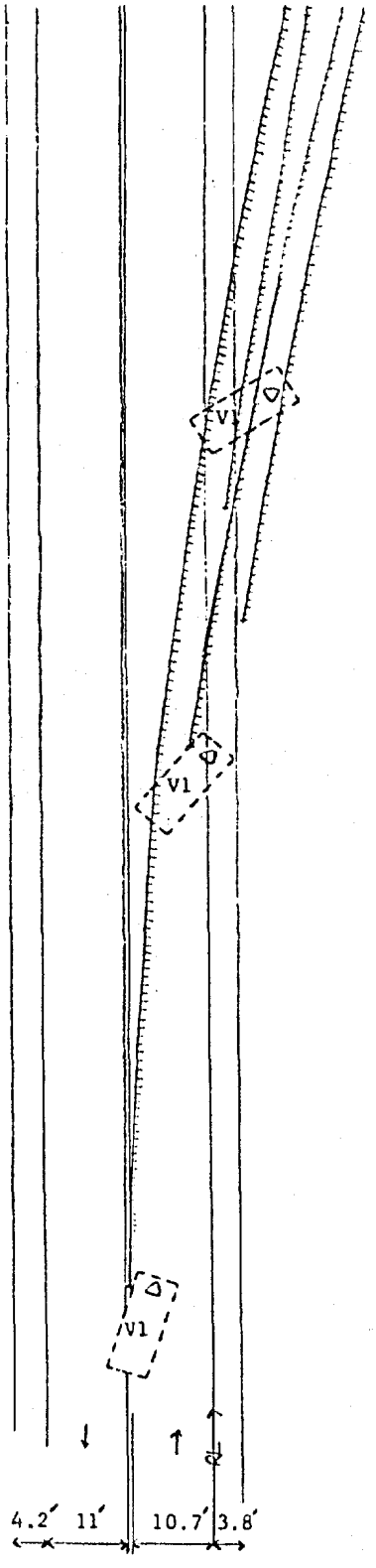

Corn Field

SCALE
1" = 24'0"

DYNAMIC SCIENCE
Case 414

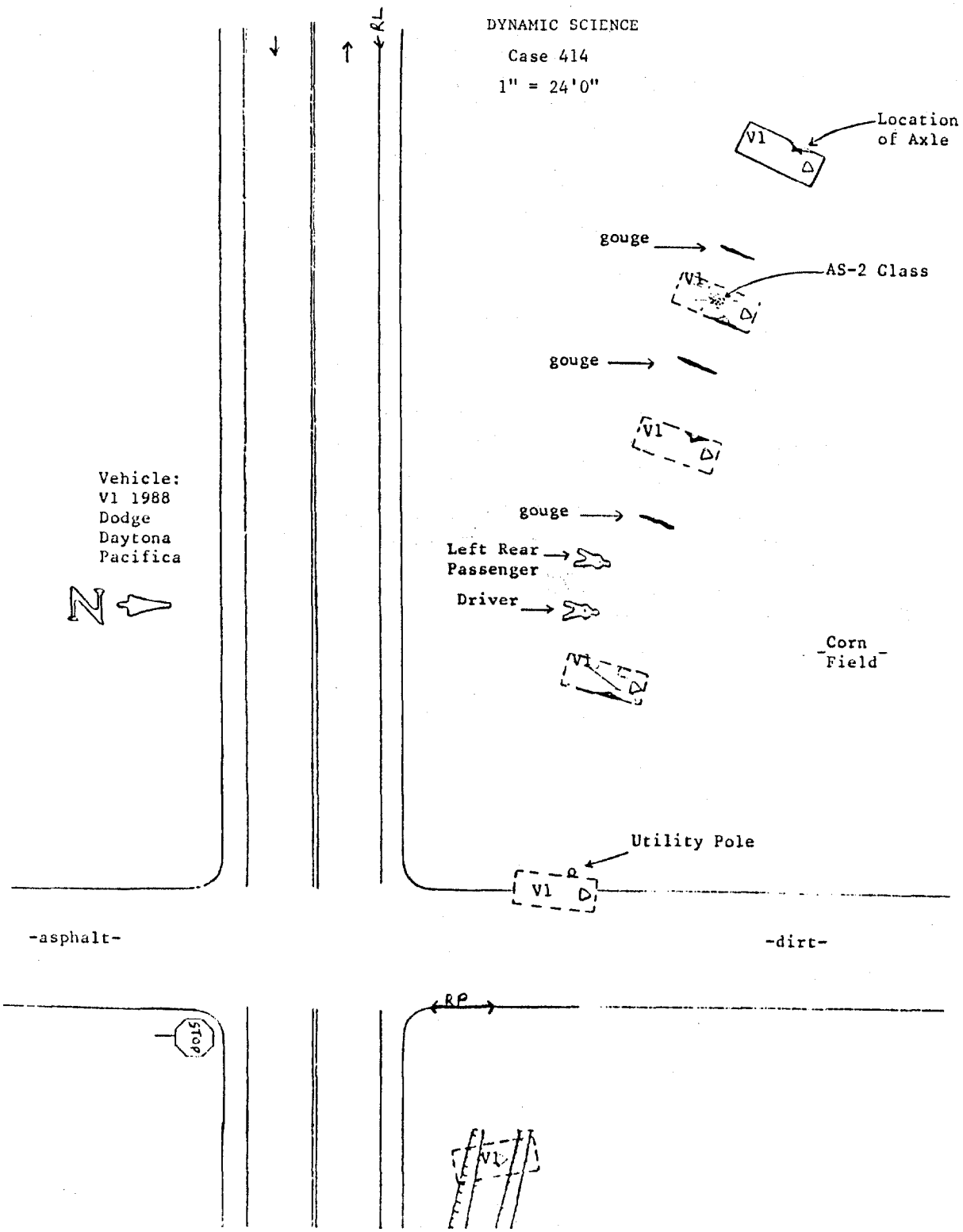
DYNAMIC SCIENCE
Case 414
1" = 24'0"
RL
Location of Axle
V1
gouge
AS-2 Class
gouge
gouge
Vehicle:
V1 1988
Dodge
Daytona
Pacifica
N
Left Rear Passenger
Driver
Corn Field
Utility Pole
-asphalt-
-dirt-
RP
STOP

SELECTED PHOTOGRAPHS, CASE 414

414-07

1.

Scene. V1 direction of travel. Impacted utility pole to right of roadway. Note: skid marks.

414-29

2.



V1; 1988 Dodge Daytona Pacifica 2 door hatchback. Vehicle to fixed object impact. Intrusion = 21.6" at left "A" pillar. Max crush = 22.5" at sill level.

SELECTED PHOTOGRAPHS, CASE 414

3.



Case occupant seated in left rear position sustained facial lacerations, right tibia fracture (AIS-3) with probable contact the seat back and other injuries. Some contact points are undetermined due to vehicular rollover.

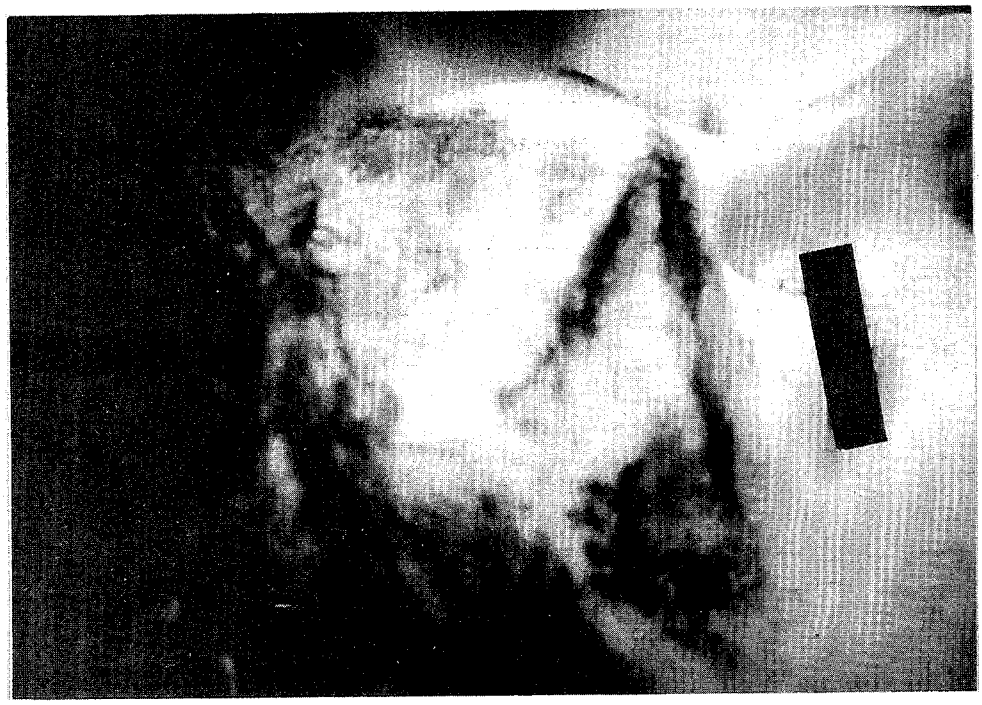

414A Laceration to the anterior scalp and left forehead.

Contact Point- Left rear window frame and glass
Type of Crash- Rollover with occupant ejection
Estimated Force of Impact with top sidepanel- 470 lbs.

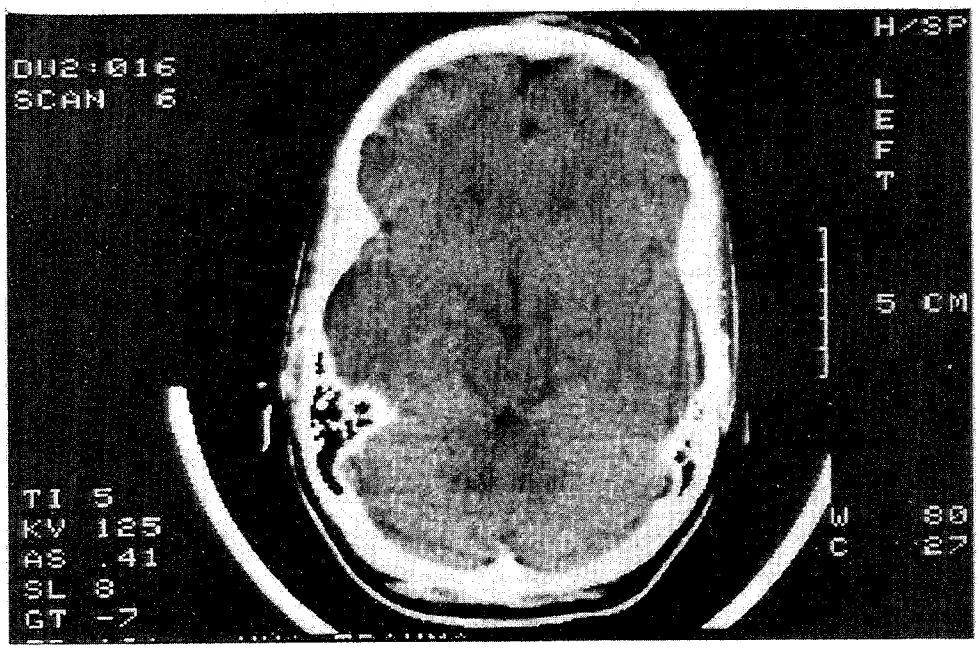

414B Head CT Scan revealing a scalp hematoma in the left frontal region.

Contact Point- Left rear window frame and glass
Type of Crash- Rollover with occupant ejection
Estimated Force of Impact with Top Sidepanel- 470 lbs.

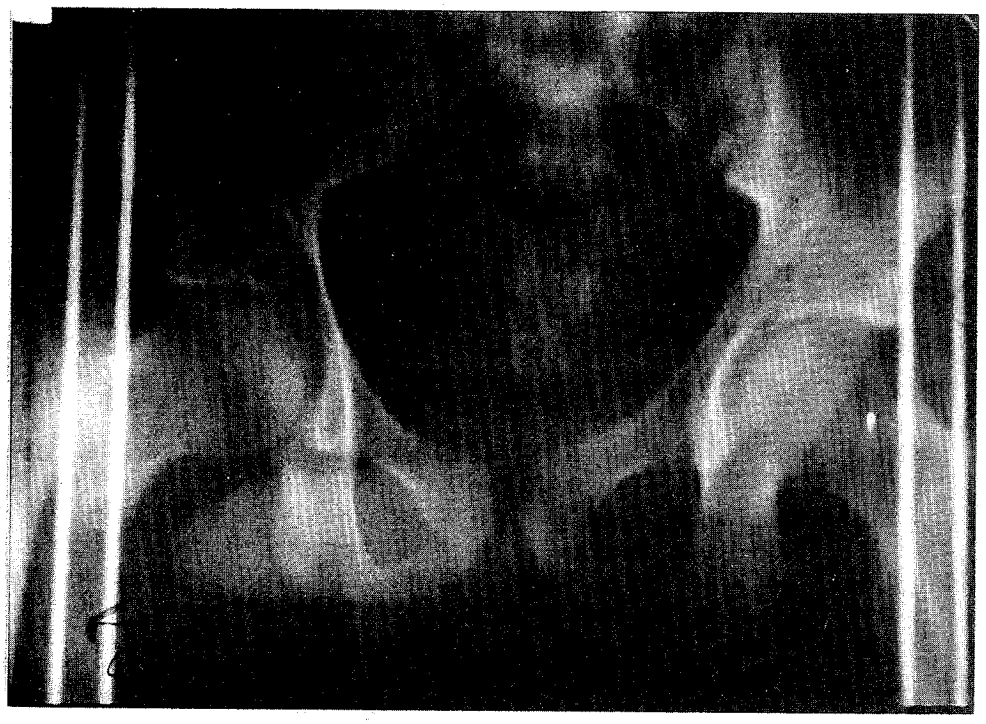

414C Pelvic X-Ray revealing an intertrochanteric fracture of the right femur. The fracture pattern is indicative of an axial load applied to the femur.

Contact Point- Seatback?
Type of Crash- Rollover with Occupant ejection



414D X-Ray revealing distal, transverse fractures of the right tibia and fibula. The fracture pattern is indicative of a direct non-axial, non-torsional load applied to the lower leg.

Contact Point- Seatback?
Type of Crash- Rollover with occupant ejection
Estimated Force of Impact- 560 lbs.

SUMMARY - CASE 088 (002)

This two vehicle accident occurred on a clear, winter, weekday afternoon. The accident involved a 1985 Dodge Omni 5-door with one 38-year-old female occupant, and a 1985 Ford Escort 5-door wagon with one 47-year-old female occupant. The Ford was westbound on a 4 lane highway just east of a bridge. The driver of the Ford was apparently suffering a diabetic seizure and the vehicle was reportedly swerving out of control. The Ford impacted a guardrail on the right side of the road, was deflected to the left, crossed the bridge, and struck the Dodge in the outside eastbound lane. The Dodge was then forced into the south bridgerail. The driver of the Dodge sustained injuries including a ruptured spleen, a left femoral neck fracture, and a lateral compression type fracture of the right superior pubic ramus. The Ford was deflected to the southwest and eventually struck the south bridgerail approximately 120 feet west of the impact with the Dodge. The driver of the Ford was transported to a hospital with incapacitating injuries.

BODY CONTACTS AND INJURIES TABLE-CASE 088
38 year old female, driver, left side impact

OIC/AIS CODE	ICD-9	CONTACTS OR INJURIES	Contact Point
2MLRQ2 201101	865.04	Ruptured Spleen	Left Door Panel
2PAFS2 201101	808.2	Pubic Ramus Fracture	Left Door Panel
2TLFS3 201101	820.09	Left Femur Fracture	Left Door Panel

PSYCHOSOCIAL TIMELINE - CASE 088

Initial Interview

Patient is a 38-year-old female who is 6 weeks post-trauma following a motor vehicle accident. She was a single driver occupant hit by a handicapped licensed vehicle whose driver went into diabetic shock. Patient was enroute to a business holiday luncheon at the time of the accident. Patient is a journalist/reporter having moved to Maryland 6-8 weeks prior to injury. Patient lives alone with no immediate family available. Patient does, however, have a supportive network of friends and business associates.

CRASH TIME LINE - CASE 088

T - 5 seconds: This accident involved two vehicles traveling on a 4 lane highway bridge in central Maryland. The bridge has 2 westbound and 2 eastbound lanes each approximately 12 feet in width. In the center of the bridge is a 4 foot wide overlap which

extends the length of the bridge. The bridge overlap has bevelled edges that allow easy access to opposing traffic lanes and it is bordered on each side by 13 foot wide lanes marked for emergency vehicle use only. The road edges are marked with solid white lines. There is a 3 foot wide paved shoulder and a 3.4 foot wide raised concrete walkway to the outside of each road edge and the bridge is bordered by concrete rails which run its entire length and terminate into abutments. The total width of the bridge is approximately 89.2 feet. The accident occurred on dry asphalt on a clear weekday afternoon. V1 is a 1985 Dodge Omni 5 door with one 38 year old female occupant. V2 is a 1985 Ford Escort 5-door wagon with one 47 year old female occupant. Neither driver was using the available lap/torso restraints. The driver of V2 was apparently suffering diabetic seizure as V2 was westbound and swerving out of control before impact. V2 began a clockwise rotation as it moved toward the north westbound shoulder at an estimated speed of 58 to 64 miles per hour.

T - .64 seconds: At this point, the vehicle had rotated enough to begin transferring lateral skid marks to the pavement. The estimated coefficient of friction was .65. Forces acting on the occupant would have been pulling her body to the left side of the vehicle interior. V2 skidded approximately 55 feet in a westerly direction and was facing approximately 10 degrees north of due west just prior to the first impact.

T - 0: By this time V1 which was eastbound had already begun to decelerate and move to the south eastbound shoulder. The right front bumper corner of V2 contacted a metal guardrail at the north shoulder edge. The vehicle then rotated counter-clockwise into the guardrail leaving direct contact damage along the entire right side of V2. Estimated Delta V at impact was 8.7 miles per hour. The driver of V2 would have been forced toward the right side of the vehicle interior at impact. The evidence suggests that she was still seated at the driver's position and laying to the right after this impact. Of the 5 occupant contact points documented for this person, at least 3 of them occurred during this impact. Deformation and clothing fabric transfers to the center console and the lower center instrument panel indicate a lower leg impact to these surfaces. There was a hard left to right motion of the right lower leg. It is reasonable to assume that this leg did not function normally prior to the accident as V2 was equipped with an aftermarket left side accelerator pedal. There was also a watch or ring gouge on the lower left steering wheel rim that was probably applied as the driver's left hand was forced from the wheel. V2 was deflected to the south after impact and crossed the bridge in a southwesterly direction with no driver input. V2 traveled approximately 161 feet in the next 2.4 seconds. At this point, V1 was stopped or nearly stopped at the extreme outside edge of the outside east bound lane and facing due east. V2 was facing approximately 35 to 40 degrees south of due west and approaching impact with the left side of V1. V2's estimated speed immediately prior to impact was 38 to 44 miles per hour.

T + 2.4 seconds: The left front bumper of V2 impacted V1 in the left side at the left front bumper corner. V2 then swept down the left side of V1 causing a shallow but long damage pattern to the entire left side of V1. The left front wheel of V2 snagged the left rear wheel of V1 causing V1 to be forced backward. Estimated speed change at impact was approximately 19 miles per hour. Upon impact with V2, the left floor pan of V1 was intruded laterally 2.8 inches and the door panel was intruded laterally 5.5 inches. Both of these intrusions occurred at the driver's position. The left rear door panel of V1 was also intruded laterally 4.3 inches. The Driver of V1 sustained injuries including a ruptured spleen, a left femoral neck fracture, and a lateral compression type fracture of the right superior pubic ramus. Three occupant contact points were documented for the driver of V1; A bent window control handle on the left front door panel, a deformed central left front door panel, and a deposit of makeup and hair was found on the upper left front door panel. After impact with V2, V1 continued backward for a short distance and mounted the raised walkway before impacting the concrete bridge rail. Upon impact with V1, the front left side/kick panel of V2 was intruded laterally 5.5 inches. This caused deformation to the aftermarket left side accelerator pedal linkage and rendered the accelerator pedal useless. The driver of V2 was forced to the front at impact and there was a contact point documented on the center middle instrument panel. There was also a clothing fabric transfer found on the center console mounted transmission selector. This transfer indicated a hard back to front motion. Both of these contact points are supportive evidence that the driver of V2 was already laying to the right upon impact with V1. During the next approximately 4.1 seconds after impact with V1, V2 continued in a southwesterly direction, was deflected to the west off of the raised concrete walkway, eventually mounted the walkway, and impacted the bridgerail with the left front bumper.

T + 6.5 seconds: V2 came to rest approximately 75 feet west of V1 at final rest and approximately 109 feet west of the estimated point of the maximum engagement between the two vehicles. The total length of documented evidence at the scene was 353.5 feet along the reference line.

T + 30 seconds to 60 seconds: The Maryland State Police were notified that the accident had occurred.

T + 5 minutes: The Maryland State Police arrived at the scene.

PREHOSPITAL AND HOSPITAL TIMELINE - CASE 088

T+3min: Ambulance receives call to respond.

T+9min: Ambulance arrives at scene. Victim is entrapped and requires heavy rescue/extrication. Assessment of patient # 088 reveals a heart rate of 140, a blood pressure of 120/60, a respiratory rate of 24, and a Glasgow Coma Score of 15. Care

provided includes administration of Oxygen.

T+54min: Patient leaves the crash scene by ground ambulance enroute to MIEMSS/Shock Trauma.

T+93min: Patient arrives at MIEMSS admitting area. Initial physiologic assessment reveals a heart rate of 110, a blood pressure of 138/77, a respiratory rate of 16, and a Glasgow Coma Score of 13. The patient's ISS = 22. The toxicologic screen reveals negative results. The following clinical care is provided:

-Evaluation by a MIEMSS trauma team,
-Fluid resuscitation,
-Full diagnostic evaluation including x-rays of the cervical spine, chest and pelvis. In addition to the toxicology screen, an arterial blood gas, a CBC (complete blood count), an SMA-6 (regular blood chemistry) and a UA (urinalysis) were performed.

Injuries noted include:

-Ruptured spleen
-Fractured pubic ramus
-Left femur fracture (subcapital)

Operative procedures include:

-Splenectomy
-Open reduction and internal fixation of femur fracture

No complications were reported on this patient during the acute care phase.

T+24hours - 13 days: The patient requires 6 days of intensive care and 7 days of intermediate care.

T+ 13 days: Patient discharged to home unable to ambulate.

COGNITIVE-COMMUNICATIVE ASSESSMENT NARRATIVE - CASE 088

The patient was evaluated on T + 5 days and presented with auditory and reading comprehension scores that were within normal limits. No deficits were noted in verbal expression skills. Subtle and resolving deficits were noted in voice production, orientation and thought organization skills. Hearing and swallowing skills appeared within normal limits. No treatment or follow-up intervention was indicated.

CRASH COMPARISON - CASE 088

A preliminary screening of the Crash Test data Base showed 5 cases for the Volkswagen Golf. One case is at 180 degrees, 2 at 30 degrees, and 2 at 0 degrees. The speeds are from 29.5 to 34.9 miles per hour. We will look more closely at the 30 degree impact tests for other characteristics to see if any useful data can be extracted.

Results and Considerations:

The initial information was again lean. However again, expanding the search criteria, it offered a wider range of possibilities. The vehicle is roughly 2200 lbs. and the impact angle 310 degrees. The search criteria was expanded to include vehicles between 1800 lbs. (if any exist) and up to 2600 lbs. The impact angle was expanded to include impacts of between 285 and 345 degrees. The initial results are as follows.
There were 8 cases retrieved. All of the cases were vehicles hitting either poles or guardrails at angles between 289 and 330 degrees, with vehicle weights between 2100 and 2600 lbs. at a wide range of speeds. It was then hoped that after broadening other variables as was shown above, that there would be more vehicle-to-vehicle impacts found. There were, as is shown in Table 088-1.

Table 088-1
DODGE OMNI

MAK	MOD	BOD	T#	YR	LBS.	LENGTH	WIDTH	COG	WBASE	SPEED	V	CRUSH
07	09	2C	701	81	2660	173.20	66.10	44.10	960.00	0.00	2	19.20
		3H	679	81	2680	173.90	66.10	44.10	96.80	0.00	2	15.90
		4S	806	84	2831	163.60	65.50	49.90	98.80	0.00	2	23.50
		5H	810	84	3016	163.60	66.50	47.20	99.00	0.00	1	14.80
			611	83	2602	164.50	65.80	39.40	99.10	31.20	2	27.10
			795	83	2745	162.00	66.30	41.00	99.20	29.90	2	23.80
			795	83	2750	163.70	66.50	38.60	99.00	30.10	1	20.80
			816	83	2942	163.80	66.10	43.30	98.90	0.00	1	25.30
			845	83	2828	163.70	65.60	44.80	99.00	0.00	1	34.00
			845	83	2861	164.10	66.30	42.30	99.00	59.90	2	30.50
			846	83	2888	163.70	66.50	44.10	99.20	29.80	1	30.20
			866	83	2785	163.90	66.00	41.60	99.30	0.00	1	28.80
			876	83	2788	163.80	66.50	42.70	99.00	30.00	1	26.30
			877	83	2795	163.20	66.30	42.40	99.40	0.00	1	20.90
			877	83	2807	163.60	66.00	42.00	99.20	59.90	2	21.80
			444	82	2670	162.50	65.80	43.50	99.20	35.20	1	24.90
			236	79	2609	163.50	66.20	40.50	99.20	0.00	2	19.00
			920	79	2444	163.50	67.00	41.50	99.30	23.00	1	99.90
			299	78	2572	164.80	66.20	39.80	99.20	29.80	1	18.50

Commentary on Crash:

The delta V in this crash is estimated by the accident investigation team to be 19 MPH. The crash impulse curves for comparison purposes are at Figures 088-1 through 088-2.

Significance of the Crash:

Statistics from the NASS data base tell us the occupants who are

unrestrained are 3 times more likely to be hospitalized as the result of a crash than those who are restrained. Twenty-nine percent of those unrestrained receive injuries of an AIS of greatre than or equal to 1. The speed and conditions of this accident make a fairly common one. Thirty-one percent of all rural crashes at about 45 MPH result in AIS ratings of equal to or greater than one and 41% of all passenger car crashes are in rural areas at 45 MPH. Women of age 35-44 are not, however, common in these accident conditions (17%). Left side hits are very popular scoring upwards of 48% of the occurrences. Further, where the intrusion is 2-6 inches as in this case, 66% will result in an AIS greater than or equal to 1. Left side interiors of the car are particularly likely to cause severe injury. About 11% of the time the AIS will be 2 or more.

In summary it can be said that this is a very common crash and that there are no real surprises in the severity of the injuries received and in the apparent contributing factors to the injury.

PSYCHOSOCIAL FOLLOW-UP - CASE 088

3 Months

At T + 3 months, this patient is back to work full-time, although not travelling as frequently on free-lance journalism assignments due to some difficulty and discomfort with ambulation which requires the use of a cane. The patient had returned to work part-time at T + 55 days after having stayed with friend until T + 42 days due to her inability to care for herself. The patient has employed a housekeeper to assist her and is in the process of buying a new car. Although renting a car, she drives only on weekends and has co-workers pick her up for work due to her shaken confidence level. The patient has been fortunate in being able to retain full salary and insurance benefits. Her supportive network of friends and business associates remain intact.

6 Months

Although patient feels her recovery to be progressing well, she is also readily aware that with the type of injury she sustained you are not totally "okay" and can get up in the morning feeling you do not have a fractured hip for at least one year post-trauma. Although patient ambulates without cane or devices and has no visible limp, she experiences some weakness on one side. She has also developed a bursitis (bulge on hip) necessitating removal of pins at approximately twelve months post trauma. Anti-inflammatory medications have helped although discomfort continues at times.

Patient drives on a daily basis and has purchased a new car, same make, bigger model. She feels fully readjusted to her work schedule putting in long hours and keeping up with work load.

She describes accident as having major impact on her life

stating she has intense irritability and acute awareness of careless drivers. She doesn't drive more than necessary and continues to avoid scene of accident and roadway where it occurred.

1 Year

Patient re-admitted to hospital for removal of pins in hip, followed by 6 weeks crutch-bearing ambulation. Patient re-located to be closer to work site and reduce driving time due to discomfort of travel. Patient taking more time off work to recover from surgery. Benefits and salary continue.

Although patient has returned to full-time work, physical and psychological effects of crash remain, and necessitated a new way of life for patient who is single and living alone.

PREVENTION AND INJURY REDUCTION - CASE 088

This crash may not have occurred had the driver of V2 not suffered a seizure, according to the Medical Advisory Board Unit of the State Department of Transportation. Before July of 1987, any person who suffered a seizure as a result of a seizure disorder automatically had his/her driver's license suspended for a period of 1 year. This assumes that the Medical Advisory Board is made aware of the problem. In July of 1987, the law was changed and the period of suspension was reduced to 3 months. This was a result of efforts by an organized lobby. If a person is found to have a seizure problem, and possesses or is applying for a valid driver's license, that person must obtain a doctor's report and go before the Medical Advisory Board for certification. We have no information as to the seizure history of the driver of V2.

Another problem concerning this crash is the design of the Bridge Overlap at the collision scene. The Bridge Overlap is a continuous raised concrete "curb like" structure that runs the entire length of the bridge. The problem is that the structure has beveled edges which allow vehicles to easily cross over it into opposing traffic. According to the State Traffic Engineering Division, this may be the only bridge median of this design in the State. Nobody knew the exact reason for the beveled edges, however, there are crossovers on each end of the Bridge Overlap which are marked for Emergency Vehicle Use Only. One opinion: The edges of the Bridge Overlap were beveled due to the fact that westbound fire trucks and other emergency vehicles must "U" turn in order to access developments on the eastbound side of the highway. This highway is currently being upgraded and widened to Interstate status which will probably aleviate the median and facilitate the placement of Jersey Barriers.

With regard to injuries, this is a classic case of the "low Delta V (19 m.p.h.) / serious injury" situation that exists in lateral impacts. Unfortunately, seatbelts do not address the

problem of lateral intrusion. The injuries to our case could have been reduced or even prevented by the deployment of a lateral air cushion restraint device. As seen in Crash Team photograph number 43, contact to the driver's door mounted arm rest obviously caused the pelvic and femur fractures. A redesign of the armrest which included an Air Bag device along with a sensor and substantial bracing in the driver's door might have reduced the driver's injuries if not completely eliminating them.

Another related vehicle design problem when dealing with side impacts is the decreasing side stiffness and thickness of some modern automobiles. Please refer to Crash Team photographs numbered 27 and 35. In photo number 35, we see the basically undamaged door structure of our case vehicle. The door is about 3 inches thick. Doors were once much thicker, but the real problem is shown in photograph number 27. The driver's door literally fell apart with a 19 mile per hour Delta V. It seems possible to prevent or reduce injury in side impacts by designing automobiles with greater lateral strength.

--- Jerry Jackson

PREVENTION COMMENTS - CASE 088

This accident occurred when a Dodge Omni (case occupant) was struck from the side and front by a Ford Escort. The case occupant was a 38-year-old female while the driver of the Escort was a 47 year old female diabetic who apparently, by report, was on a continuous insulin pump. The accident occurred when this diabetic suffered a hypoglycemic attack. The driver of the Escort apparently lost control impacting a guard rail and deflecting across the roadway into the case occupant demolishing the left front fender and left front side door. Our patient had pelvic fractures, ruptured spleen and a left femoral fracture.

In terms of prevention-clearly, the causation factor was diabetic coma and the driver of the Escort was a known diabetic on continuous insulin infusion. Probably, this type of individual should not be licenced to drive without a companion or some kind of dead man's grip which would automatically stop the car (a special handicap prevention). The second option solution would be to disallow driving altogether for patients on continuous insulin infusion. This certainly would have prevented the accident from occurring.

As far as the injuries to Case 088, it is clear both from the pictures of the crash (specifically numbers 088-25 through 088-27) and from the patients injuries, that the construction of the car demonstrated lack of protective support on the side and door panels. It is evident that the inward intrusion in this class of vehicle was a major factor in injury and also intruding structures such as the door arm rest may have been important components. A mandatory standard that established lateral construction protection from inward intrusion using steel

supports for the door which would act as a keystone arch would certainly have protected this driver. The abolition of intruding structures, such as the arm rest, would have possibly prevented the splenic injury which is directly correlated to a bruise on the side of the patient at the location of the door arm rest. The interior of the door might be designed so that all items that now protrude such as door handles, etc., be recessed with perhaps a push button mechanism that would make them accessible, when necessary.

These are the major factors that we feel would make a difference in almost all of these lateral injuries. The inadequacy of lateral door protection from intrusion, is a major structural weakness. Finally, the highways could be constructed with some type of Jersey barrier separating the two directions of traffic. In this particular accident, the problem was that the divided highway ended at the bridge so that there was no separation at this point. It is possible that in-bridge structures providing protection from crossing the median, could be established, especially on a four-lane high speed road. The idea would be to have a low-level concrete barrier that is high enough to prevent a vehicle from crossing the median.

COLLISION SCHEMATIC CASE 088

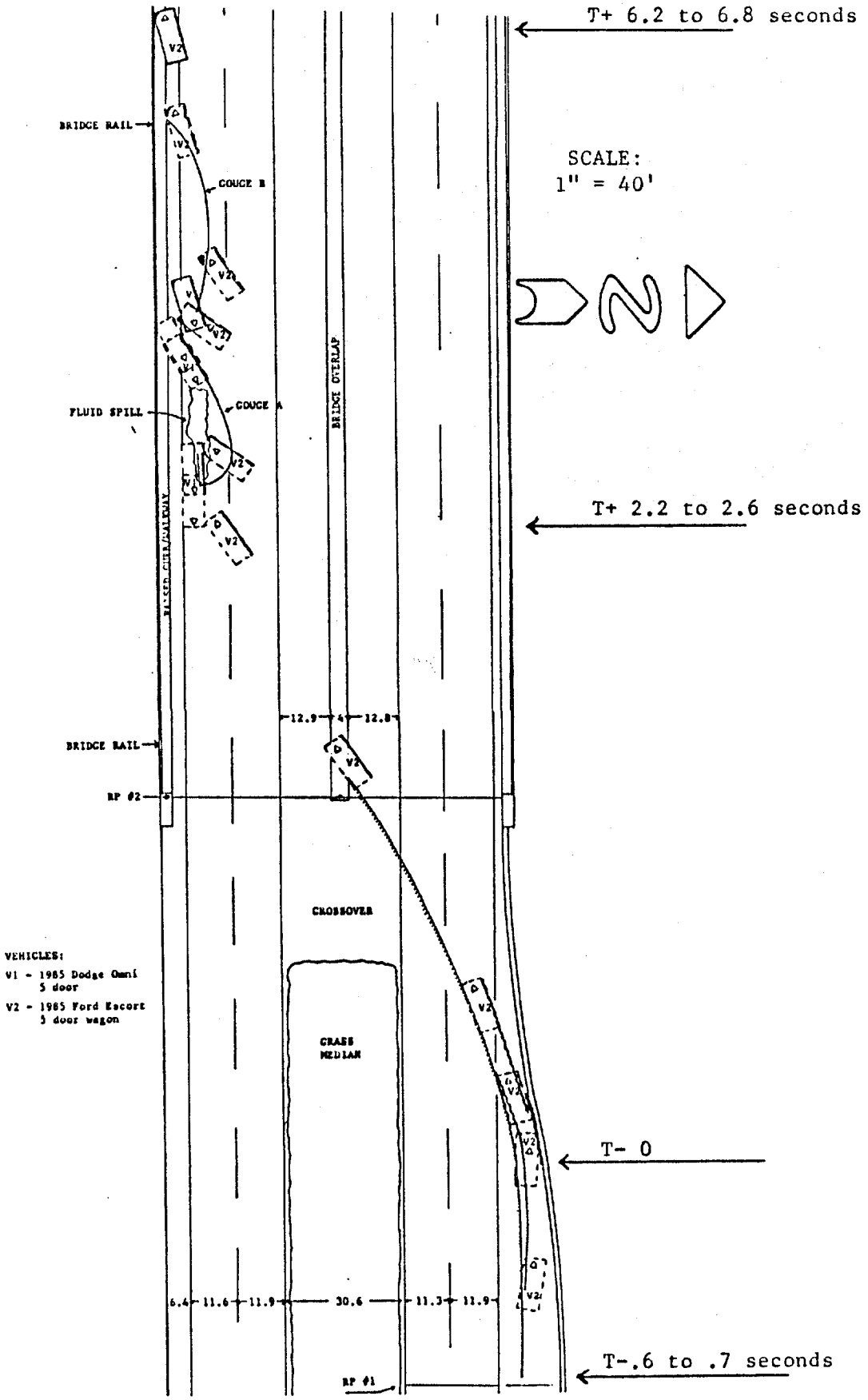

SELECTED PHOTOGRAPHS, CASE 088

1.



Scene. V2 direction of travel. First impact (gaurdrail on right). Impact with V1 (farthest lane to the left, middle of bridge).

2.

V1 (1985 Dodge Omni 5 door sedan). Left side impact. Max Crush = 10.3 inches. Delta V = 17 to 20 m.p.h. Door intrusion 5.5 inches.

SELECTED PHOTOGRAPHS, CASE 088

3.



V1 driver's position. Armrest contact (AIS-3 femur AIS-2 spleen/ pelvis. Window lever (thigh contact) upper door panel (head).

4.



V2 (1985 Ford Escort wagon). Frontal impact. Max Crush = 11.8 inches. Delta V = 17 to 20 m.p.h.

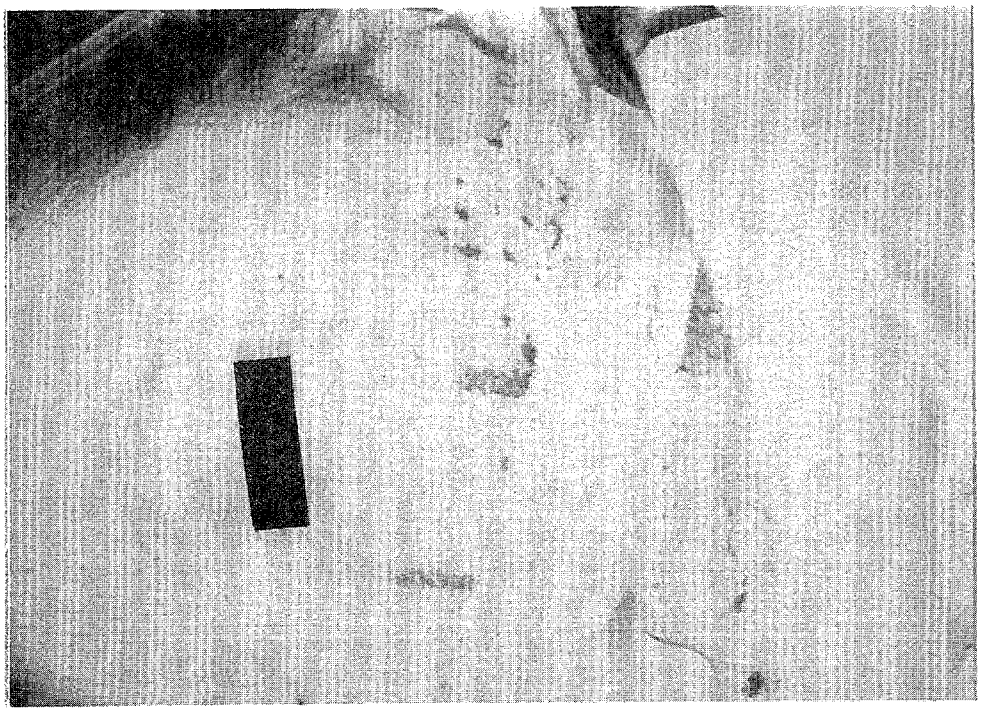

088A Multiple facial lacerations.

Contact Point- Unknown.
Type of Crash- Left lateral impact

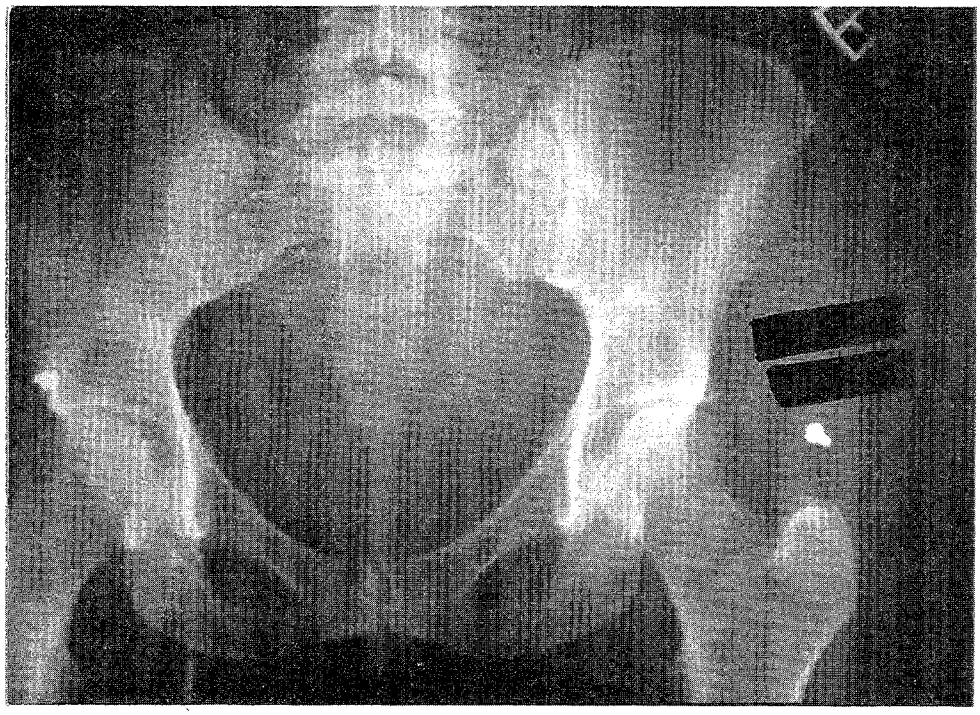

088B Pelvic X-Ray revealing a right pubic ramus fracture.

Contact Point- Left door panel
Type of Crash- Left lateral crash

SUMMARY - CASE 110 (003)

This accident occurred in the early morning hours of a weekday in the winter. It involved a 1987 Volkswagen Golf three door with two occupants impacting a fixed object (left side of vehicle and a 14 inch diameter utility pole). The driver lost control of the vehicle on a wet, two-lane asphalt road as he was attempting to negotiate a left-hand curve with a negative grade. As the driver lost control, the vehicle began a counterclockwise rotating broadside slide and departed the south edge of the roadway. After sliding an estimated 27'(feet), the vehicle impacted a cable (guy wire) and subsequently a 14 inch diameter utility pole. At impact #2, sufficient forces existed to cause Vehicle #1 to rotate approximately 150 degrees clockwise around the utility pole coming to a final rest facing north. The delta-V was calculated at 16.5 miles per hour using Crash PC. The driver sustained incapacitating injuries consisting of a closed head trauma, a "burst fracture" of the T-12 vertebra and a lateral compression pelvic fracture. The driver was transported, admitted and treated at a major trauma unit. The passenger was transported and treated at a local hospital for a scalp laceration. The vehicle was towed due to damage and was considered a total loss.

BODY CONTACTS AND INJURIES TABLE-CASE 110
20 year old male, driver, 1987 VW Golf, side impact

OIC/AIS CODE	ICD-9	CONTACTS OR INJURIES	CONTACT POINT
2HWKB2 541100	854.00	Closed Head Trauma	Roof
2CCCH4 979799	861.01	Myocardial Contusion	Unknown
2BSFS2 541100	806.25	T-12 Burst Fracture	Roof
2PAFS2 201102	808.2	Bilateral Pubic Ramus Compression Fracture	Left Door Panel
Unknown if Injured		Abraded Fabric	Right Front Seat Back
No Injury		Abraded Plastic	Right Inst. Panel
No Injury		Abraded Plastic	Left Inst. Panel

PSYCHOSOCIAL TIMELINE - CASE 110

Initial Interview

Patient is a 20-year-old single male who is one month post-injury following a motor vehicle accident where he was the only occupant in a single car accident involving alcohol. Patient is one of four children and the only one currently residing at home with both parents. At the time of the injury, he was a first-year college student and working part-time as a car rental agent to defray personal expenses. Family income

SELECTED PHOTOGRAPHS, CASE 356

3.



V1 and V2 shown in approximate impact positions. V2 - 1972 Chevrolet C-10 pickup.

4.

V1-1983 Honda Civic 1300 3-door Hatchback; frontal plane to frontal plane impact. Direct & induced damage-58" and maximum crush of 56.25" at C6 (right front bumper).

pillar and 7.3 inches laterally at the left "B" pillar.

T +.05 seconds: At this point, the intrusion to left side was forcing the left door panel into the driver's seat position. The driver sustained a lateral compression type pelvic fracture. A contact point was documented for this event on the left side seat back control knob at the right front seat. The driver's seat was forced into this adjacent seat by intrusion. The vehicle rotated after impact clockwise around the utility pole approximately 150 degrees and came to rest facing north. As the vehicle rotated, the left rear panel was cut by a switching bracket in a downward pattern as the rear of the vehicle became elevated. As the deceleration forces and rotation stopped, the driver's seat back had distorted rearward and allowed the driver to be propelled upward striking the roof with the top of his head. An occupant contact point was found on the roof just behind the driver's position. This contact point shows evidence of a heavy head impact with rearward and upward motion. The roof panel was substantially deformed with abrasions to the fabric and also contained hair deposits. The driver sustained a closed head injury and a burst type fracture of the T-12 vertebra.

T + 1 mins: Passing motorist notified Maryland State Police of the accident.

T + 5 to 10 mins: Maryland State Police arrived and started medical treatment.

PREHOSPITAL AND HOSPITAL TIMELINE - CASE 110

T+2min: Ambulance receives call to respond.

T+3min: Ambulance arrives at scene. Assessment initially reveals a blood pressure of 180/90, a pulse of 120, respiration of 24, and a Glascow Coma Score of 14. Advanced life support was initiated in the field.

T+30min: Patient departs scene by Maryland State Police helicopter for MIEMSS/Shock Trauma.

T+61min: Patient arrives at MIEMSS. Initial physiologic assessment of the patient reveals a blood pressure of 155/73, a pulse of 93, a respiratory rate of 24, and a Glascow Coma Score of 15. The patient's ISS was = 17. Toxicology screen was positive for alcohol. Clinical care provided includes the following:

- -Evaluation by a MIEMSS trauma team,
- -Fluid resuscitation,
- -Full diagnostic evaluation including x-rays of the cervical spine, chest and pelvis. In addition to the toxicology screen, an arterial blood gas, a CBC (complete blood count), an SMA-6 (regular blood chemistry) and a UA (urinalysis) were performed.
- -Cardiac monitoring, serial EKG's, and cardiac enzymes analysis

Injuries noted include:

- -Closed head injury

-Burst fracture of T-12 vertebra
-Myocardial contusion
-Fractured pubis ramus-bilateral compression type.

Operative procedures include:
-Stabilization of T-12 fracture with Harrington Rods and a bone graft.

No complications were reported on this patient during the acute care phase.

T+24hours - 8days: Patient spends 4 days in intensive care and 4 days in intermediate care.

T+8days: Patient was discharged to home able to both ambulate without assistance and to resume limited activities.

CRASH COMPARISON
CASE # 110

Overview

The following table contains data that was extracted from the NHTSA vehicle database, based on vehicle make, vehicle model, body type, production year, weight, and general physical measurements. The center of gravity, speed and vehicle # have also been included. A system of data retrieval using INGRES "views" and report formats has made the extraction of general preliminary data much easier, and less time consuming than in previous retrievals. This type of query eliminates the need to perform redundant retrieval processes.

Although a query of this type is useful for gathering basic data, a more detailed query for selected cases chosen from this table is constructed per individual case, to include all possible cases that may contain useful information. For example it may be necessary to search for a list of all vehicles that fall within a certain weight range (say +/- 500 lbs.) or traveling within a given range of speed (say +/- 15 mph). In this example, finer case-specific data is retrieved.

After these searches, for cases that are deemed "close matches", an exhaustive report (15-20 pages long) including instrumentation specifics are generated, and used as necessary for the reconstruction.

22-MAY-1989 16:06:51

VOLKSWAGEN GOLF
Report on Table: VEW000A

Mak	Mod	Bod	T#	YR	LBS.	Length	Width	COG	Wbase	Speed	V#	Crush
08	01	3H	1272	88	2660	157.90	65.00	40.70	97.60	0.00	2	13.90
			898	86	2621	158.00	65.50	37.30	97.30	30.10	1	22.50
			903	86	2677	157.90	65.80	38.00	97.60	30.00	1	22.30
			260	85	2650	158.00	65.50	42.40	97.10	0.00	2	13.20

4S	945	86	2620	158.30	65.50	42.30	97.30	34.90	1	21.90
5H	1053	87	2716	156.40	65.20	43.00	97.20	29.50	1	19.10

PSYCHOSOCIAL FOLLOW-UP - CASE 110

3 Months

The patient has returned to full time versus part-time work at T + 100 days. The patient has not returned to school mid-semester but hopes to continue at a later date. The patient's use of alcohol has decreased since the injury and he feels that he is well and doing most things that he did prior to the injury, feeling satisfied with relationships and work status. He continues to drive and describes no residual effects as a result of injuries sustained, although he states that it takes longer to accomplish some tasks.

6 Months

Twenty (20)-year-old single white male discharged from Shock Trauma following 9 days hospitalization with no rehabilitation services. Patient returned to full-time vs. part-time work 100 days post-trauma. Patient has not returned to school due to mid-semester but hopes to continue at later date. Patient's use of alcohol has decreased since injury and he feels he is well and doing most things he did prior to injury, feeling satisfied with relationships and work status. He continues to drive and describes no residual effects as a result of injuries sustained although states it takes longer to accomplish some tasks.

1 Year

Patient fully recovered and resuming pre-injury activities. No residual effects of injury noted. Successful return to pre-morbid status and achievement of life goals.

CRASH AND INJURY PREVENTION IDEAS - CASE 110

This accident occurred as a result of excessive speed for existing conditions. Continuous drivers' education beyond licensing and speed control devices for younger, inexperienced drivers assisted the driver to better deal with the conditions. Increased side impact protection through air cushions or overall improved door stiffness probably would have reduced the severity of the impact associated injuries.

PREVENTION COMMENTS - CASE 110

This is a twenty-year-old male with a previous documented

single vehicle accident involving alcohol one month prior to the present injury. His present injury occurred while trying to negotiate a turn at a somewhat excessive rate of speed. The driver was toxicology positive for alcohol. He sustained closed head injuries, a T-12 burst fracture, myocardial contusion, and an anterior-posterior pelvic ramus fracture. What is striking about this is, of course, a previous history of an accident involving alcohol in a patient who was drinking at the time of this accident as well as exceeding the speed limit. The need for a mandatory suspension of a drunken driver's license after an accident regardless of whether the accident produces damage to other individuals is a way of forcing the driver into appropriate alcohol abuse therapy. Clearly, one month later this patient was still drinking and this contributed to the accident.

Secondly, as in other studies with small cars of this sort, the lateral occupant protection is very poor, with considerable intrusion of the door into the car occurring on impact. Another important factor in this particular case is the fact that the driver's seat did not remain in an upright position, but collapsed backward as the impact force was applied, allowing the patient to be projected toward the roof posterior to the front door support striking his head and then transmitting the force down to T-12 where, as mentioned previously, he had a burst fracture. He was also not wearing a seatbelt so the combination of inadequate seatbelt use and the collapsible seat should be addressed. The seat standard should be strengthened, so it cannot collapse. There was some steering wheel deformity which probably accounts for the myocardial contusion and an airbag might have prevented the head impact and also protected him to some degree from his anterior-posterior pelvic fracture. Furthermore, the use of a three-point seatbelt would have aided in preventing his T-12 fracture because even with normal seatbelt usage there still is a tendency to be directed upwards in a collision. The other point is that the roof on this vehicle is quite close to the driver's head. This is another design feature that might be looked at in terms of not only providing padding but also mandating a minimum distance as a standard, which will reduce the likelihood of head to roof impacts.

The unusual aspect of injury in this case stems from the collapse of the seat back causing, as previously stated, the patient to be projected upward into the roof of the car. That in turn caused an axial loading of the thoracic spine which led to his T-12 burst fracture.

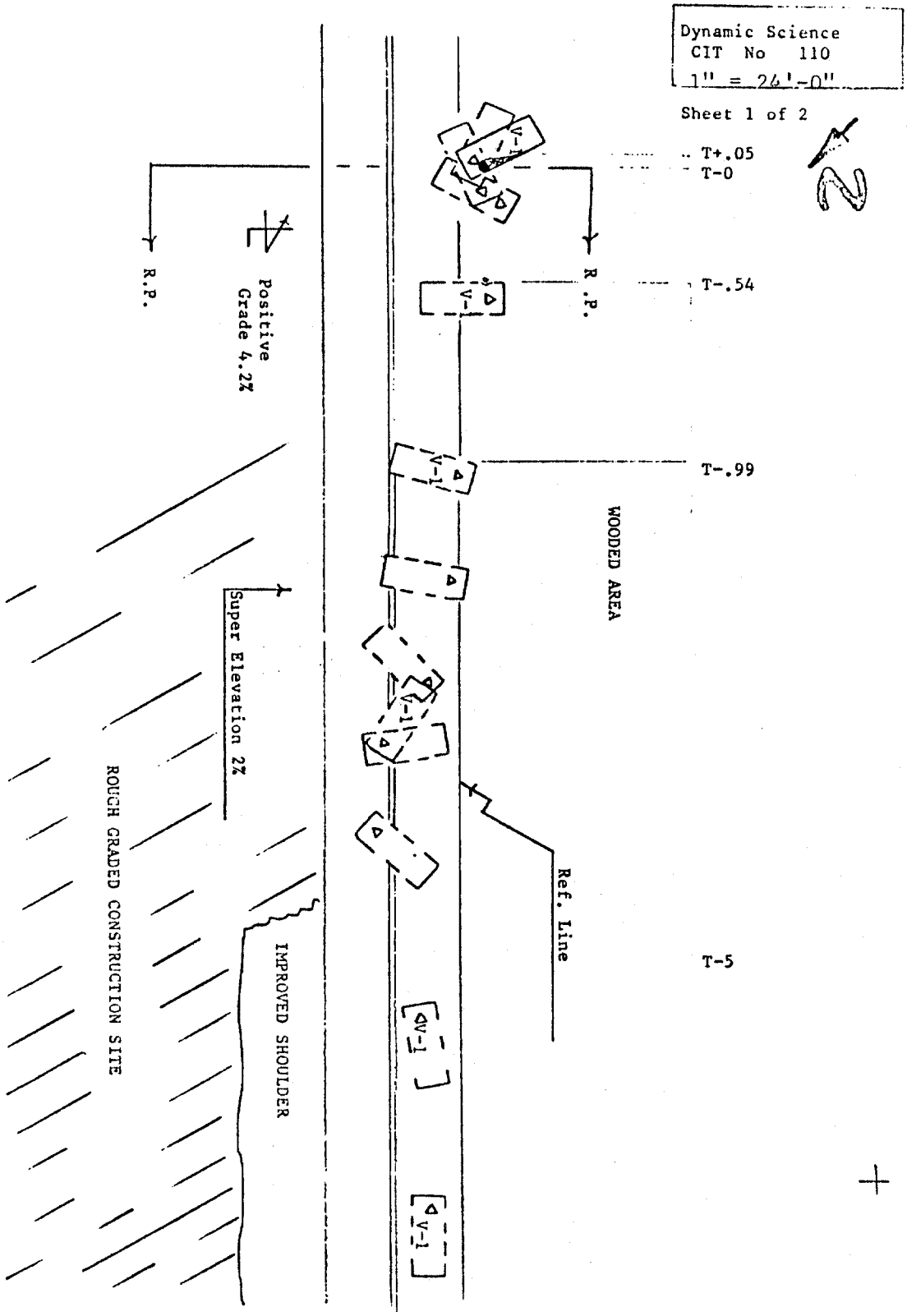
Dynamic Science
CIT No 110
1" = 24'-0"
Sheet 1 of 2
T+.05
T-0
T-.54
T-.99
T-5
R.P.
R.P.
Positive
Grade 4.2%
WOODED AREA
Ref. Line
Super Elevation 2%
ROUGH GRADED CONSTRUCTION SITE
IMPROVED SHOULDER
V-1

Dynamic Science
CIT No 110
1" = 24'-0"

Sheet 2 of 2

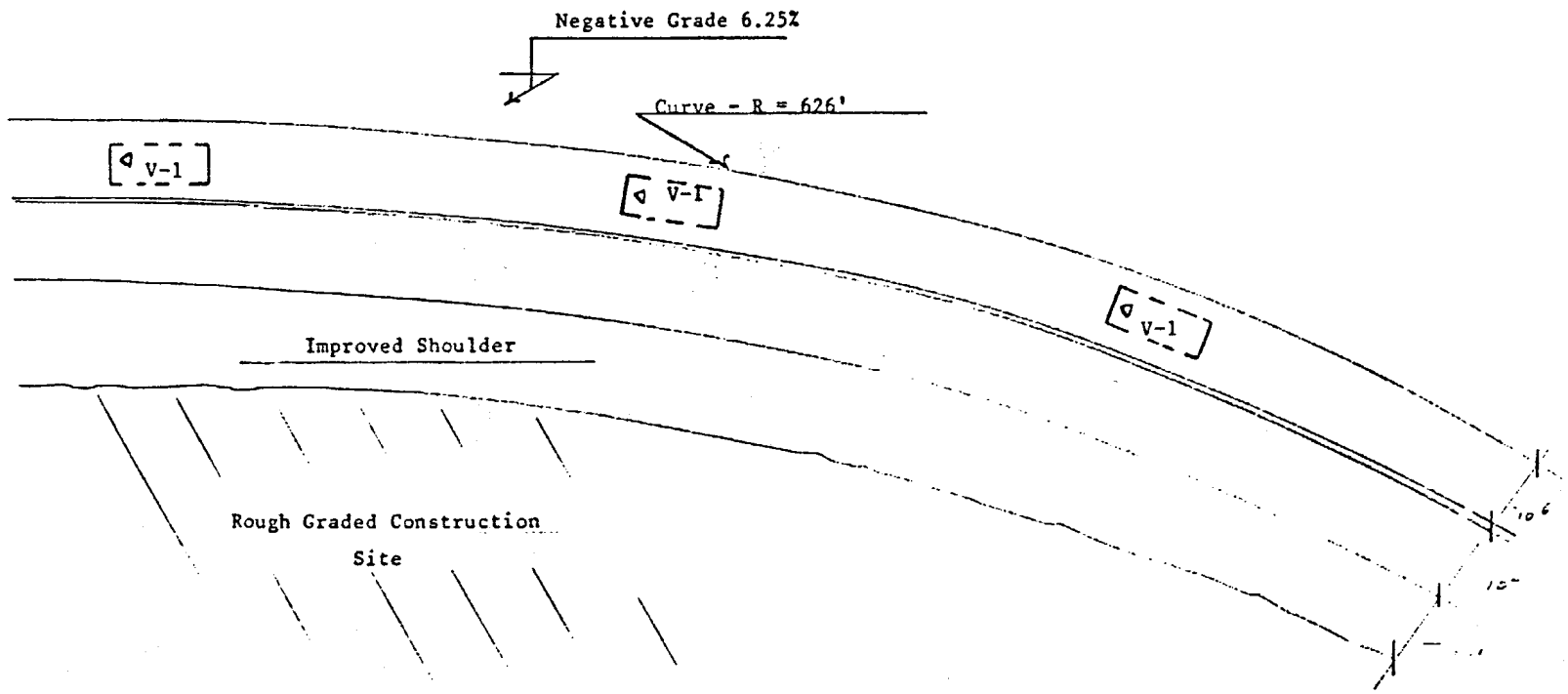

SELECTED PHOTOGRAPHS, CASE 110

1.



View from Vehicle 1's path of travel.

2.

View of impact area from opposite direction of travel. First impact is guy wire behind the pole; second impact is with the 14 inch telephone pole.

SELECTED PHOTOGRAPHS, CASE 110

3.

V1′ (1987 Volkswagen Golf 3 door); multiple impacts with fixed object. Max crush = 16.1 inches at left door panel. Intrusion of 11.6 inches at door panel into the driver's area caused

SELECTED PHOTOGRAPHS, CASE 110

4.



seat deformation and the driver sustained a lateral compression type pelvic fracture.

5.



Driver's seat distorted rearward; driver propelled upward. Roof contact point contributed to burst type fracture of T-12 vertebrae. Driver sustained myocardial contusion due to impact forces.

110A X-Ray revealing a burst type fracture of the T-12 spine. The fracture pattern is indicative of hyperflexion and axial loading to the spine.

Contact Point- Roof
Type of Crash- Left lateral impact

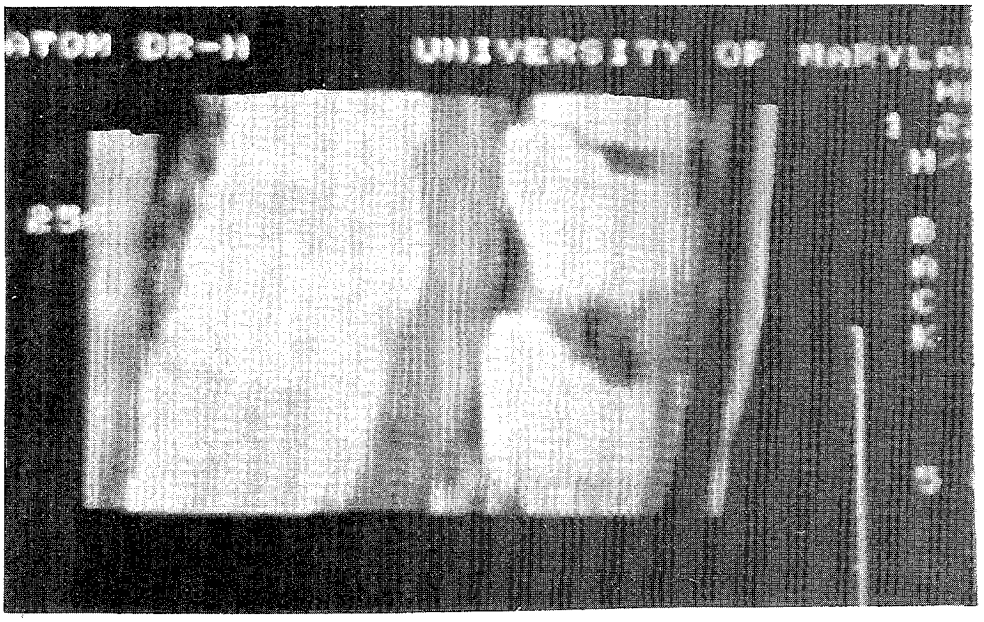

110B CT Scan revealing a burst type fracture of the T-12 spine.

Contact Point- Roof
Type of Crash- Left lateral impact

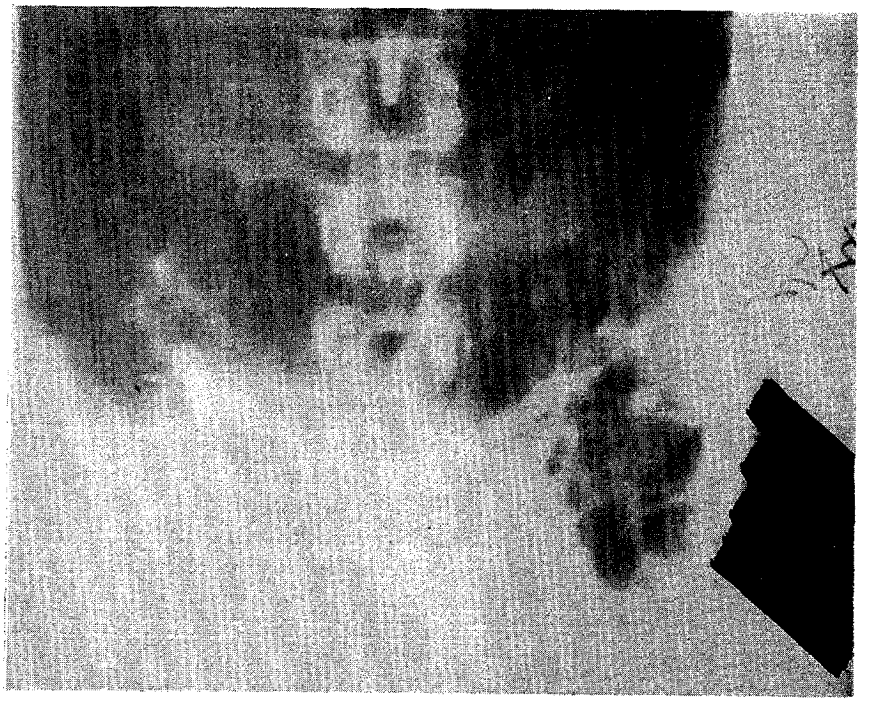

110C X-Ray revealing a burst type fracture of the T-12 spine.

Contact Point- Roof
Type of Crash- Left lateral impact

SUMMARY - CASE 484 (004)

This three vehicle collision occurred on a clear, fall, weekend night. The collision involved a 1982 Plymouth Sapparo two door sedan with one 24 year old male occupant, a 1982 Pontiac Trans Am three door sedan with one 35 year old female occupant, and a 1987 Suzuki Samurai multi-purpose vehicle with one 23 year old female occupant. The Plymouth and the Suzuki were westbound on a dry 5 lane asphalt arterial street in a residential area. The Pontiac was eastbound at high speeds on the same street. The roadway was illuminated by street lights and was straight and level with a posted speed limit of 40 miles per hour. The Pontiac crossed the center left turn lane and struck the Plymouth head-on. The Plymouth was forced backward (east) and north where it was impacted in the left rear fender by the front of the Suzuki. The second collision was very minor and produced no injuries. The driver of the Pontiac, who was not using the available lap and shoulder belt, was killed upon impact with the Plymouth. The driver of the Plymouth, our case index, was severely injured and was transported to a trauma center for treatment. He was not using the available lap and shoulder belt. The driver of the Suzuki was reported to have worn a lap and shoulder belt and was also reported as possibly injured. She was not transported to a medical facility for treatment. Injuries sustained by our case index are listed below in OIC format.

BODY CONTACTS AND INJURIES TABLE-CASE 484
24 year old male, driver, Plymouth Sapparo, frontal impact

OIC/AIS CODE	ICD-9	CONTACTS OR INJURIES	CONTACT POINT
2HICB5 221102	851.0	Basil Ganglia/Thalamic Cont.	Left A Pillar
2HLUB3 221102	853.0	Intraventricular Hemorrhage	Left A Pillar
2FRFS2 221102	802.20	Mandible fracture	Left A Pillar
2FILI1 221102	910.8	Chin laceration	Left A Pillar
2FULI1 221102	910.8	Face laceration	Left A Pillar
2FRFS2 221102	802.4	Zygomatic Fracture	Left A Pillar
2CCCH4 061100	861.01	Myocardial Contusion	Steering Hub
2MLRQ2 051100	865.02	Ruptured Spleen	Steering Wheel
2PLZJ3 201104	808.0	Acetabular FX/Dislocation	Left Door Panel
2QRFS2 561101	825.0	Lateral Talar Fracture	Toe Pan
2MLAI1 201104	911.0	Left Anterior Abdomen Abrasion	Left Door Panel
2MLCI1 201104	911.0	Left Anterior Abdomen Contusion	Left Door Panel

2MLAI1	201104	911.0	Left Posterior Abdomen Abrasion	Left Door Panel
2MLCI1	201104	911.0	Left Posterior Abdomen Contusion	Left Door Panel

PSYCHOSOCIAL TIMELINE - CASE 484

Initial Interview

Patient is a 24-year-old black male driver and single occupant sustaining multiple trauma following a motor vehicle accident involving 3 cars. Driver of other vehicle was drinking and was DOA. Patient is married with a two-year-old daughter, having a high school degree and a primary occupation as a bricklayer. Although unemployed at the time of the accident, he still receives health insurance coverage and family is in the process of applying for Medical Assistance. Patient lives with wife and child and is described by family as a hard worker being self-employed during the winter months and returning to construction work with a company he has been with for five years. At the time of the accident, patient was enroute to an aunt's funeral. Family describes close family relationships, although some competition between wife and mother is evidenced. Family currently receiving unemployment compensation and income as free-lance bricklayer ranging between $10,000-$20,000.

Patient described as outgoing, and interested in music (D.J.) and athletics, although somewhat immature. Family denies patient's use of alcohol, drugs or nicotine.

Patient was discharged to Rehabilitation Institution 34 days status post-trauma.

CRASH TIMELINE - CASE 484

T - 5 seconds: V1, a 1982 Plymouth Sapparo 2 door sedan was westbound in the inside westbound lane of a dry 5 lane asphalt arterial street. V2, a 1982 Pontiac Trans Am 3 door sedan was eastbound on the same street at an estimated speed of 75 to 82 miles per hour. V3, a 1987 Suzuki Samurai multi-purpose vehicle was westbound in the outside westbound lane of the same street. The street was illuminated by street lights and the accident occurred on a clear weekend night in a residential area. The roadway is level and straight and bordered by a continuous 8 inch concrete curb. The outside and inside westbound lanes are 14.5 and 10.3 feet wide respectively and separated by a broken white line. The center turn lane is 10 feet wide and bordered on each side by a broken and a solid yellow line. The outside and inside eastbound lanes are 12.9 and 11.3 feet wide respectively and separated by a broken white line.

The driver of V2 was a 35 year old female who was not using the available lap and shoulder belt. The driver of V1 was a 24 year old male who was not using the available lap and shoulder belt. The driver of V3 was a 23 year old female who was reported as using a lap and shoulder belt. As the eastbound V2 approached the collision area, the vehicle crossed the center turn lane and entered the oncoming inside westbound lane. The drivers of both V1 and V3 were applying brakes by this time.

T - 0 seconds: The front of V2 impacted the front of V1. At maximum engagement V1 sustained 53.3 inches of longitudinal crush to the left front bumper corner. The toe pan at the driver's position intruded longitudinally 16.7 inches. The A pillar at the driver's position intruded longitudinally 13.3 inches and laterally 4.4 inches. The left side/kick panel and left door panel intruded laterally 11.4 and 7.2 inches respectively. Upon impact, the driver of V1 was forced toward the left A pillar. There was heavy abdomen/chest contact to the steering wheel rim and hub, deformed and abraded left door panel surfaces and two deep dents in the left A pillar from a high speed head impact. Due to extensive altering of the vehicle interior damage by rescue personnel, only these four occupant contacts were found. The driver of V1 suffered a right basal ganglia/thalamic contusion, a left intraventricular hemorrhage in the lateral ventricle, a right subcondylar mandible fracture with medial displacement, a right zygomatic fracture, a ruptured spleen, a left acetabular fracture with hip dislocation, a nondisplaced fracture of the right lateral talar bone, a myocardial contusion, and chin and face lacerations. A wooden speaker box was forced forward from the rear deck behind the right rear seat. The box impacted the windshield on the passenger side leaving two small spider web type fractures with embedded wood fibers in the glass. The driver's left shoe was reported to have an imprint of the brake pedal pad imbedded in the sole. V1 began counter-clockwise rotation at impact and was forced backward (east) and north. At maximum engagement, V2 sustained 57.5 inches of longitudinal crush at the left front bumper corner. The toe pan at the driver's position was intruded longitudinally 13.1 inches. The A pillar at the driver's position was intruded longitudinally 9.4 inches and laterally 2.3 inches. The left side/kick panel was intruded laterally 8.2 inches and the driver's seat back intruded backward 9.6 inches due to occupant rebound action. The driver's abdomen, chest, and head caused a total collapse of the steering wheel rim as her body was forced forward at impact. There was a subsequent head impact to the upper left instrument panel evidenced by broken plastic and tissue deposits. The left lower instrument panel had a skin transfer and the plastic was broken indicating a knee impact. The driver of V2 was fatally injured. The tachometer gauge was pinned at impact and indicated an engine speed of 5000 revolutions per minute. While engine speed is not directly indicative of vehicle speed in this case, an engine speed of 5000 revolutions per minute in a standard automobile such as this one does indicate heavy acceleration. The driver's

right shoe was found to be embedded in and stuck to the accelerator pedal. V2 began counterclockwise rotation at impact and continued east.

T + 1 second: At this point, V1 had rotated counterclockwise approximately 60 degrees after impact with V2. V1 had also been forced to the northeast approximately 12 feet from the point of impact. V1 was now positioned in the outside westbound lane facing southwest. The front bumper of V3 then impacted the left rear fender of V1 causing additional counterclockwise rotation to V1 and clockwise rotation to V3. The damage length on V1 from this impact was measured to be 33.9 inches with a maximum lateral crush of approximately 3.5 inches. V3 was not located for inspection, but this minor impact had no effect on the injuries sustained by the case index.

T + 1.6 seconds: V1 came to rest facing due south in the outside westbound lane. V3 came to rest facing due north and positioned beside and parallel to V1.

T + 1.8 seconds: V2 came to rest approximately 70 feet east of the point of impact with V1. V2 was facing north in the eastbound lanes after approximately 55 degrees of rotation.

T + 1 minute: The police were notified that the collision had occurred.

T + 4 minutes: The police arrived at the scene.

PREHOSPITAL AND HOSPITAL TIMELINE - CASE 484

T+ 2min.: Ambulance receives call to respond.

T+ 5min.: Ambulance arrives at scene. Initial field assessment reveals a blood pressure of 160/PALP, a heart rate of 88, a respiratory rate of 22, and a Glasgow Coma Score of 7. Care provided includes full spinal immobilization with backboard.

T+ 71min.: Patient departs location enroute to MIEMSS by Maryland State Police medevac helicopter.

T+ 77min.: Patient arrives at MIEMSS/Shock Trauma. Initial physiologic assessment of the patient reveals a blood pressure of 160/100, a heart rate of 100, a respiratory rate of 16, and a Glasgow Coma Score of 7. The patient's ISS (Injury Severity Score) was = 41. Toxicology screen reveals negative results. Initial care provided includes the following procedures:

- -Evaluation by a MIEMSS trauma team,
- -Fluid resuscitation,
- -Full diagnostic evaluation including x-rays of the cervical spine, chest and pelvis. In addition to the toxicology screen, an arterial blood gas, a CBC (complete blood count), an SMA-6 (routine blood chemistry) and a UA (urinalysis) are performed.
- -Casting of his talar fracture.

Injuries noted include:

- -Basal Ganglia/Thalamic contusion,

-Intraventricular hemorrhage,
-Facial lacerations,
-Right mandible fracture,
-Right zygomatic fracture,
-Myocardial contusion,
-Ruptured spleen,
-Abdominal abrasions/contusions,
-Left acetabular fracture/dislocation,
-Right lateral talar fracture.
-Right 5th proximal metatarsal
-Right 1st cuneiform fracture.

The following operative care is provided:

-Tracheostomy due to prolonged mechanical ventilation,
-Intermaxillary fixation of mandible fracture,
-Diagnostic peritoneal lavage (grossly positive),
-Exploratory laparotomy,
-Splenectomy
-Internal fixation of acetabular fracture.

The patient develops the following complications: bilateral pneumothoraces and pneumonia.

T+24 hours - 33 days: Patient spends 26 days in intensive care and 7 days in the intermediate care unit.

T +33 days: Patient discharged to instate inpatient Rehabilitation Hospital.

COGNITIVE-COMMUNICATIVE ASSESSMENT - CASE 484

The patient was initially evaluated on T + 20 days. He exhibited minimal responses to stimulation at that time. He was unable to complete the MIEMSS assessment protocol due to severe cognitive-communicative deficits. The patient was felt to be functioning at an RLAS II- Generalized Response- level (Rancho Los Amigos Score.) Intensive therapy was recommended. Hearing could not be assessed. Swallowing could not be assessed as the patient was NPO, or unable to be administered anything orally.

The patient received daily treatment sessions and progressed rapidly.

The patient was re-evaluated prior to discharge to a rehabilitation center on T + 33 days. Moderate deficits continued to be noted across all areas assessed. The patient was felt to be at an RLAS VI- Confused/ Appropriate Response level. It was recommended that the patient continue to receive inpatient rehabilitation. The patient's hearing skills were within normal limits as he passed the screening and he was released on a P.O., or oral, diet.

Follow-up to be conducted at T + 6 months.

CRASH COMPARISON
CASE # 484

Overview

The following table contains data that was extracted from the NHTSA vehicle database, based on vehicle make, vehicle model, body type, production year, weight, and general physical measurements. The center of gravity, speed and vehicle # have also been included. A system of data retrieval using INGRES "views" and report formats has made the extraction of general preliminary data much easier, and less time consuming than in previous retrievals. This type of query eliminates the need to perform redundant retrieval processes.
Although a query of this type is useful for gathering basic data, a more detailed query for selected cases chosen from this table is constructed per individual case, to include all possible cases that may contain useful information. For example it may be necessary to search for a list of all vehicles that fall within a certain weight range (say +/- 500 lbs.) or traveling within a given range of speed (say +/- 15 mph). In this example, finer case-specific data is retrieved.

After these searches, for cases that are deemed "close matches", an exhaustive report (15-20 pages long) including instrumentation specifics are generated, and used as necessary for the reconstruction.

22-MAY-1989 16:07:53

PLYMOUTH SAPPORO
Report on Table: VEW000A

Mak	Mod	Bod	T#	YR	LBS.	Length	Width	COG	Wbase	Speed	V#	Crush
05	10	2C	278	81	3247	179.70	65.90	48.90	100.00	0.00	2	16.10
			385	81	3191	179.70	65.90	45.60	100.00	0.00	2	12.40
			120	78	3093	183.00	66.70	49.70	99.00	0.00	2	15.00

PSYCHOSOCIAL FOLLOW-UP - CASE 484

3 Months

The patient remained at the rehabilitation facility until T + 3 months and was discharged to home with continued physical and occupational therapy prescribed. The patient is ambulating with crutches, working hard at physical therapy and has surpassed rehabilitation goals with early discharge. Cognitively, the patient is doing well and has made a remarkable recovery with minimal speech deficits, slight speech delay and no major residual effects. The patient has returned home to family although some marital problems are evidenced. These were also

present prior to injury. Apparently the driver of one of the vehicles involved in the collision visits the patient frequently and has, "fallen in love with him." The patient remains a handsome, outgoing man, friendly and charming with a good sense of humor.

6 months

Twenty-four (24)-year-old married black male discharged from acute hospital 34 days post-trauma to inpatient rehabilitation where he remained for 2 months. He was than discharged home and continued with occupation and physical therapy for 3 months ambulating with crutches. At 6 months, patient feels well and doing most pre-injury activities. Although he ambulates more slowly and exhibits minimal speech deficits and delays, he is doing well cognitively. He describes reflexes as slower but has returned to bike riding and plans to begin driving car soon.

Patient has not returned to work due to unemployment insurance benefits and wanting time to sort out career direction. Patient planning to return to work next month as brick mason. He states religion plays more important role in life and injury has affected relationships in positive way. Patient is currently covered by medical assistance. Patient feels well and more satisfied and appreciative of role as spouse and parent. Patient has no limitations or restrictions at present time. He continues to live with his wife although some marital problems evidenced, but these existed pre-injury as well.

1 Year

Patient returned to full-time work 8 months post-trauma. He continues to work in the construction field, brick mason, laying tiles and driving truck. Although he has a slight limp, it is hardly noticeable. Speech appears to be greatly improved with no noticeable delays.

Patient has made remarkable recovery with little evidence of any deficits. He is a handsome, outgoing man, friendly and charming with a good sense of humor.

PREVENTION AND INJURY REDUCTION - CASE 484

The Police officer who was on the scene after this head-on crash stated that there were open alcoholic beverage containers in V2 and a strong odor of alcohol about the deceased driver of V2. The roadway was dry, straight, level, and lighted. The 5 lanes were wide and well marked. Most people would consider this to be a very safe roadway by design, but no roadway is safe when it is being traveled by a vehicle whose operator is under the influence of alcohol. From a strictly mechanical point of view, the case vehicle held up fairly well considering the 41 mile per hour Delta V, but there is at least one problem with this type of high speed frontal that could be addressed in vehicle design. With frontal Delta V's above 30 miles per hour,

one often sees rearward displacement of the front wheels. In collisions such as this one, the front wheel can cause severe intrusion to the occupant compartment. Perhaps this problem could be reduced or even eliminated in some cases by substantial bracing of the Dash Panel (or Fire Wall as it is sometimes called).

This idea is part of the more comprehensive idea of actually designing an integral "Roll Cage" within the passenger vehicle structure. We have all seen the benefits of Roll Cages in the construction of race cars with regard to minimizing intrusion. With Roll Cages, we tend to lose the luxury of doorways but with redesigned door latch and hinge systems, the door latch and hinge could be an integral part of the cage. In today's automobiles, door latches are usually nothing more than a Hook that clamps over a small metal Rod. A system that uses a Roll Cage could have a continuous structural tube through the "B" pillar and the door which branches out inside the door and continues through the hinges. The latch mechanism would not be unlike a "Deadbolt" which when latched, would slide into the tubing ends at the normal "B" pillar mount as well as at the hinges. This configuration would allow normal door function as well as offering the benefits of a full Roll Cage. In emergency situations, an electrically actuated latch system of this type could have additional manual release mechanisms.

Another obvious preventative measure regarding injuries in this particular crash is the addition of a Steering Hub mounted driver's Air Bag. With a collision of this severity, it would be unreasonable to assume that a driver's Air Bag would have prevented injury, however, the two most serious injuries involved the head and chest, and there is reason to believe that the severity of these injuries would have been greatly reduced had the vehicle been equipped with an air cushion restraint system. In fact, the Myocardial Contusion (AIS-4) may have been prevented had a driver's Air Bag deployed, and had the driver been using the available manual restraints.

All of the complex preventative mechanical changes that could be applied to this case and others like it still do not address the basic problem that drunk drivers present.

---- Jerry Jackson

PREVENTION COMMENTS - CASE 484

This was a three car collision in which the driver of a Plymouth Sapporo who was apparently under the influence of alcohol, cocaine, and PCP, crossed the center line and struck the patient's car from the front and left lateral direction completely crushing the front of the car and with severe damage to the left front door. The patient sustained severe face and head injuries by impact with the A-pillar which was driven back into the car, a myocardial contusion from striking the steering hub, and a ruptured spleen from striking the steering wheel. The

left front tire, which was driven back into the floor panel apparently impacted on the left foot so the patient had a left lateral talus fracture. He also had injuries to the left side of the abdomen due to the left door intrusion.

As for prevention-obviously restrictions as far as driving under the influence of alcohol and drugs are important here. Again, some sort of legislation mandating loss of license for any accident in which drugs or alcohol are involved would go a long way to forcing individuals, like the initiator of this accident perhaps to abstain from drinking or taking drugs while driving. Secondly, again the same problems noted in other cases; the lateral structural protection is very poor, since the door was driven well into the car, strong strengthening of the side of the car with some kind of steel supports would have reduced the intrusion into the occupant compartment. Also, the toe pan needs to be strengthened so that the wheel intrusion is less likely to occur. This would greatly protect the lower extremities from injury. Furthermore, an air bag would undoubtedly have protected this patient to some degree from his head injury based on an impact with the A-pillar and may also have prevented his myocardial contusion and ruptured spleen which occurred on impact with the steering hub and wheel, respectively.

COLLISION SCHEMATIC
CASE 484

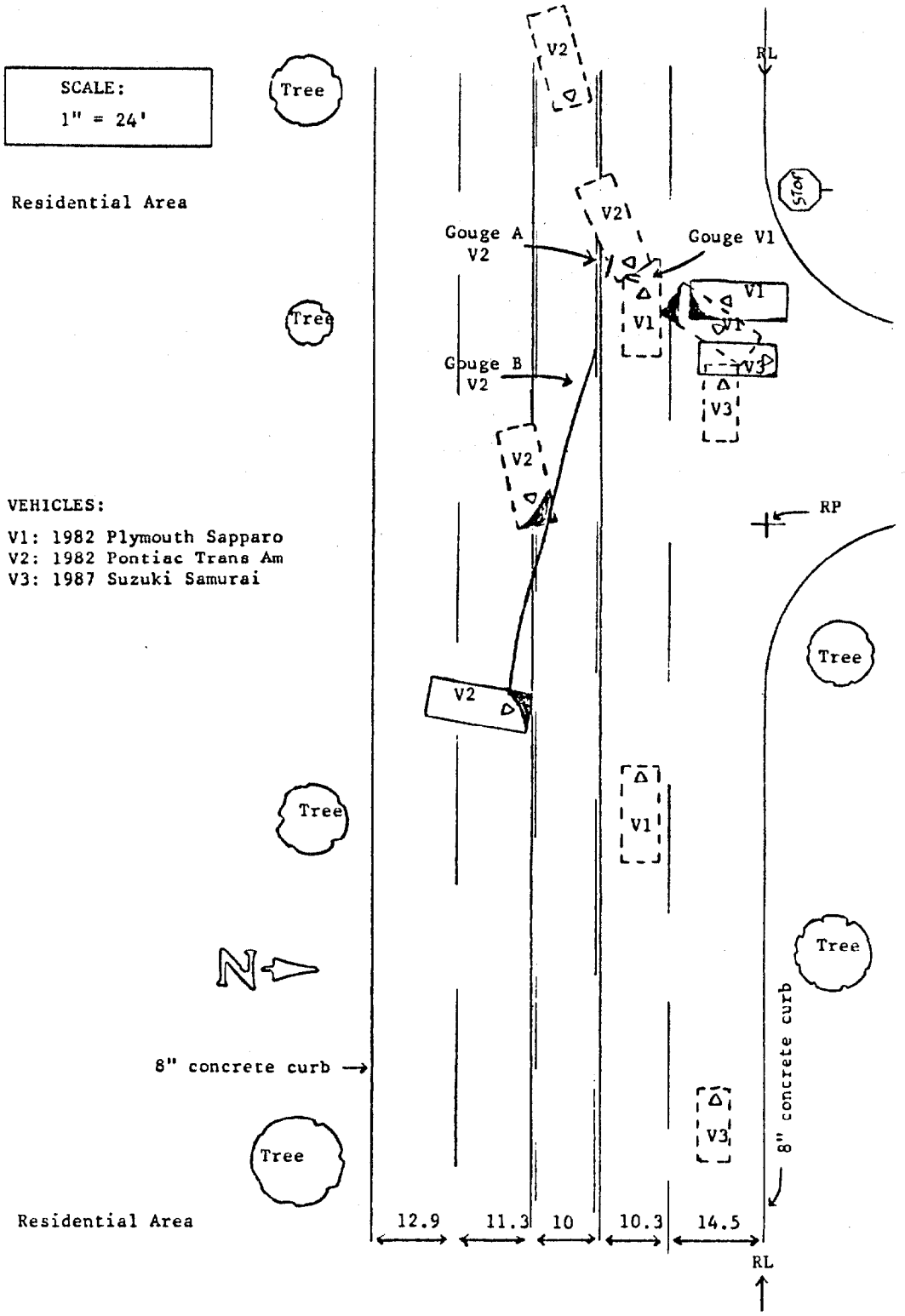

SELECTED PHOTOGRAPHS, CASE 484

1.

Scene. V2 direction of travel. Impact point to left of center turning lane. V2 point of rest to right of center turn lane.

2.



V1 (1982 Plymouth Sapparo). Head-on impact. Max Crush = 53.3 inches. Delta V = 40 - 42 m.p.h. Toe pan intrusion = 16.7 inches.

SELECTED PHOTOGRAPHS, CASE 484

3.



V1 driver's position. Steering hub, (AIS-4 chest). Left door panel (AIS-3 pelvis). Steering column/Roof removed for rescue.

4.

V1 interior. Left A pillar (AIS-5 AIS-3 head), (AIS-2 face). Roof was removed by rescue personnel. Note taped head contact point.

SELECTED PHOTOGRAPHS, CASE 484

5.



V2 (1982 Pontiac Trans Am 2 door). Max Crush = 57.5 inches. Delta V = 40 - 42 m.p.h. Toe pan intrusion 13.1 inches.

6.



V2 interior. Driver's abdomen, chest and head collapsed the steering wheel. Shoe was stuck to accelerator pedal.

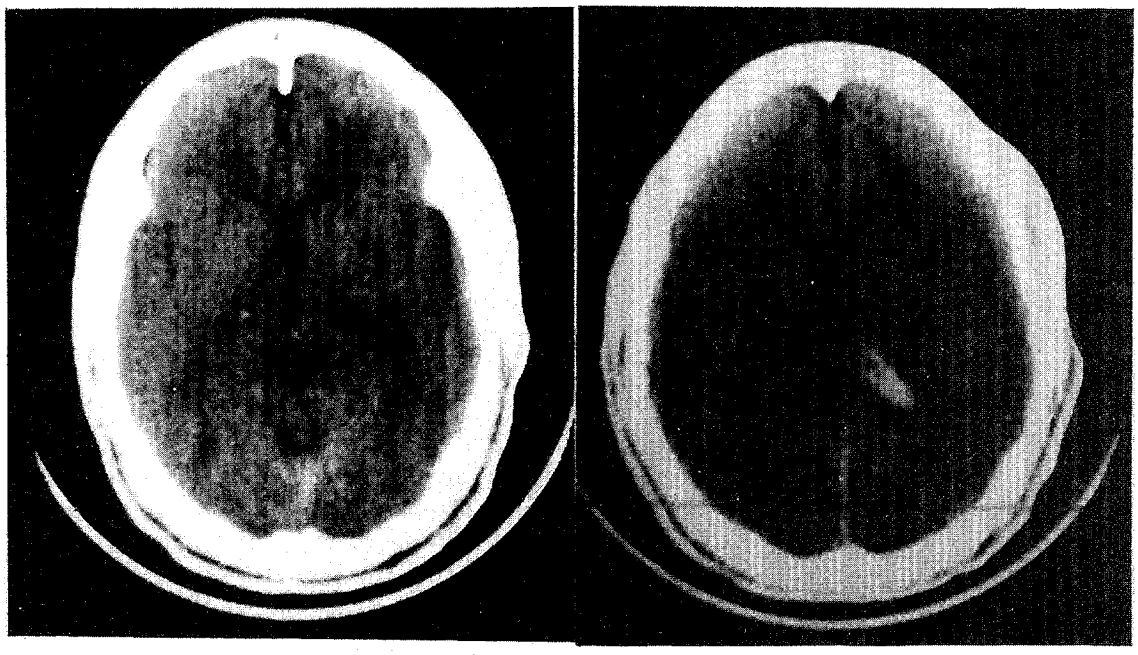

484A Head CT Scans reveals basal ganglia and thalamic hemorrhage with intraventricular hemorrhage.

Contact Point- Left A Pillar
Type of Crash- Frontal impact

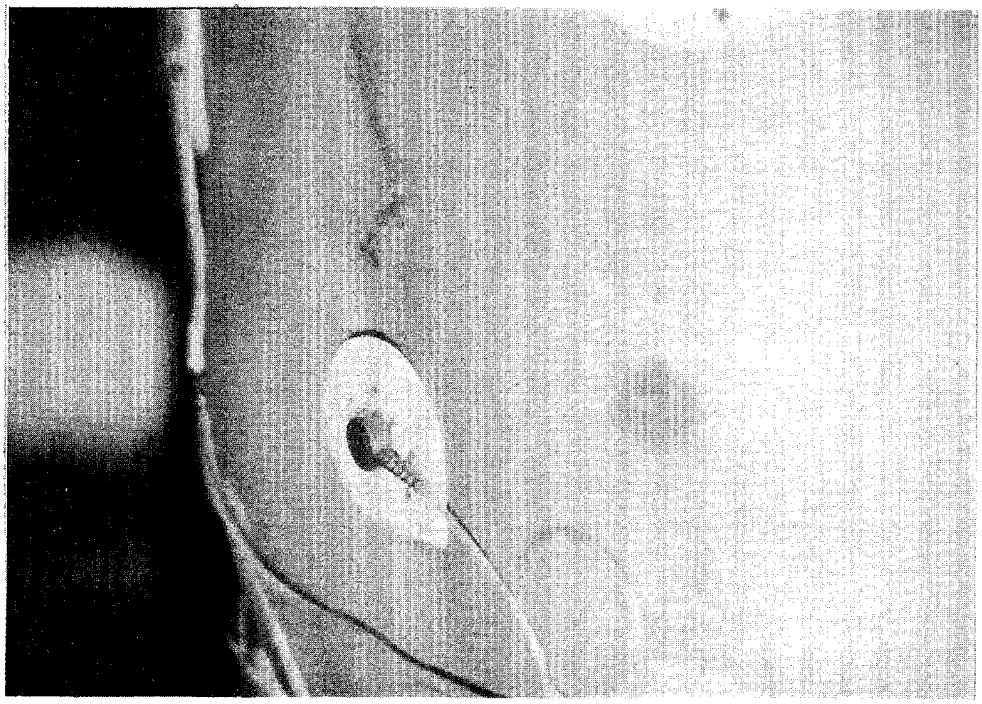

484B Midline epigastric abdominal abrasion.

Contact Point- Left Door Panel
Type of Crash- Frontal impact

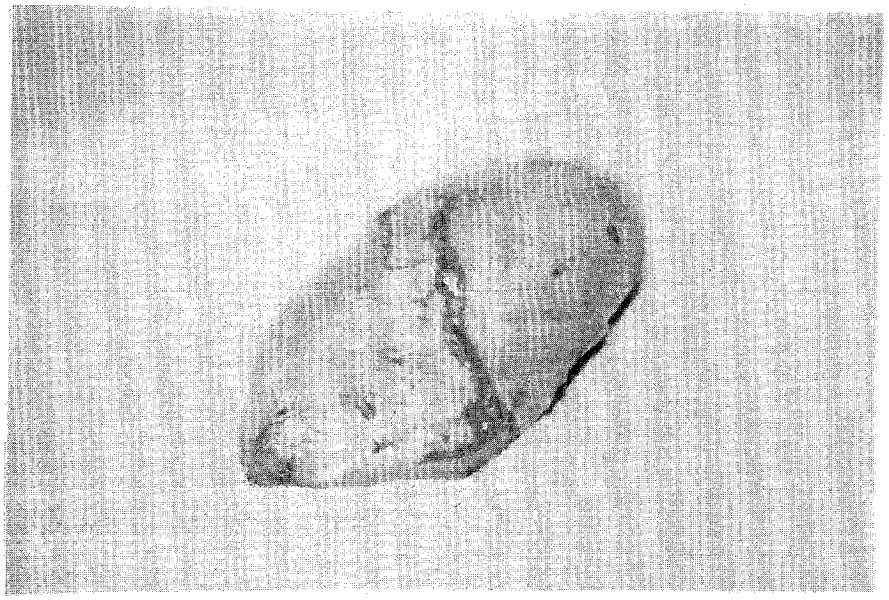

484C Operative photo showing resected spleen with laceration.

Contact Point- Steering wheel
Type of Crash- Frontal impact

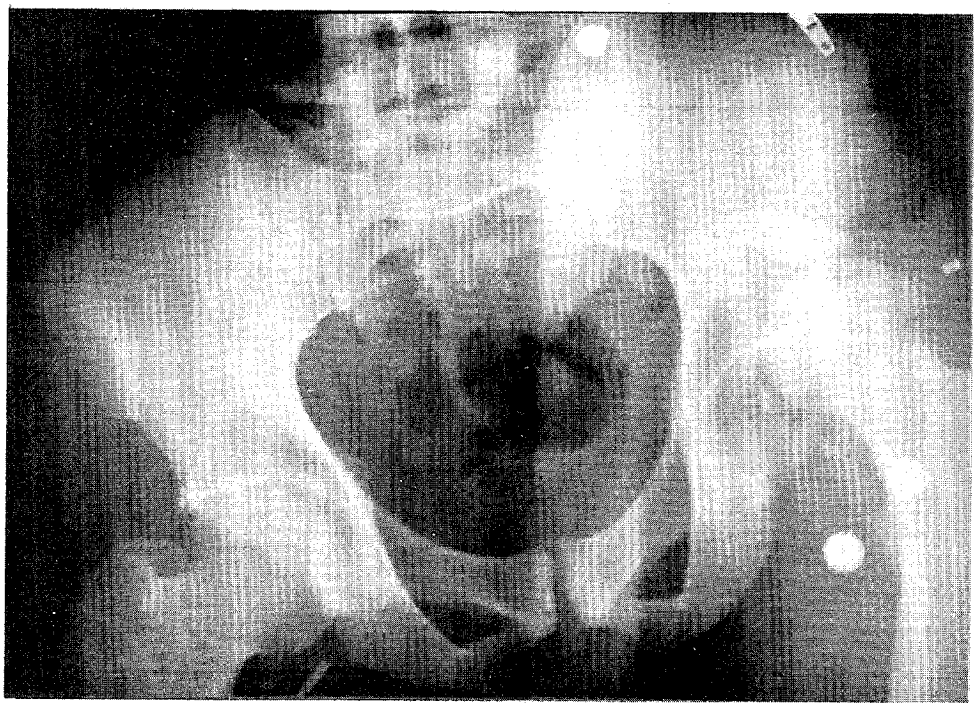

484D Pelvic X-Ray reveals bilateral pubic ramus fracture and left acetabular fracture with dislocation.

Contact Point- Left door panel
Type of Crash- Frontal impact

SUMMARY - CASE 365 (005)

This single vehicle accident occurred during the evening, mid week, in January 1989. It involved a 1987 Chevrolet Camaro Z-28 being driven by a 29 year old male. The driver lost control as he departed a right hand curve at a high rate of speed. The vehicle began a clockwise rotating skid, and struck a curb in a near broadside slide. The vehicle continued over the curb and struck a fire hydrant and a utility pole in the vicinity of the driver's door. The vehicle had started a roll toward the left and struck the utility pole at a point approximately 60 degrees into its first quarter roll. The driver was ejected through the left portion of the " T " top and was projected in front of the vehicle's path. The utility pole fractured at impact, and the vehicle continued rolling through the remaining 3 quarter turns coming to rest on its wheels facing east. The Driver sustained severe incapacitating injuries consisting of a closed head injury, facial lacerations, a left elbow fracture and dislocation a lateral type 1 pelvic fracture, an acetabular fracture, and a ruptured diaphragm. The driver was not using the available lap and shoulder belts at the time of the accident. The vehicle was towed due to damage and was considered a total loss. Injuries sustained by the driver are listed below in OIC format.

BODY CONTACTS AND INJURIES TABLE-CASE 365
29 year old male, driver, 1987 Chevrolet Camaro Z28, side impact

OIC/AIS CODE	ICD-9	INJURY DESCRIPTION	CONTACT POINT
2HLLI1 261111	910.8	Left Scalp Laceration	Left Side Glass/Frame /Side Rail
2HWKB2 261111	854.00	Closed Head Injury	Left Side Glass/Frame /Side Rail
2FLLO1 261111	921.1	Left Eyelid Laceration	Left Side Glass/Frame /Side Rail
2MSRR3 671100	862.0	Ruptured diaphragm	Right Front Tire and Rocker Panel
2MLAI1 842111	911.0	Abdomen Abrasion	Ground ?
2PAFS2 211111	808.43	Left Pelvic Compression Fracture	Left Armrest
2PLFS3 211111	808.00	Left Acetabular FX	Left Armrest
2ELZJ3 979799	812.4	Left Elbow Fracture/ Dislocation	Unknown
No Injury		Deformed Plastic	Left Kick Panel

PSYCHOSOCIAL TIMELINE - CASE 365

Initial Interview

Patient is a 29-year-old male who was the driver and sole occupant involved in a single car accident. Prior to the injury, the patient was employed as a truck dispatcher and is a high school graduate. The patient is the second youngest of three brothers and four sisters. The patient's father is deceased. The patient has been separated from his wife and children, ages 7 and 2, for the past six months. The patient's wife describes the patient as being manipulative with a history of multiple substance abuse (alcohol, marijuana and cocaine). This was reported to have been an issue and the primary reason for separation. The patient had been enrolled in a drug rehabilitation program but signed out prior to completion. The patient expressed frustration by hospitalization and some conflict has been reported by staff regarding pain medication. Intermittent episodes of loud demanding behavior have been exhibited during the acute care stay although the patient has been cooperative when firm limits have been given.

The patient's wife has expressed concern that the collision was the result of a suicidal gesture, however, the patient denies this possibility. The patient also denies any dependency or problem with alcohol or drug use and feels that medication is not indicated. The patient acknowledges drinking beer daily with heavier drinking on the weekends. The patient also admits to occasional marijuana and cocaine usage.

The patient was discharged home at T + 18 days.

CRASH TIME LINE - CASE 365

T - 5.0 to 1.84 Seconds: The driver of Vehicle 1 was approaching a right hand curve at a speed estimated to be between 75 and 80 miles per hour. This 2 lane asphalt paved roadway has an estimated co-efficient of friction of .65. As the vehicle departed the curve and started down a negative 8.3 % grade, traction was lost and the left rear tire began leaving a yaw type skidmark indicating the start of clockwise rotation.

T - 1.67 Seconds: At a point of 20.1 feet farther west, the left front tire also began leaving a yaw skidmark. These tire signatures terminate 159.9 feet further west after impacting a curb, fire hydrant, and utility pole. Velocity was estimated to be 113.5 feet per second at this point.

T - 0.40 Seconds: Vehicle 1 had continued its clockwise rotational skid at a near broadside slide. The left front tire struck and mounted a curb at a point 19.4 feet to a fire hydrant and 32.5 feet to a utility pole.

T - 0.20 Seconds: Vehicle 1 struck a fire hydrant in the vicinity of the driver's door, intruding the driver's area in the vicinity of the driver's seat. The left rear tire struck the curb

slightly further west with a force sufficient to snap the wheel and rim from the axle. The impact of the left front tire at the curb and the loading of the left rear tire changed Vehicle 1's clockwise rotation to counterclockwise rotation, and Vehicle 1 struck the fire hydrant and utility pole at a 90 degree angle.

T - 0: Vehicle 1, in a counterclockwise rotating broadside slide, impacted the utility pole inducing further intrusion into the driver's area. Vehicle 1 had started a rollover to the left as a result of impacts with the curb, fire hydrant and frictional forces. Vehicle 1 had rotated an estimated 45 degrees into the first quarter turn at pole contact. Partial to complete failure had occurred at the "T" top insert on the left side. At impact with the utility pole, the left window glass was shattered and integrity to the left side lost. The driver was ejected forward of the vehicle path of travel, struck the ground and came to rest oriented in a southeasterly direction.

T + 0.6 Seconds: Vehicle 1 struck the ground with the left rear quarter panel 11.3 feet after the pole impact while continuing the rollover configuration in a nose high attitude and came to final rest on its wheels facing northwest at a point 30.3 feet from the pole impact. The driver was found at the right front wheel, slightly under the vehicle. Exterior occupant contacts indicate the vehicle ran over the driver with the right front wheel and lower wheel well/sill sheet metal.

T + 2.00 Minutes: The police were notified.

T + 4.00 Minutes: The police arrived and rescue/investigative procedures started.

PREHOSPITAL AND HOSPITAL TIMELINE - CASE 365

T+ 1min: Ambulance receives call to respond.

T+ 5min: Ambulance arrives at scene. Initial field assessment of the patient reveals a blood pressure of 110/72, heart rate of 60, respiratory rate of 44, and a Glasgow Coma Score of 11. Initial care provided includes the administration of 500cc of crystalloid.

T+ 53min: The patient is evacuated from the scene by police medevac helicopter for MIEMSS/Shock Trauma.

T+ 77min: Patient arrives at MIEMSS/Shock Trauma. Initial physiological assessment of the patient reveals a blood pressure of 123/69, a heart rate of 43, a respiratory rate of 30 and a Glasgow Coma Score of 15. The patient's ISS (Injury Severity Score) = 22. Results of the toxicology screen were positive for alcohol.

T+77min: Initial hospital care provided included the following procedures:

- -Evaluation by a MIEMSS trauma team,
- -Fluid resuscitation,
- -Full diagnostic evaluation including x-rays of the cervical spine, chest and pelvis. In addition to the toxicology

screen, an arterial blood gas, a CBC (complete blood count), an SMA-6 (routine blood chemistry) and a UA (urinalysis) were performed.

-Diagnostic peritoneal lavage (negative).

Injuries noted include the following:

-Parietal scalp laceration (superficial),
-Left forehead laceration (superficial),
-Left eyelid laceration (superficial),
-Left hyphema abrasion/contusion/hematoma,
-Left elbow dislocation (with injury to medial ligament),
-Left hemidiaphragmatic injury (tear),
-Left lateral abdominal and left flank contusion/abrasion/ hematoma,
-Splenic capsule injury,
-Pelvic fracture (Left acetabulum, Grade I compression type with Vertical Shear Injury and Bilateral Pubic Ramus Fracture),
-Left Anterior Sacroiliac widening
-Left Anterior sacral fracture with displacement.

Operative care included:

-Repair of Left hemidiaphragm

No complications were reported for this patient during the acute care phase.

T+24hours- 18days: Patient remains in intensive care for ten days and intermediate care for 8 days.

T+18days: Patient discharged to home.

COGNITIVE-COMMUNICATIVE NARRATIVE - CASE 365

The patient's cognitive-communicative abilities were initially evaluated on T + 8 days. The patient was noted to have adequate auditory comprehension, written comprehension, oral expression, speech and cognitive skills. The patient's written expressive skills were reduced. The patient was felt to be functioning at an RLAS VIII-Purposeful/Appropriate level (Rancho Los Amigos Score.) No speech-language pathology intervention was recommended, however, a psycho-educational evaluation was recommended. The patient passed a hearing screening and swallowing was within normal limits. No follow-up is indicated for this patient.

CRASH COMPARISON
CASE # 365

Overview

The following table contains data that was extracted from the NHTSA vehicle database, based on vehicle make, vehicle model, body type, production year, weight, and general physical measurements. The center of gravity, speed and vehicle # have

also been included. A system of data retrieval using INGRES "views" and report formats has made the extraction of general preliminary data much easier, and less time consuming than in previous retrievals. This type of query eliminates the need to perform redundant retrieval processes.
Although a query of this type is useful for gathering basic data, a more detailed query for selected cases chosen from this table is constructed per individual case, to include all possible cases that may contain useful information. For example it may be necessary to search for a list of all vehicles that fall within a certain weight range (say +/- 500 lbs.) or traveling within a given range of speed (say +/- 15 mph). In this example, finer case-specific data is retrieved.

After these searches, for cases that are deemed "close matches", an exhaustive report (15-20 pages long) including instrumentation specifics are generated, and used as necessary for the reconstruction.

22-MAY-1989 16:10:05

CHEVROLET CAMARO
Report on Table: VEW000A

Mak	Mod	Bod	T#	YR	LBS.	Length	Width	COG	Wbase	Speed	V#	Crush
01	08	2C	450	82	3428	187.50	72.00	53.20	101.00	35.40	1	25.60
			38	79	3980	197.80	74.50	50.20	108.10	35.00	2	10.80
		3H	994	87	3524	188.00	72.00	50.20	100.80	35.20	1	25.30
			499	82	2895	189.00	74.30	45.90	101.00	29.30	1	18.00

PSYCHOSOCIAL FOLLOW-UP - CASE 365

6 Months

Patient discharged home with girlfriend 17 days post-trauma with home physical therapy for gait training. Patient continued to abuse drugs/ETOH post discharge.Six weeks after discharge, patient involved in fight at bar and pushed through plate glass window and bled to death.

CRASH AND INJURY PREVENTION IDEAS - CASE 365

This accident occurred as a result of excessive speed. Downsizing car engines or otherwise controlling speed such as electronic sensing units within city limits would have reduced the 75-80 miles per hour speed by at least half. The driver, properly restrained by an automatic restraint system, would have

been kept inside the vehicle, rather than being ejected and run over by his own vehicle. With a side impact air cushion restraint system, the severity of his injuries sustained during the impacts with a fire hydrant and telephone pole, would have been less.

PREVENTION COMMENTS - CASE 365

This patient is a 28-year-old male who had a positive toxicology screen for alcohol. He was proceeding at an excessive rate of speed and lost control on a right curve, struck a fire hydrant pole and was ejected through the T-top of his Z-28 Camaro. He sustained a mild head injury, a pelvic compression fracture, a left acetabular fracture (probably from the arm rest), and a ruptured diaphragm from being extruded through the T-top and/or possibly from being run over by the car after ejection. One of the major issues here is, of course, the issue of alcoholism. It is of interest in this patient that he was subsequently killed in an altercation within three months of the injuries he sustained in this accident. The patient was clinically addicted to alcohol and it appeared to produce aggressive behavior. A breath analyzer ignition lock would have prevented him from driving when impaired by alcohol.

As far as the car is concerned, the T-top would appear to be a rather poor, unsafe design allowing for ejection. Although the driver was not wearing a seatbelt, the T-top allowed him to be ejected with considerable force. The photographs show extensive deformation to the door panel, demonstrating the lack of lateral protection which undoubtedly contributed to the left sided pelvic fractures. The arm rest was a contributing factor and probably should be eliminated. The T-top probably should be viewed as an inherently unsafe design, even though the fact that this patient was not wearing a seatbelt certainly contributed to his extrusion from the car.

The pre-hospital times for transport were appropriate as was the treatment both in the field and at the hospital.

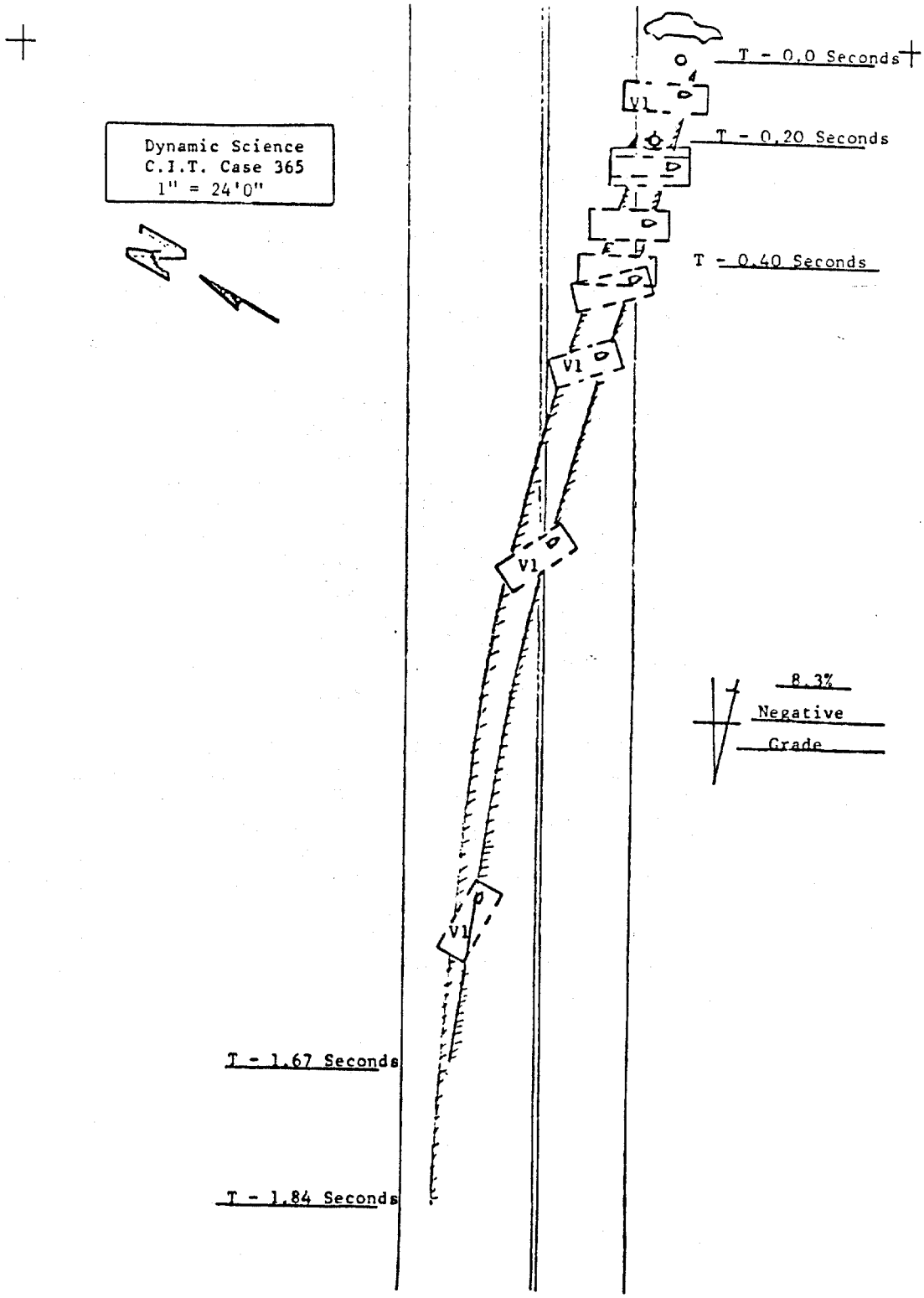
Dynamic Science
C.I.T. Case 365
1" = 24'0"
T - 0.0 Seconds
T - 0.20 Seconds
T - 0.40 Seconds
V1
V1
V1
V1
8.3%
Negative
Grade
T - 1.67 Seconds
T - 1.84 Seconds

Dynamic Science
C.I.T. Case 365
1" = 24'0"

NOTES

Ref.#1, L/QTR
V1 GRD. POS

Ref. #2 FRP FIRE
HYDRANT

Ref. #3 FRP V1
HOOD

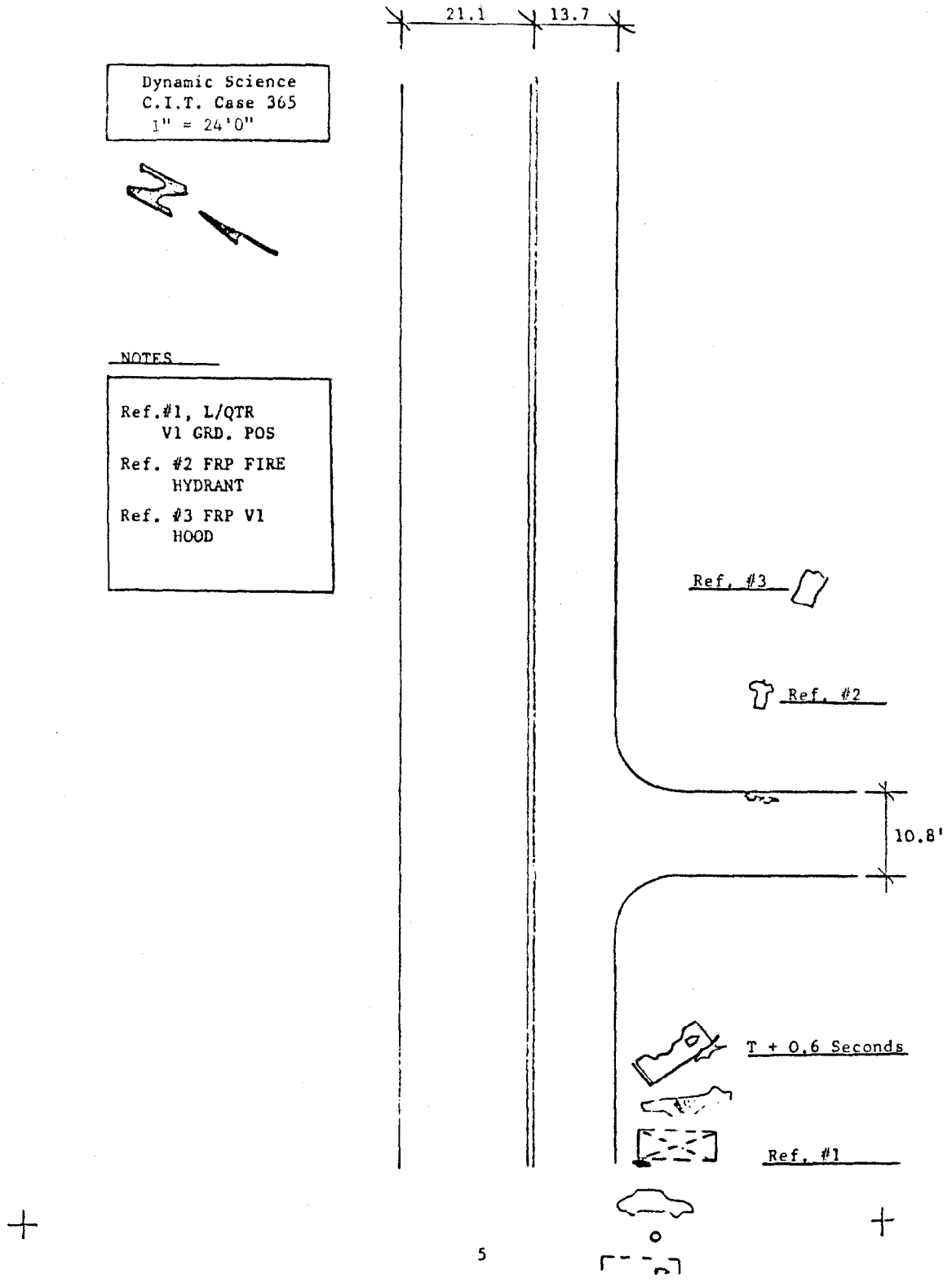

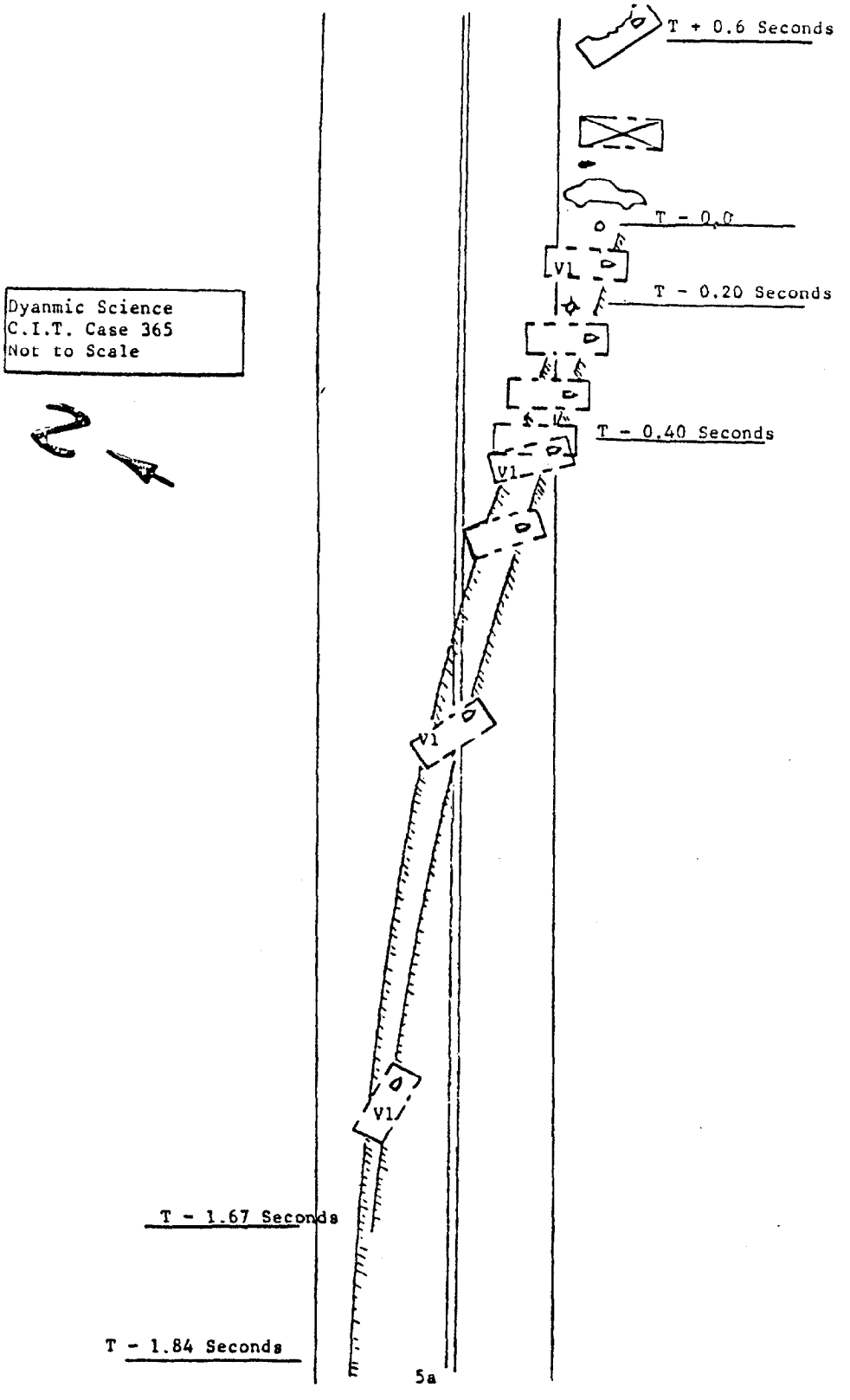
T + 0.6 Seconds
T - 0.0
T - 0.20 Seconds
T - 0.40 Seconds
T - 1.67 Seconds
T - 1.84 Seconds
Dyanmic Science
C.I.T. Case 365
Not to Scale
V1
V1
V1
V1
5a

SELECTED PHOTOGRAPHS, CASE 365

1.

Scene photograph showing Vehicle 1's direction of travel; single vehicle collision w/multiple fixed objects. Note: skid marks toward right curb and pole.

2.



After impact #1 with curb (nearly broadside), vehicle 1 struck utility pole (impact #2) in vicinity of driver's door.

SELECTED PHOTOGRAPHS, CASE 365

365-23

3.



V1; (1987 Chevrolet Camaro Z28); Max crush - 16.5 inches. Intrusion at left front "A" pillar - 12.1 inches.

365-31

4.



Driver sustained closed head injury (AIS-2) when contacted with L/side glass/frame/side rail; ruptured diaphram & L/acetabular fracture (AIS-3), L/arm rest; and other less severe injuries.

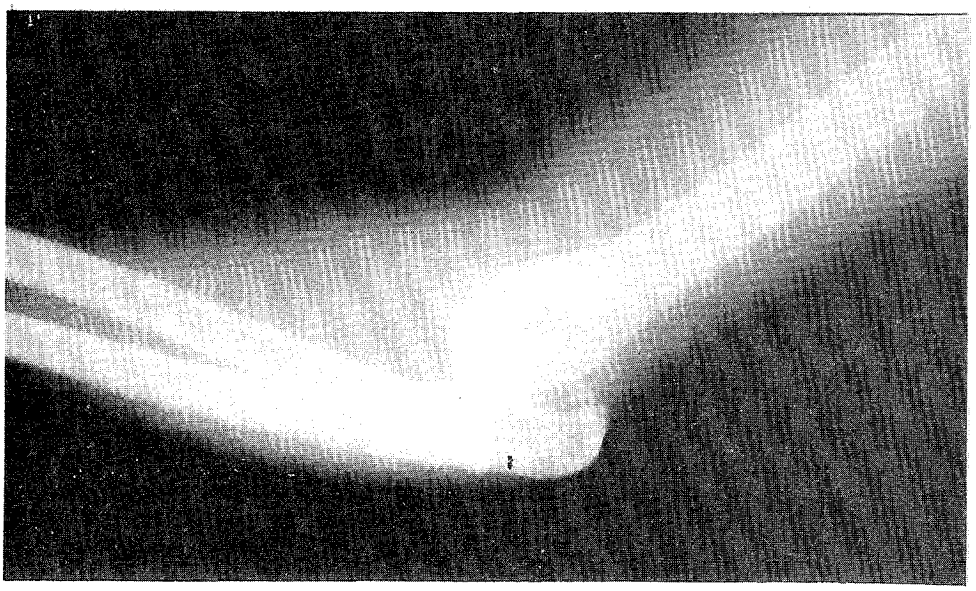

365A X-Ray revealing fracture dislocation of the left elbow.

Contact Point- Unknown
Type of Crash- Left lateral impact with occupant ejection

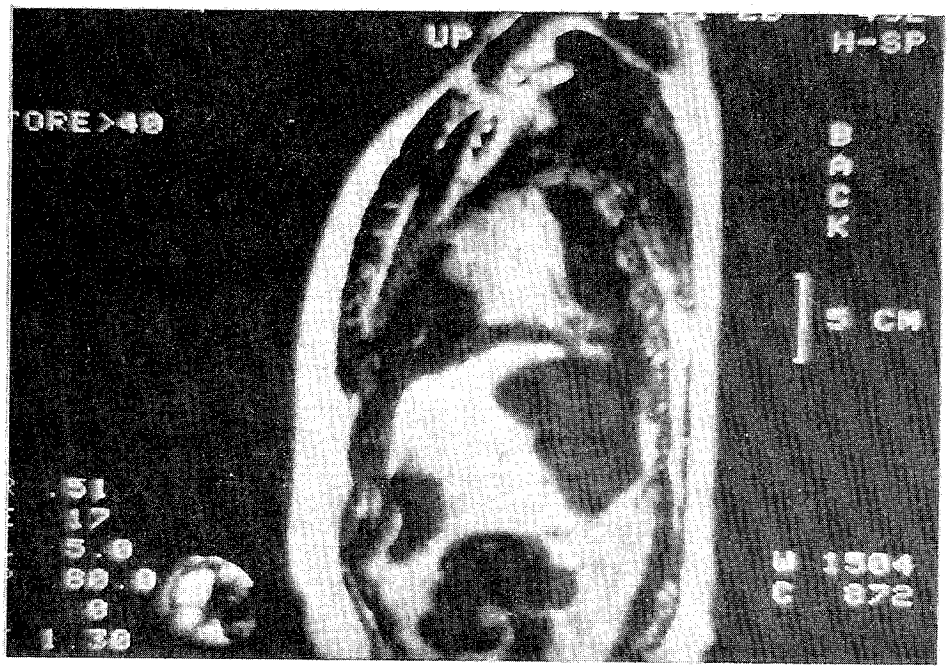

365B Magnetic Resonance Imaging (MRI) scan revealing ruptured diaphragm with displacement of mesenteric omentum into chest.

Contact Point- Right Front Tire and Rocker Panel
Type of Crash- Left lateral impact with occupant ejection

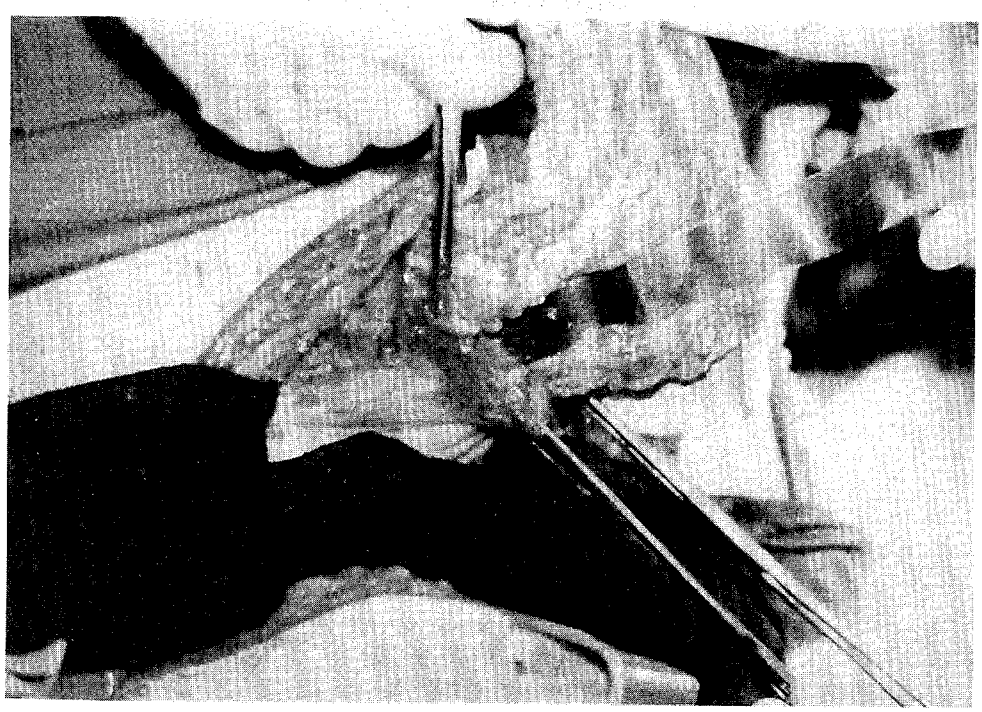

365C Operative photo revealing ruptured diaphragm as viewed from a thoracic incision. Omentum is seen to be herniating into the thoracic cavity.

Contact Point- Right front tire and rocker panel
Type of Crash- Left Lateral Impact with occupant ejection



365D Pelvic X-Ray revealing left acetabular fracture.

Contact Point- Left armrest
Type of Crash- Left lateral impact with occupant ejection

SUMMARY - CASE 368 (006)

This accident occurred during the daylight hours of mid-winter. It involved a 1979 Lincoln Versailles being driven by a 45 year old female and a 1984 Buick Riviera being driven by a 31 year old female who had a 3 year old passenger. A second impact occurred between the 1979 Lincoln and a third vehicle, a 1981 Mazda 626 being driven by a 31 year old male. The driver of Vehicle 1 was eastbound on a 6 lane asphalt paved road at a speed estimated to be between 35 and 45 miles per hour. Vehicle 2 was westbound on the same road at a speed estimated at 45 to 50 miles per hour. Vehicle 3 was behind Vehicle 1, also eastbound. The driver of Vehicle 2 allowed the vehicle to cross the center lines and impacted Vehicle 1 frontal plane to frontal plane. At impact #1 Vehicle 1 sustained a maximum crush of 30.5 inches and slid rearward an estimated distance of 10 feet. Vehicle 3 struck Vehicle 1 frontal plane to back plane at an undetermined time during the accident sequence. Vehicle 2 sustained 48.25 inches of maximum crush, rotated 50 degrees counterclockwise and slid 7.5 feet to final rest. During impact number 2, Vehicle 1 sustained a maximum crush of 12.2 inches to the back plane and Vehicle 3 sustained 16.0 inches of maximum crush measured at the hood line. Damage flow from Vehicle 1 and Vehicle 2 indicated an underride impact. The case, the driver of Vehicle 1, was not wearing the available lap/shoulder belts and received severe incapacitating injuries. She was transported and admitted to a shock trauma unit. The driver of Vehicle 2 was not wearing the available lap/shoulder belts and received severe incapacitating injuries. Her 3 year old passenger was not listed as injured. The driver was transported to a local hospital and admitted. The driver of Vehicle 3 was not wearing the available lap/shoulder belts and sustained incapacitating injuries. Transport and treatment data for this driver is unknown. Neither Vehicle 1, Vehicle 2, nor Vehicle 3 were equipped with air bags and all were towed due to damage. Injuries sustained by the case, the driver of V1, are listed below in OIC format:

BODY CONTACTS AND INJURIES TABLE-CASE 368
45 year old female, driver, 1979 Lincoln Versailles, frontal impact

OIC/AIS CODE	ICD-9	CONTACTS OR INJURIES	CONTACT POINT
1.2MRLL5 061111	864.04	Major Liver Lacerat.	Steering Column
2.2CRFS3 041111	807.09	FX. Right Ribs (5-8)	Steering Rim/Hub
3.2TLFS3 042111	821.01	FX. Left Femur	Steering Wheel Rim?
4.2KRFS2 091111	822.0	FX. Right Patella	L/Inst. Panel
5.2KLFS2 091111	822.0	FX. Left Patella	L/Inst. Panel
6.2LRFS2 091111	823.32	FX. Right Tibia	L/Inst. Panel
7.2LRFS2 091111	823.32	FX. Right Tibia	L/Inst. Panel
8.2LLFS2 091111	823.21	FX. Left Fibula	L/Inst. Panel
9.2LRFS2 091111	823.32	FX. Right Fibula	L/Inst. Panel
NO INJURY		Hair Deposits	Roof/Left A

Pillar
Junction

PSYCHOSOCIAL TIMELINE - CASE 368

Initial Interview

Patient is a 45-year-old divorced female who sustained multiple internal injuries following an MVA while enroute to work. The patient was the driver and sole occupant of her vehicle.

The patient is an elementary school teacher and has been employed by a municipal school district for 24 years. Divorced with no children, the patient is currently living alone and provides total self support. Family consists primarily of cousins and a boyfriend. The patient's large support network is made up of friends and colleagues. The patient's mother, with whom she had previously lived and had a close relationship, died within the past year (T - 1 year). Relatives indicated that the patient was depressed over the Christmas holidays (T - 2 months) due to this loss.

A cousin, the primary spokesperson, describes the patient as a, "bubbly, energetic person, very loving and willing to do for others." The patient was very interested in her school children and active in educational organizations. The patient is described as one who verbalizes her feelings easily and stays in frequent contact with relatives and peer group. Patient enjoys artistic endeavors such as ceramics and flower arrangement.

The patient is a smoker and uses alcohol occasionally at social gatherings. No history of drug use known to spokesperson. The patient has used food (snacking) as a way to cope when anxious. Patient unable to contribute to initial interview due to her medical status.

The patient expired at T + 27 days.

PREHOSPITAL AND HOSPITAL TIMELINE - CASE 368

T+ 3 min: Ambulance receives call to respond.

T+ 9 min: Ambulance arrives at scene. Initial field assessment reveals blood pressure of 100/60, heart rate of 100, respiratory rate of 16, and a Glasgow Coma Score of 14. Prehospital care includes full spinal immobilization.

T+ 30min: Patient departs scene for MIEMSS/Shock Trauma by paramedic staffed ground ambulance.

T+ 51min: Patient arrives at MIEMSS/Shock Trauma. Initial physiological assessment of the patient reveals a blood pressure of 61/41, a heart rate of 120, a respiratory rate of 17 and a Glasgow Coma Score of 15. The patient's ISS (Injury Severity Score) = 29. Results of the toxicology screen were negative. Initial treatment provided included the following procedures:

-Evaluation by a MIEMSS trauma team,
-Fluid resuscitation,
-Full diagnostic evaluation including x-rays of the cervical

spine, chest and pelvis. In addition to the toxicology screen, an arterial blood gas, a CBC (complete blood count), an SMA-6 (routine blood chemistry) and a UA (urinalysis) were performed.

-Diagnostic peritoneal lavage (grossly positive),

Injuries noted to include:

-Fractured Ribs (Right Side) Nos. 5 - 8,
-Laceration of Right Lateral Liver Lobe with major tissue destruction,
-Hemoperitoneum due to Liver Injury (>1000cc blood),
-Fracture of Left Femur (Transverse, Middle 1/3),
-Bilateral Patellar Fractures (Transverse)
-Fracture of Right Tibia (Comminuted, Middle 1/3, Open),
-Fracture of Right Tibia (Oblique, Distal Articular Surface),
-Fracture of Right Fibula (Transverse, Lower 1/3. Open),
-Fracture of Right Fibula (Transverse, Head),
-Fracture of Left Fibula (Transverse, Middle 1/3)
-Fracture of Left Tibia (Transverse, Middle 1/3).

Operative care includes:

-Resection of liver injury,
-Intermedullary Rod placement in left femur,
-External fixation of right tibia and fibula,
-Traction on left fibula and tibia,
-Traction and casting of left patella.

T+ 24hours-27days: Patient remains in critical care throughout stay and develops Adult Respiratory Distress Syndrome (bilateral uniform), renal failure and pneumonia on Day 3. On Day 7, patient develops septic complications from a pulmonary source.

T+ 27DAYS: Patient expires.

CRASH COMPARISON
CASE # 368

Overview

The following table contains data that was extracted from the first pass on the NHTSA vehicle database. It is framed from vehicle make, vehicle model, body type, production year, weight, and general physical measurements. The center of gravity, speed and vehicle # have also been included.

Table 368-1
LINCOLN CONTINENTAL

MAK	MOD	BOD	T#	YR	LBS.	LENGTH	WIDTH	COG	WBASE	SPEED	V#	CRUSH
13	01	4S	528	82	4158	201.2	72.2	50.7	109.5	34.7	1	26.9
			204	79	5362	232.5	79.9	60.8	127.2	35.1	1	30.8

While this retrieval showed the proper vehicle make, the

configuration as to weight and general size did not match up well and there were no vehicle motion curves for the tests. As a result, the search was broadened to include other types of vehicles of a size closer to the Lincoln Versailles and with the right combination of speed and weight. Several showed up (Cases 581,282,812, and 866).
Comparison of the Crash Test Curves:

Instrumentation curves for the vehicles drawn from the test data base were not very good. There was a lot of oscillation in them and the accelerometer pulses had to be estimated from an averaging process with periods less than 5 msecs averaged out. The curves obtained are at Figures 368-1 through 4. They are taken from the rear axle, rear deck and dash panel because there was a lack of COG data in these tests. Of these tests, the Celebrity and the Accord looked most promising in the view of the simulation engineer (closing speed closest).

Comparison of Injuries:

The driver occupant of the crash test # 812 was restrained with a 3point belt and received an HIC of 667 and a CSI of 245. The driver occupant of case 866 was also restrained and received an HIC of 499 and a CSI of 193. In both cases the primary injury causing device was the steering wheel. Obviously the restaraint system kept these injuries from being as severe as those in the actual crash. The absence of a restraint was almost certainly the cause of the liver injury being as severe as it was.

Significance of the case:

This is a rather unusual case as there was a fatality involved and the statistics seem to suggest that it shouldn't have been a fatal accident. Only 10% of fatal accidents involve women 45 or older. Four door sedans are fourth in the number of fatalities produced (19%). Further, only 1% of cases of an urban crash at 55mph or greater result in an AIS greater than or equal to 3. Only 1% are drivers injured at AIS >= 3.

The common features of the accident are that 65% of crashes are on straight and level roads and 55% are collisions with other vehicles. 39% of all vehicle occupants are unrestrained but of these, only 1% are injured as seriously as this case. The fact that the steering wheel was the primary cause of injury is not at all unusual. At 16% it is the most frequent cause of serious injury when it occurs.

The main points seem to be that this accident, while a rather common type of accident under usual conditions, produced serious injuries that exceed the norm. This appears to be due to the lack of restraints in use. 70% of all fatalities to drivers are due in part to lack of use of restraints. In this case it

seems to be the combination of a lack of restraint with the somewhat off-of-center point of impact that threw the occupant upward and to the left, causing the rather serious lacerations to the liver and rib fractures apparently caused by contact with the steering column.

PSYCHOSOCIAL FOLLOW-UP - CASE 368

6 Months

Patient expired in acute care 27 days post-trauma due to injuries received in car crash. No follow-up.

CRASH AND INJURY PREVENTION IDEAS - CASE 368

This accident occurred as a result of driver distractions or inattention. Drivers need constant reinforcement concerning safe driving programs. The use of these programs at license renewal time, mandatory in nature, could make the driver more aware of defensive driver tactics and the need to stay alert. An unrestrained child may have distracted the driver who allowed her car to cross the center line. As in most of our frontal impact cases, the installation of an air cushion restraint system and automatic seat belts would have reduced the driver's injury severity.

PREVENTION COMMENTS - CASE 368

This accident involved a near-frontal impact with the patient eventually succumbing from massive liver injuries resulting from impact with the steering wheel. These injuries would clearly have been prevented through the use of an airbag and a two or three point safety restraint. Additional factors involved in causing the accident include the possibility that the causative vehicle strayed from its lane because the driver was distracted by a child who was unrestrained and moving about the vehicle. This clearly could have been prevented by a properly restrained child in a child seat.

The pre-hospital time was slightly prolonged given that the event occurred in the city and that the victim was clearly a load-and-go type trauma patient. The total body shock insult to the patient may also have been reduced if there had been an early use of a rapid infusion system during the acute resuscitation and liver surgery which occurred within the first 24 hours.

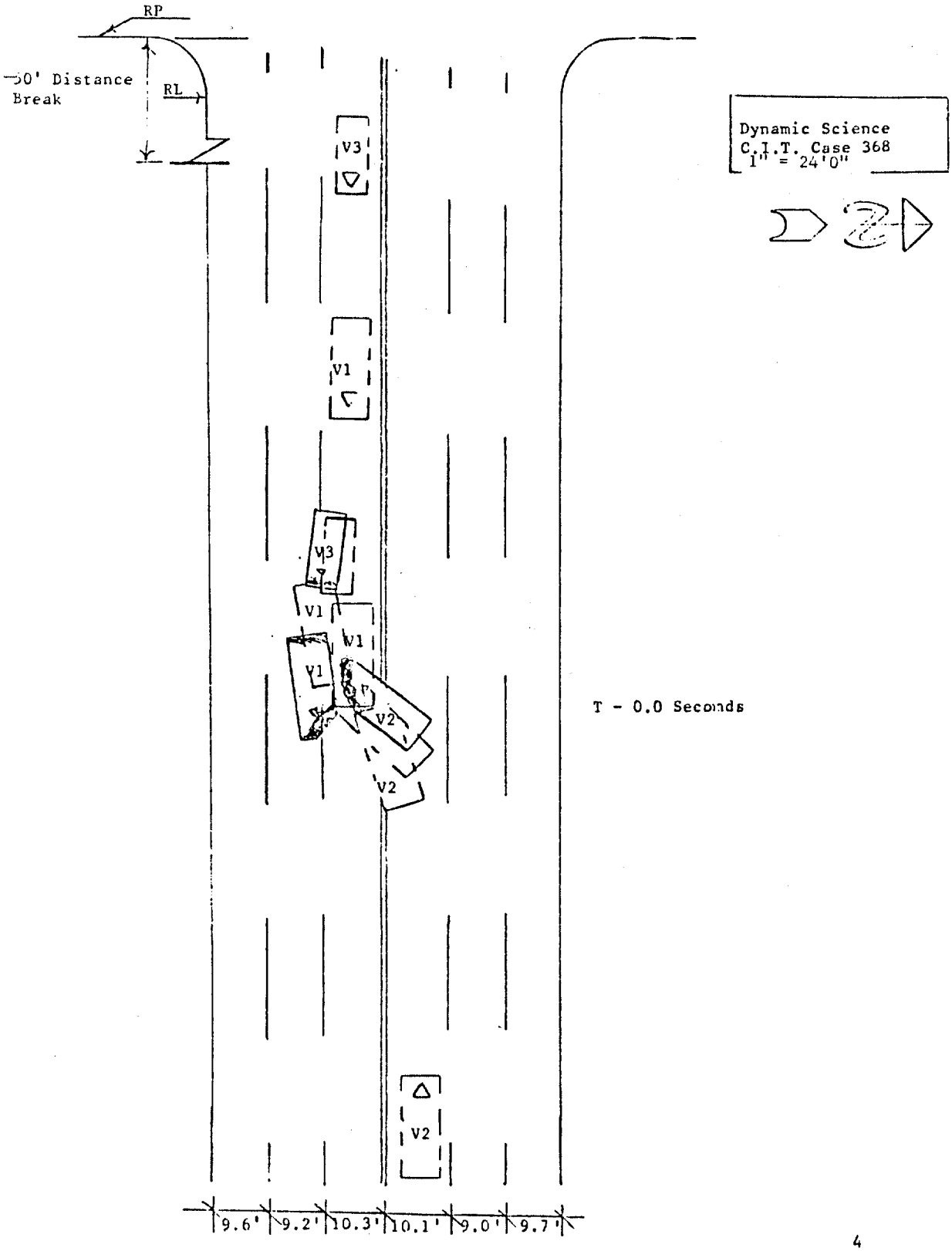
RP
50' Distance
Break
RL
V3
V1
V3
V1
V1
V1
V2
V2
V2
Dynamic Science
C.I.T. Case 368
1" = 24'0"
T - 0.0 Seconds
9.6'
9.2'
10.3'
10.1'
9.0'
9.7'

SELECTED PHOTOGRAPHS, CASE 368

368-01

1.

Scene photograph showing Vehicle 1's and Vehicle 2's direction of travel.

368-16

2.



V1; (1979 Lincoln Versailles). Impact #1-frontal w/V2-Max Crush-30.5". Intrusion of 8.1"-left front. Delta-V 26-30 m.p.h. Impact #2-V3 front to V1 rear plane. V1 max crush-12.2"-rear plane.

SELECTED PHOTOGRAPHS, CASE 368

3.



Driver contact points include steering wheel contributing to major liver lacerations (AIS-5); steering wheel rim, fracture, femur; L instrument panel, FX. R/L patellas, fibulas, tibias.

4.

V2; (1984 Buick Riviera). Max Crush - 48.25" at left front bumper. Intrusion at toe pan = 9.7".

SELECTED PHOTOGRAPHS, CASE 368

368-31

5.



Intrusion of toe pan and impact forces caused the driver to contact head with left instrument panel; chest with steering wheel; and hands and knees with steering column and left instrument panel.

SELECTED PHOTOGRAPHS, CASE 368

6.



V3; (1982 Mazda 626; Max crush - 20.5 inches at hood line caused by impact #2. V3's frontal plane contacted V1's rear plane. No intrusion.

7.



Driver contacted windshield with head and fist; steering wheel with chest; and instrument panel with L/R knees and arms.

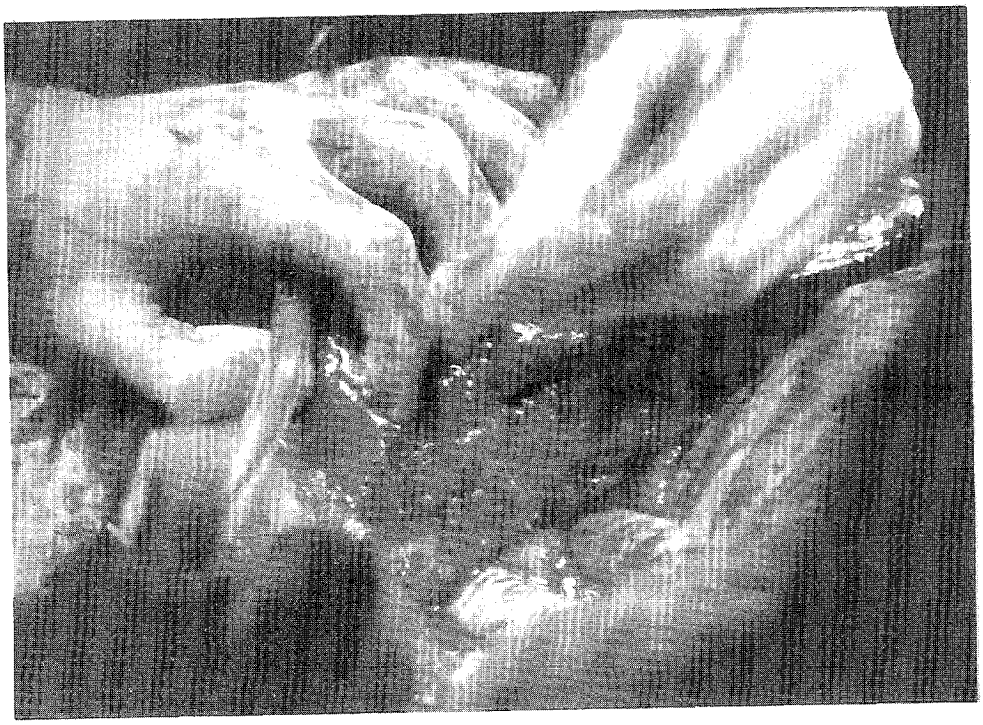

368A Operative photo revealing major right lobe liver laceration.

Contact Point- Steering column and wheel
Type of Crash- Frontal impact
Estimated Force of Mid-torso impact- 100 lbs.

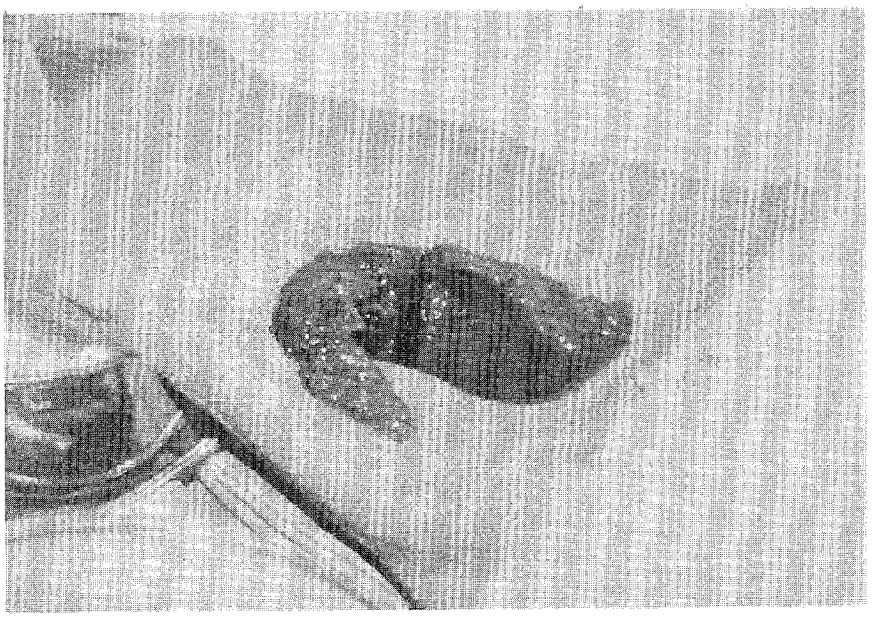

368B Operative photo showing resected left lateral lobe of liver.

Contact Point- Steering column and wheel
Type of Crash- Frontal impact

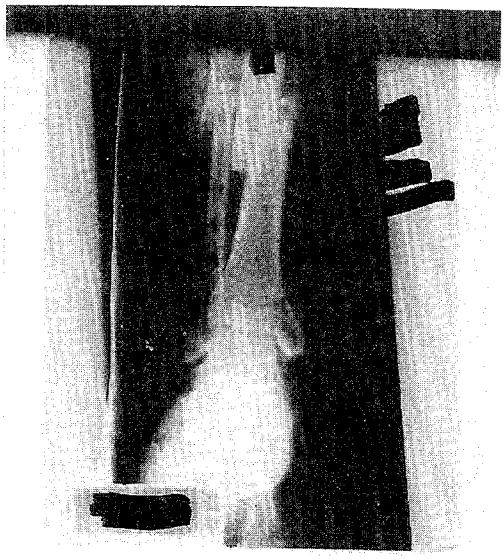

368C X-Ray revealing splinted transverse fractures of the distal 1/3 right tibia and fibula.

Contact Point- Lower instrument panel
Type of Crash- Frontal impact
Estimated Force of Impact- 550 lbs.

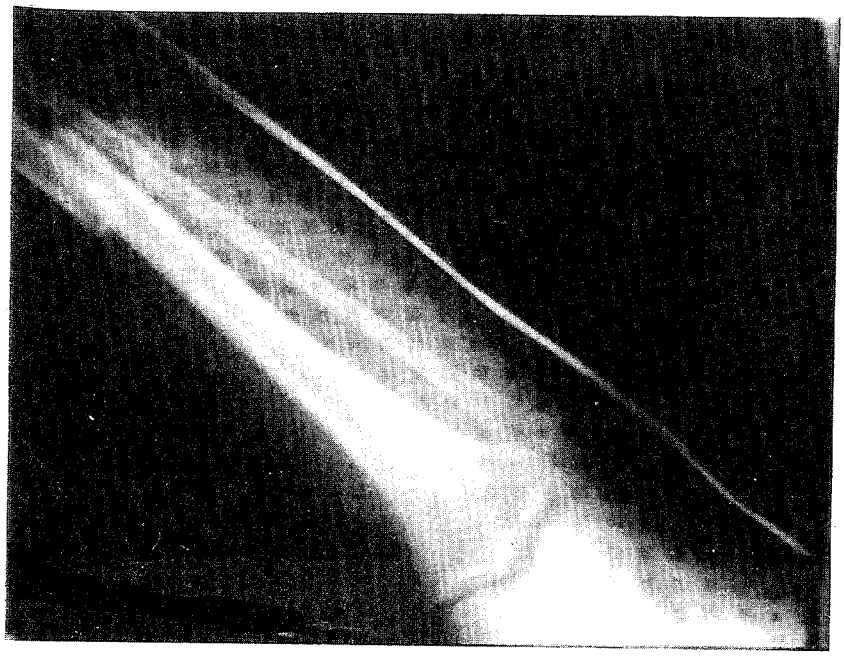

368D X-Ray revealing transverse fractures of the distal 1/3 left tibia and fibula.

Contact Point- Lower instrument panel
Type of Crash- Frontal impact
Estimated Force of Impact- 1070 lbs.

SUMMARY - CASE 418 (007)

This single vehicle accident occurred on a clear, winter, weekday night. The collision involved a 1987 Chevrolet Celebrity 4 door sedan with a 38 year old male driver and a 19 year old male right front passenger. The vehicle (V1) was westbound on a winding 2 lane asphalt road in wooded hill country. V1 topped a hill and decended into a sharp left-hand turn at an estimated speed of 50 to 58 miles per hour. The vehicle moved onto the right shoulder and struck a 3.5 inch mailbox post head-on. V1 then traveled an additional 6 feet westward before impacting a 24 inch diameter tree head-on. There was no evidence of any skidding or yawing before impact and no evidence of significant rebound or rotation after impact. The right front passenger was wearing the available lap and shoulder belt and was critically injured. He was transported to a trauma hospital for treatment. The driver, our case index, was not using the available lap and shoulder belt and was seriously injured. Injuries sustained by this case are listed below in OIC format.

BODY CONTACTS AND INJURIES TABLE-CASE 418
38 year old male, driver, 1987 Chevrolet Celebrity, frontal impact

	OIC/AIS CODE	ICD-9	CONTACTS OR INJURIES	CONTACT POINT
1.	2HWKB2 042106	854.0	Closed Head Trauma	Steering Rim
2.	2FULI1 091104	873.59	Facial Lacerations	Left Inst. Panel
3.	2FUAI1 091104	873.49	Facial Abrasions	Left Inst. Panel
4.	2SLFS2 042106	810.00	Clavicular Fracture	Steering Rim
5.	2RLFS2 092104	813.44	Left Ulna Fracture	Left Inst. Panel
6.	2RLFS2 092104	813.44	Left Radius Fracture	Left Inst. Panel
7.	2PRFS2 041106	808.41	Right Iliac Wing FX	Steering Rim
8.	2WLFS2 092104	815.00	Metacarpal Fracture	Left Inst. Panel
9.	2WLFS1 092104	816.01	Proximal Phalanx FX	Left Inst. Panel
10.	2TRFS3 091104	821.00	Right Femur Fracture	Left Inst. Panel

PSYCHOSOCIAL TIMELINE - CASE 418

Initial Interview

The patient was transported to MIEMSS Shock Trauma with extremity injuries sustained as the unseatbelted driver of a rented vehicle. Case 169 was a passenger in this vehicle, sustained major head trauma and was also admitted to MIEMSS

Shock Trauma. The two friends were returning from an area where the passenger was said to have had a play rehearsal. Two half-full six-packs of beer were found in the car. The driver, patient 418, had requested that the passenger remove the beer from his home due to his own status as a recovering alcoholic. The family was unsure of the details.

The patient is a divorced male with no children, married for the second time to a woman he had known for 1 year and had lived with for the past 4 months. The patient's father is deceased and past relationship with mother and older brother are described as distant. Relationship with younger brother re-established following the patient's recent enrollment (1.5 months ago) in a drug and alcohol treatment program. The brother had successfully completed similar program. The patient's wife exhibits a clear understanding of drinking behavior and family role based on her childhood experiences (e.g. living with an alcoholic mother, attending Al-Anon meetings and psychotherapy.)

The patient had been suspended from high school and later quit due to drug problems but was able to obtain his GED (General Equivalency Diploma) and completed two years of college following discharge from the Army. The patient served in the Vietnam War, escaping without physical injury but according to his wife, this was the most traumatic event experienced by the patient until this motor vehicle accident.

The patient had been employed as a cable lineman with a new company after having worked for the State. The patient was not yet eligible for health insurance coverage and is currently not receiving any salary or disability pay. The wife does not work and the family has applied for food stamps, medical assistance, and income maintenance through Social Services.

The wife descibes the patient as a demanding man who was unable to express feelings or discuss problems. AA meetings and rehabilitation counseling has since helped him to talk out concerns and religion has played a key role in his coping which was non-existent previously. The wife describes the patient's past behavior and drug use (hashish and marijuana) as a pattern of binge drinking coupled with violent behavior resulting in trouble with the law, work and family. The patient is described as a 'go-getter' a fighter for what he wants and generally an optimistic individual although impulsive. The patient is described as a 'fun guy' by friends.

The patient and wife are hopeful that the present crisis will provide insight and stabilization and priority of marital relationship. Continued counseling is indicated to deal with economic impact of injuries as well as helping the couple cope with the devastating injuries of friend and abstinence from drugs.

CRASH TIME LINE, CASE 418:

T - 2 seconds: The vehicle involved in this collision, a 1987

Chevrolet Celebrity 4 door sedan, was westbound on a winding 2 lane asphalt road in wooded hill country. The collision occurred on a clear weekday night in a rural area. The roadway was dry, well marked, not lighted, and had a posted speed limit of 30 miles per hour. The eastbound lane is approximately 9.6 feet wide and bordered on the south by a solid white line. The westbound lane is approximately 9.6 feet wide and bordered on the north by a solid white line. There is a double yellow center stripe separating the 2 lanes. In the area of the collision, there is a 3.7 foot paved shoulder on the north road edge which terminates just west of the tree that was contacted. Otherwise the roadway is bordered by woodlands and pasture. There is a superelevation slope of positive 2 percent and a negative longitudinal grade of 4 percent. The estimated coefficient of friction is .73. The vehicle (V1) topped a hill and descended into a tight left-hand curve. The curve has a radius of approximately 229 feet. V1 was traveling at an estimated speed of 50 to 58 miles per hour. The driver, our case index, is a 38 year old male who was not using the available lap and shoulder belt. The other occupant in the vehicle was a 19 year old male. This occupant was at the right front seat position and was using the available lap and shoulder belt. The critical speed of the the curve was calculated to be approximately 50 miles per hour. V1 exceeded this threshold and began moving to the right onto the narrow shoulder that runs along the north road edge.

T - 0: V1 impacted a 3.5 inch diameter wooden mailbox post at the shoulder edge. Since any damage caused by this impact was completely masked by damage from the second impact, the first impact could not be measured on the vehicle. However, the mailbox post shattered at impact producing very little if any change in V1's velocity. This impact most probably produced no injury to the occupants.

T + .077 seconds: V1 impacted a 24 inch diameter tree. Direct contact began approximately in the center of the front bumper and extended to the right front bumper corner. Maximum longitudinal crush at the right front bumper corner was measured to be 59.4 inches. There was an 8 inch diameter limb rising from the main trunk of the tree that caused additional longitudinal crush at the junction of the right A pillar and the roof of the vehicle. There was no evidence of vehicle rotation or rebound after impact with the tree. The vehicle deformation was a strict 12 O'clock longitudinal pattern with an estimated speed change at impact of 52.7 miles per hour. Upon impact the right toepan intruded longitudinally 31.8 inches. The right, center, and left instrument panels intruded 23.7, 14.6, and 11.2 inches respectively. These intrusions were also longitudinal. The left toe pan intruded longitudinally 9.6 inches and the steering column intruded longitudinally 4.5 inches. The driver was forced forward at impact. It is probable that his left hand was positioned at the top of the steering rim at impact. There was significant deformation and abrasion to the top of the rim and to the left instrument panel behind the rim. The driver sustained

associated left first metacarpal, left third proximal phalanx, left radius, left ulna, and left clavicle fractures. There was another driver contact point on the center instrument panel evidenced by abraded plastic and tissue deposits but no associated injury could be positively attributed to it. The driver suffered unspecified closed head trauma and multiple facial abrasions and lacerations. These injuries appear to have been caused by upper steering rim and possibly left instrument panel contact. There were 2 heavy knee impacts to the left lower instrument panel from which the driver sustained an associated right femur fracture. He also sustained a fracture to the right iliac wing. There was an abraded lower steering rim associated with this injury, however the lower steering rim was modified by rescue personnel at the scene. The right front passenger was also forced forward at impact. His head contacted the roof at the A pillar junction. This is also the point at which the tree limb had crushed into the roof. By the time the occupant's head reached the contact point, metal edges from the windshield header were exposed. There was torn fabric and brain tissue found on the roof just opposite the tree limb deformation. Associated injuries include a depressed frontal skull fracture with dural laceration, a left frontal lobe hematoma, a brain stem infarction, a left scalp laceration, a left forehead laceration, a major right forehead avulsion, a right eyelid abrasion, a right lower lip laceration, and a laceration inside the mouth. The occupant was reported as having a Glasgow index of 3. The entire right instrument panel was collapsed by occupant contact and covered with blood and other tissue. There was a fabric transfer and a dent in the right front shock absorber housing that suggests a probable knee impact. There was also possible head contact to the hood of V1. Brain matter, and skin deposits were found on the hood as it was shoved into the right A pillar/roof junction area at impact. V1 came to rest facing west still fully engaged with the tree. Both occupants were taken to a trauma hospital for treatment.

T + 5 minutes: The Police were notified that the collision had occurred.

T + 13 minutes: The Police arrived at the scene.

PREHOSPITAL AND HOSPITAL TIMELINE - CASE 418

T+ 23min: Ambulance receives call to respond.

T+ 35min: Ambulance arrives at scene. Initial field assessment reveals a blood pressure of 118/78, a heart rate of 76, a respiratory rate of 16 and a Glasgow Coma Score of 15. Prehospital care includes application of MAST suit and administration of oxygen.

T+ 67 min: Patient departs scene for MIEMSS/Shock Trauma by police medevac helicopter.

T+ 95 min: Patient arrives at MIEMSS/Shock Trauma. Initial physiological assessment reveals a blood pressure of 123/69, a

heart rate of 118, a respiratory rate of 26, and a Glasgow Coma Score of 15. The patient's ISS (Injury Severity Score) was 14. Results of the toxicology screen were positive for alcohol (43mg/dl). Initial hospital care provided includes:

-Evaluation by a MIEMSS trauma team,
-Fluid Resuscitation,
-Full diagnostic evaluation including x-rays of the cervical spine, chest and pelvis. In addition to the toxicology screen, an arterial blood gas, a CBC (complete blood count), an SMA-6 (routine blood chemistry) and a UA (urinalysis) were performed.
-Diagnostic peritoneal Lavage (Negative),

Injuries included the following:

-Laceration of nasal septum (superficial),
-Laceration of lower lip (superficial),
-Fracture of Left Clavicle,
-Laceration of the Right Elbow,
-Fracture of Left Radius (Lower 1/3, Oblique),
-Fracture of Left Ulna (Lower 1/3, Oblique),
-Fracture of Left 1st Metacarpal (Impacted, Proximal Articular Surface),
-Fracture of Left 3rd Prox. Phalanx (Comminuted, Upper 1/3),
-Lacerations of the 1st Left Metacarpal and 3rd Proximal Phalanx,
-Fracture of Right Femur (Transverse, Upper 1/3),
-Fracture of Pelvis, (Right Lateral Compression of Right Iliac Wing).

Operative care includes:

-Repair of the facial and elbow lacerations,
-External Fixation of Left Radius and Ulna,
-Intermedullary Rodding of Right Femur,
-Arthrocentesis of knee.

T+ 24hours-5days: Patient spends 4 days in intensive care and 1 day in the intermediate care unit. No complications were reported during this patient's acute care hospitalization.

T+ 5DAYS: Patient discharged to inpatient rehabilitation hospital.

CRASH COMPARISON - CASE 418

The following table is the result of an initial search of the NHTSA crash test data base on vehicle make and year:

Table 418-1
CHEVROLET CELEBRITY

MAK	MOD	BOD	T#	YR	LBS.	LENGTH	WIDTH	COG	WBASE	SPEED	V#	CRUSH
01	32	4S	1119	85	2849	188.00	67.80	41	104.80	0.00	2	16.00
			806	84	3395	189.80	70.00	43	105.10	54.80	1	23.80

	810	84	3392	188.50	69.50	44	105.00	37.70	2	11.60
	812	84	3392	188.20	69.50	43	105.00	55.60	2	20.70
	887	84	3374	188.30	67.80	45	104.90	0.00	2	15.40
	645	83	3405	188.30	69.30	44	104.90	31.10	2	27.50
	659	83	2745	188.00	68.40	38	105.00	29.70	1	20.00
	773	83	3410	186.20	60.00	42	105.00	29.90	1	23.80
	776	83	3390	185.00	60.00	45	104.70	29.70	1	22.30
	824	83	3445	188.40	69.70	44	105.20	56.50	2	27.20
	866	83	3437	188.80	69.40	46	105.30	53.90	2	35.30
	451	82	3273	188.30	67.70	32	104.50	35.00	1	26.20
	888	82	2925	188.30	67.80	43	104.90	23.00	1	99.90
SW	688	84	3590	191.80	67.80	49	104.70	35.00	1	29.00

Some of these are vehicle to vehicle cases but there are some vehicle to barrier in the group. Since we have a wide choice, the selection process takes into account the speed and crush characteristics of the test case. Of these cases, the one that comes the closest to matching the actual case in the damage profile is that of 688. Case 688 also has the advantage of being a test crash involving a pole which is somewhat closer to a tree than a flat barrier.

Comparison of Crash Test Curves:

The instrumentation curves for this test case are at Figures 418-1 and 2. They were taken from the vehicle center of gravity and the engine on the X axis direction (i.e. forward). The peak to peak average G force appears to be about 45 Gs over a period of about 60 milliseconds. Of the two curves, the engine curve shows the more stable results. Usually it is the center of gravity. Rear deck and firewall instrumentation was not in this test so could not be used for validation of the two curves shown.

Comparison of Injuries:

The curve for the head COG for the driver occupant (this case index) is at Figure 418-3. It shows a rather sharp deceleration pattern as is common for driver occupants in this type of crash test. Remember that this crash test is with a pole and as a result the crash impact is not as sudden as it would be with a tree. The pole is far more elastic. Review of the injury data for the crash test 688 shows that the driver dummy occupant sustained an HIC of 518 and a CSI of 238. This is generally consistent with that sustained by the actual crash occupant. The more leg and lower body injuries suffered in this case were apparently caused by the upward movement and contact with the steering rim allowed by the lack of proper restraints. The test case dummy showed no such lower body injuries as severe as this case. Further, the delta V of the accident was much higher in the actual case (52mph) as against 35 mph in the test case.
Significance of crash:

This case is related to case #169, and therefore many of the statistics are similar. This case covers injuries to the driver of the vehicle while case #169 covers injuries to the passenger.

The NASS reports that collisions with objects will result in an AIS >= 3 only 3% of the time. Also there is only a 3% incidence of AIS 3 or greater in rural accidents at speeds in excess of 55mph. In cases of AIS 3 injuries, the steering wheel is the object causing the injury 16% of the time and is the single largest cause of AIS 3 or greater injuries. It is also interesting to note that in the case the intrusions were in excess of 12 inches and NASS tells us that this will increase the chances of serious injury to 25%.

The accident itself is very common. 43% of all passenger car crashes are in rural areas involving speeds in excess of 55mph. Further 49% of all frontal crashes will result in injuries of AIS = 1 or more while only 2% will result in AIS >= 3. Why then, the severity of this case?

It is apparent that the severity of injury is due to the combination of events including the lack of restraint, striking the steering wheel and interior intrusions exceeding 12 inches.

The driver can consider himself fortunate in that 65% of occupant fatalities are in passenger cars and a great many of these are the driver. That may be of little solace though when it turns out that less than 3% are injured AIS 3 or greater by a collision with a fixed object and less than 0.5% are killed by collision with a tree, making this a rather low incidence crash as far as severity of result. Had the driver been wearing the seat belt in a frontal crash like this, he would have fared much better as he would have had a 30% better chance of avoiding an AIS 3 injury.

PSYCHOSOCIAL FOLLOW-UP - CASE 418

3 Months

After spending 23 days at an in-state rehabiliation hospital, the patient was discharges to home with physical therapy prescribed three times per week and one occupational therapy session per week. The patient walks with a limp and has a wedge in his shoe in order to assist with his gait. The patient admits to having experienced flashbacks about the accident and more sensitive to noise and is in the ocess of relocating to a quieter area. The patient also indicates dsitractibilty and working on several projects and unable to focus on one to completion. The patient is also attempting to locate his eight year old son from a previous relationship in order to establish paternity. This has created dissent in his marriage. The wife states that the patient has withdrawn funds from their bank account and frequently gone off for several days at a time. She

is concerned that his changes in behavior may be indicative of a return to substance abuse. The patient has not returned to work at T + 3 months but anticipates doing so within a month with few restrictions.

6 Months

Patient discharged from Shock Trauma 5 days post-trauma to inpatient rehabilitation facility non-ambulatory with limited weight bearing.

Patient spent 23 days at in-state rehabilitation hospital, discharged home with physical therapy three times per week and occupational therapy weekly. Initially patient quit drinking, joined AA, attended psychotherapy sessions and was high on religion. By three months, these behaviors did not appear as strong. Patient walks with a limp, and has wedge in shoe to assist with his gait. Patient admits to having experienced "flashbacks" about accident and is more sensitive to noise. Patient also indicates distractibility and inability to focus on tasks to completion. Patient is attempting to locate 8-year-old son from prior relationship and establish paternity, which has created dissent in marriage. Wife states patient has withdrawn funds from bank account and is frequently gone for several days at a time. Concerns that changes in behavior indicative of return to substance abuse. Patient had not returned to work 6 months post-trauma. Patient also exhibited decreased attention span and distractibility with memory deficits.

1 Year

Due lack of funds, patient and wife were evicted from their home and relocated to trailer home with assistance from wife's mother. Patient unable to hold job due to physical pain associated with leg and severe memory lapses of uncertain etiology. Wife works sporadically but finds it difficult to leave husband home alone due to poor judgement and his increased dependency on her. In addition to financial deprivation, patient exhibits increased irritability, lack of motivation, angry outbursts, erratic sleeping patterns and depression, similar to post-traumatic stress syndrome. Wife states patient drinks less than pre-injury and no is longer a "wild and carefree guy" - very different and difficult to get along with due his behavioral and personality inconsistencies. Patient rarely socializes.

Patient needs to re-apply for Medical Assistance as coverage expired, and is in process of applying for Social Security Disability. Referrals also made for vocational rehabilitation and neuropsychology evaluation due to patient's poor functioning. Referral to Center for Living also indicated for help with community re-integration.

Patient severely disabled due to physical and cognitive problems and unable to resume functional activities at 1 year post-trauma.

PREVENTION AND INJURY REDUCTION - CASE 418

This crash occurred on a curve that has a radius of 230 feet. By modern standards, this is a severe curve. Couple this type of curved, tree-lined roadway with a vehicle operator who is under the influence alcohol, and you have set the stage for a crash. As we hurry from point to point on these winding roads, we often do not realize how close we sometimes come to exceeding the sideslip threshold and losing control of a car. Complicate the situation with a couple of alcoholic beverages and it is easy to cross this threshold and lose control of the vehicle, or depart the roadway while attempting to remain in control. In this particular case, had the driver reacted even slightly better (no alcohol), he may have missed the tree and departed the roadway in an open field. It was a matter of about 3 lateral feet. A fraction of a second.

From the mechanical aspect, this is another case where a steering hub mounted air cushion restraint device and usage of the manual restraints would certainly have reduced if not eliminated many of the driver's injuries. All 10 of his injuries resulted from contact to either the steering assembly or the left instrument panel. Considering the 52 mile per hour Delta V, he was actually very lucky. His passenger was not so lucky. The right front seat position sustained catastrophic intrusion. It is hard to imagine any preventative measures from a structural standpoint that could deal practically with this impact configuration, however, the passenger's most severe injuries (2 of AIS-5, 2 of AIS-4; all head injuries) might have been greatly reduced in severity if only there were something to pad the contact area. A roof or "A" pillar mounted Air Bag would certainly have helped, and in this case, even a piece of sturdy fabric such as the fabric that Air Bags are constructed of would have shielded the passenger's head from the exposed metal. (additional observations); Upon inspection of the vehicle in this case, the after-crash position of the right "A" pillar was hard to determine due to alterations made by rescue personnel. The fact that one could only estimate the 3 dimensional measurements for the right front passenger's head impact made it hard for the biodynamics team to reconstruct this occupant's motion. The coding indicated that this occupant used the manual lap and shoulder belt, but restraint failure was unknown. This is because there was evidence that the belt was cut from his body, but no evidence of stretched webbing. The biodynamic reconstruction showed heavy occupant loading of the belt webbing. There are 2 possible explanations for the combined evidence. Either the belt failed to lock at impact, or the "A" pillar and right instrument panel longitudinal intrusion was was extensive enough to stop the occupant's forward motion before he fully loaded the restraint system. The field investigator tends to favor the latter explanation. Would a 5 point harness have helped? It is hard to say without knowing the exact position of the "A" pillar.

---- Jerry Jackson

PREVENTION COMMENTS - CASES 418 AND 169

Case 418 was a 38-year-old male driver with a previous history of alcohol who apparently also had been drinking at the time of this accident. He was traveling with the occupant (Case #169) who was a 19-year-old male. The driver was not wearing a seatbelt. He sustained closed head trauma of a minor degree with facial lacerations primarily from the steering rim. He had an ulnar/radius fracture from the left instrument panel, as well as a right iliac wing fracture probably from the steering panel and left femur fracture from impact with the left instrument panel. This patient was driving at a high rate of speed on a curve which was rated for a much lower speed. Alcohol may well have impaired his judgement. The car struck a tree and his passenger was killed. The (driver-case 418) patient would clearly have been protected had worn a seatbelt or other operational three-point restraint system been available and used. An airbag also would have prevented the mild head trauma and would probably have prevented him from driving his left arm into the instrument panel. Better protection from the engine moving backward would probably have prevented the knee from striking the instrument panel causing the subsequent femur fracture.

In this case, the long term outcome was very significant because the closed head injury, although minor in degree produced severe psychological changes in this patient. It interfered with both his social orientation as well as his goal to continue working. This was compounded as well by his femur fracture a disability in mobility, since he was a telephone lineman. As a result, the long-term impacts of not protecting this patient with a relatively simple device (airbag), were substantial in terms of cost and a bad outcome.

Case 169 was a 19 year old passenger who was belted with a lap and shoulder belt; he sustained a severe head injury when the car, driven by the 38-year-old (Case 418) probably under the influence of alcohol, struck a tree with intrusion of the right side A-pillar and roof structures into the car. This produced an open skull fracture with exposed brain in Case 169. Secondarily, the patient developed meningitis and had to be treated by extensive use of antibiotics. He had a Glasgow Coma Score of 3 on admission as well as forehead lacerations and avulsions. All of these could have been ameliorated to some degree, if not prevented, by having a passenger airbag especially one that would include the A-pillar. The head injuries might also have been prevented by having a stronger structure to the front of the car which might have prevented the collapse of the passenger compartment A-pillar. The patient's injury was very severe and resulted in a vegetative state that will require persistent and continued custodial care.

The pre-hospital time for case #169 was 114 minutes and there were numerous factors involved in causing this prolonged time; none of which could necessarily have been reduced and part of this delay was attributed to an extended time required for extrication.

COLLISION SCEMATIC
CASE 418

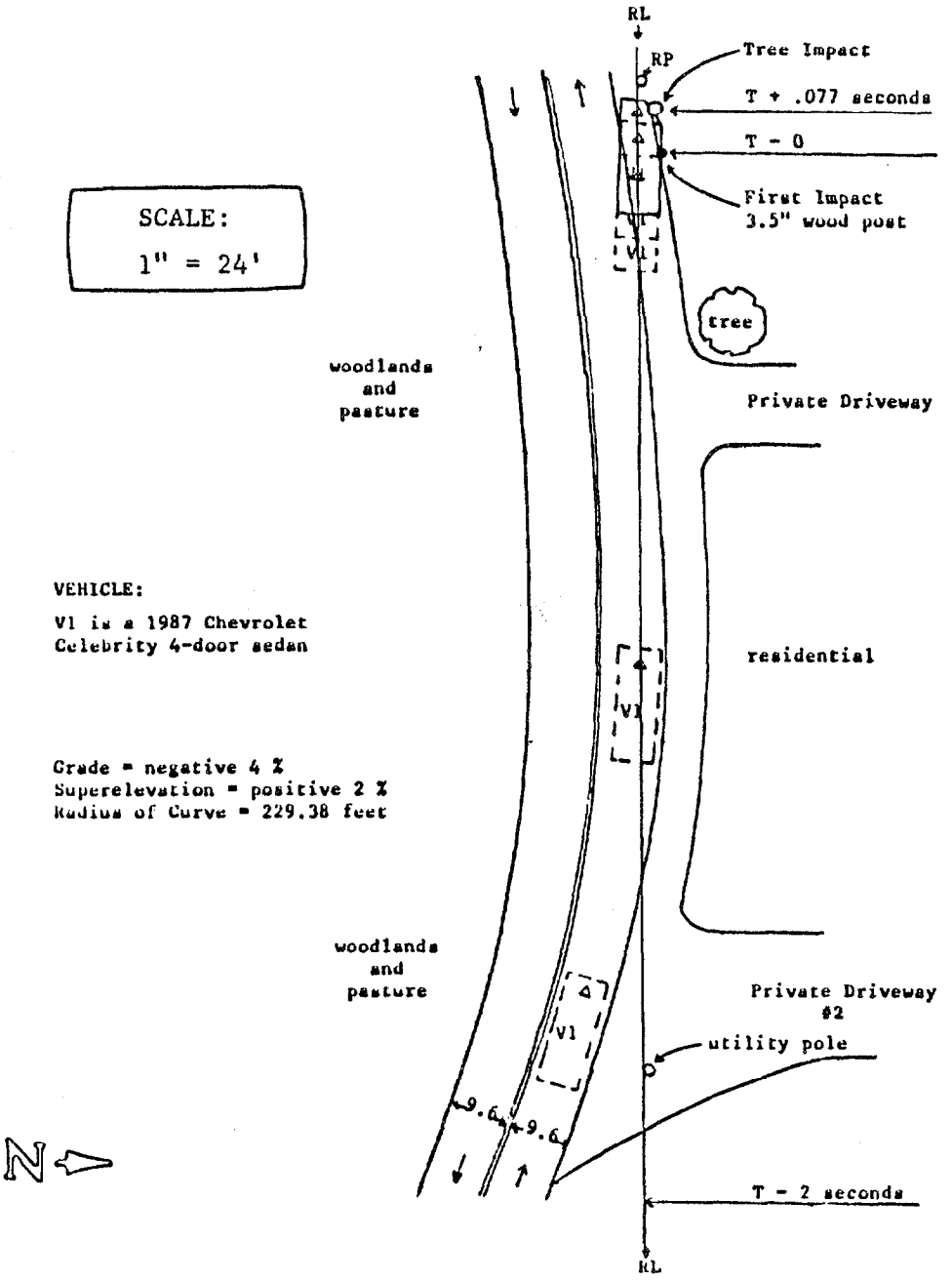

SELECTED PHOTOGRAPHS, CASE 418

1.

Scene. V1 direction of travel. Curve radius = 229 feet. Vertical alignment = negative 4 percent. Superelevation = positive 2 %.

2.



V1 (1987 Chevrolet Celebrity 4 door sedan). Frontal tree impact. Delta V= 52.7 m.p.h. Max crush= 59.4 inches. Roof altered; rescue

SELECTED PHOTOGRAPHS, CASE 418

3.



Driver's position. Steering rim (AIS-2 head AIS-2 shoulder AIS-2 pelvis). Upper right Left Instrument Panel (AIS-1 face).

4.



Driver's position. Lower Left Instrument Panel (AIS-3 femur). Left Instrument Panel? (AIS-2 forearm/hand). Driver unrestrained.

SELECTED PHOTOGRAPHS, CASE 418

5.

Object contacted. 24 inch diameter tree with protruding limb. Note abrasions to limb; right "A" pillar/ roof junction contact.

418A Facial abrasions and lacerations. The patient's left clavicle fracture has been reduced and is immobilized.

Contact Point- Left instrument panel
Type of Crash- Frontal impact
Estimated Force of Impact- Head/Windshield- 1870 lbs.
- Head/Steering Rim- 280 lbs.

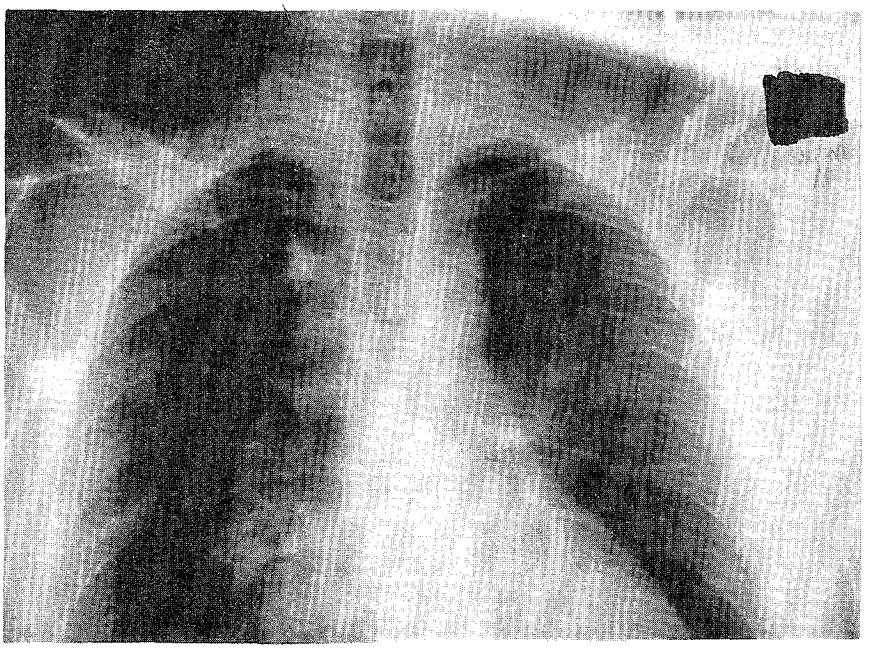

418B X-Ray reveals a transverse midshaft fracture of the left clavicle.

Contact Point- Steering Wheel Rim
Type of Crash- Frontal impact
Estimated Force of Chest Impact- 1500 lbs.

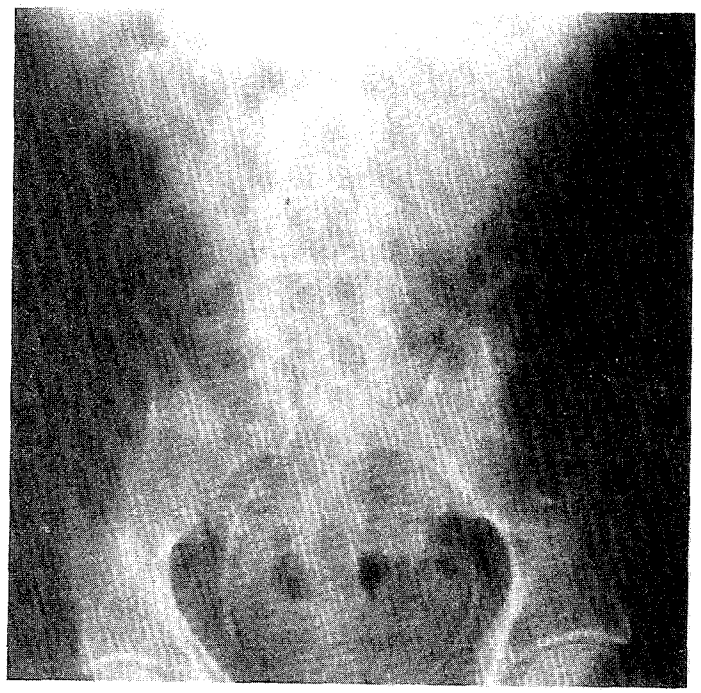

418C Pelvic fracture reveals a nondisplaced right iliac wing fracture.

Contact Point- Steering Wheel Rim
Type of Crash- Frontal impact

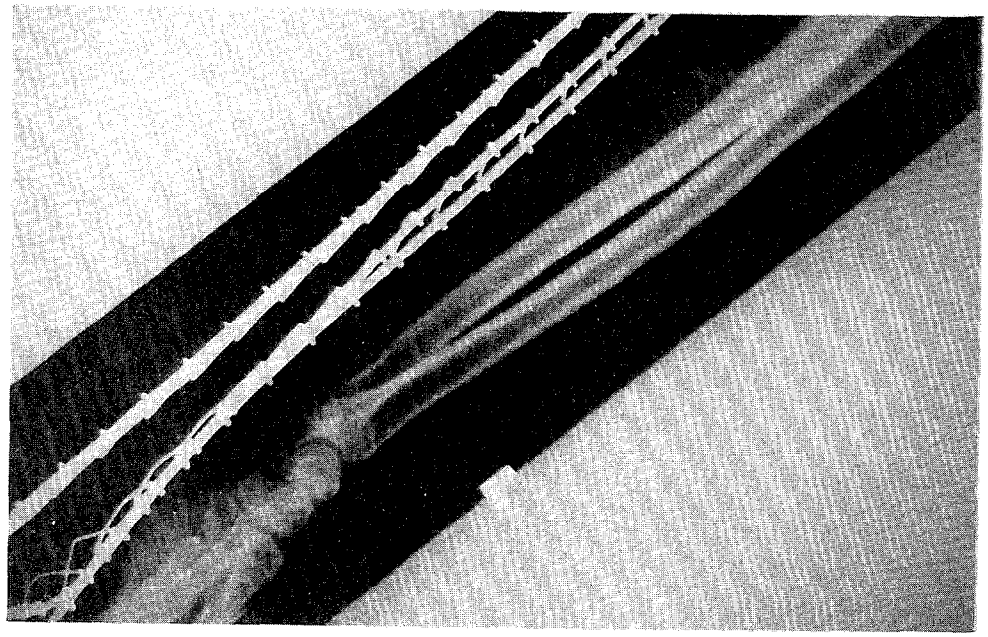

418D X-Ray reveals distal 1/3, transverse fractures of the left radius and ulna extending to the wrist joint, involving the articular surfaces of the bones.

Contact Point- Left instrument panel
Type of Crash- Frontal impact
Estimated Force of Impact- 500 lbs.

SUMMARY - CASE 169 (008)

This single vehicle accident occurred on a clear, winter, weekday night. The collision involved a 1987 Chevrolet Celebrity 4 door sedan with a 38 year old male driver and a 19 year old male right front passenger. The vehicle (V1) was westbound on a winding 2 lane asphalt road in wooded hill country. V1 topped a hill and decended into a sharp left-hand turn at an estimated speed of 50 to 58 miles per hour. The vehicle moved onto the right shoulder and struck a 3.5 inch mailbox post head-on. V1 then traveled an additional 6 feet westward before impacting a 24 inch diameter tree head-on. There was no evidence of any skidding or yawing before impact and no evidence of significant rebound or rotation after impact. The driver who was not using the available lap and shoulder belt was seriously injured and was transported to a trauma hospital for treatment. The right front passenger, our case index, was using the available lap and shoulder belt and was critically injured. Injuries sustained by this case are listed below in OIC format.

BODY CONTACTS AND INJURIES TABLE-CASE 169
19 year old male, right front passenger, frontal impact

	OIC/AIS CODE	ICD-9	CONTACTS OR INJURIES	CONTACT POINT
1.	2HWKB5 371199	850.5	Glasgow Coma - 3	A Pillar/Roof
2.	2HAFS4 371199	800.75	Frontal Skull Fracture	A Pillar/Roof
3.	2HIUB5 371299	851.55	Brain Stem Infarction	A Pillar/Roof
4.	2HALI1 371199	873.1	Left scalp Laceration	A Pillar/Roof
5.	2HAUB4 371199	851.35	Dural Laceration	A Pillar/Roof
6.	2FSVI3 371199	873.52	Forehead Avulsion	A Pillar/Roof
7.	2FSLI1 371199	873.42	Forehead Laceration	A Pillar/Roof
8.	2FRAO1 371199	918.0	Abraded Right Eyelid	A Pillar/Roof
9.	2FILI1 112102	873.43	Lower Lip Laceration	Right Inst. Panel
10.	2FILD1 112102	873.69	Laceration In Mouth	Right Inst. Panel

PSYCHOSOCIAL TIMELINE - CASE 169

Initial Interview

The patient is a 19-year-old, single male who was admitted to MIEMSS Shock Trauma with multiple injuries and massive head injuries suffered in a motor vehicle accident. The patient was a passenger in a vehicle driven by Study Patient #418 who was discharged to an inpatient rehabilitation hospital at T + 5 days.

The patient (169), at T + 3 weeks, remains hospitalized in critical condition an unable to communicate. Prior to injury, the patient had been living with friends of the family (Pt. #418 and wife) to be closer to his high school. The patient was a

senior with average grades and excelled in drama. The patient and mother had recently moved back to the State from Florida following the mother's second divorce. The patient does have a half-brother living with his former stepfather and another half-brother is the result of his own father's second marriage. Interaction with siblings is minimal however, although relationship with father is described as close and intense despite sporadic contacts. The patient and parents are also involved providing emotional support. The mother is living with boyfriend and conflict between boyfriend and patient precipitated the patient's move to Case #418's home. The patient continued to have daily contact with mother.

The mother describes the patient as one who has weathered past crises (e.g. two difficult divorces and lingering illnesses, institutionalization and death of maternal grandfather, and friend's suicide over the past year as well as a change of residence and developing a new support group.) The patient also has a history of excessive drinking and drug abuse (cocaine and LSD) and was involved in a drug rehab program as well as Al-Anon. The family has availed themselves of counseling in the past and are receptive and motivated to seek out such therapy to enhance coping and communication. The patient's stepfather had a long history of alcohol and drug abuse which the mother feels attributed to addictions for both patient and self. The mother reports that the patient has abstained from drug use for the past two years but that the patient is a 'weekend drinker' when with peers and describes this same behavior as 'typical for high school seniors.' The mother feels that the patient is intoxicated less frequently than in the past and had been exhibiting more responsible drinking behavior due to increased self-esteem derived from school. The patient's drama coach has "taken the patient under his wing" and describes the youth as a talented comedic actor as well as being very expressive in music and writing. Interestingly, prior to the injury, the patient portrayed a retarded man in a school play and achieved numerous successes this past academic year in school and community productions. Although interested in soccer and basketball, activities are limited to drama. The patient appears to be a young man who has successfully overcome drug abuse and was just beginning to focus in on future career development while gaining in maturity and independence. Family and peers appear supportive, however, efforts to communicate with nuclear and blended families may pose some difficulties and differences. Mother and patient's dependence on one another will be drastically altered and psychosocial intervention is indicated.

CRASH TIME LINE - CASE 169

T - 2 seconds: The vehicle involved in this collision, a 1987 Chevrolet Celebrity 4 door sedan, was westbound on a winding

2 lane asphalt road in wooded hill country. The collision occurred on a clear weekday night in a rural area. The roadway was dry, well marked, not lighted, and had a posted speed limit of 30 miles per hour. The eastbound lane is approximately 9.6 feet wide and bordered on the south by a solid white line. The westbound lane is approximately 9.6 feet wide and bordered on the north by a solid white line. There is a double yellow center stripe separating the 2 lanes. In the area of the collision, there is a 3.7 foot paved shoulder on the north road edge which terminates just west of the tree that was contacted. Otherwise the roadway is bordered by woodlands and pasture. There is a superelevation slope of positive 2 percent and a negative longitudinal grade of 4 percent. The estimated coefficient of friction is .73. The vehicle (V1) topped a hill and descended into a tight left-hand curve. The curve has a radius of approximately 229 feet. V1 was traveling at an estimated speed of 50 to 58 miles per hour. The driver, a 38 year old male, was not using the available lap and shoulder belt. The only other occupant in the vehicle was a 19 year old male who is our case index. This occupant was at the right front seat position and was using the available lap and shoulder belt. The critical speed of the curve was calculated to be approximately 50 miles per hour. V1 exceeded this threshold and began moving to the right onto the narrow shoulder that runs along the north road edge.

T - 0: V1 impacted a 3.5 inch diameter wooden mailbox post at the shoulder edge. Since any damage caused by this impact was completely masked by damage from the second impact, the first impact could not be measured on the vehicle. However, the mailbox post shattered at impact producing very little if any change in V1's velocity. This impact most probably produced no injury to the occupants.

T + .077 seconds: V1 impacted a 24 inch diameter tree. Direct contact began approximately in the center of the front bumper and extended to the right front bumper corner. Maximum longitudinal crush at the right front bumper corner was measured to be 59.4 inches. There was an 8 inch diameter limb rising from the main trunk of the tree that caused additional longitudinal crush at the junction of the right A pillar and the roof of the vehicle. There was no evidence of vehicle rotation or rebound after impact with the tree. The vehicle deformation was a strict 12 O'clock longitudinal pattern with an estimated speed change at impact of 52.7 miles per hour. Upon impact the right toepan intruded longitudinally 31.8 inches. The right, center, and left instrument panels intruded 23.7, 14.6, and 11.2 inches respectively. These intrusions were also longitudinal. The left toe pan intruded longitudinally 9.6 inches and the steering column intruded longitudinally 4.5 inches. The driver was forced forward at impact. It is probable that his left hand was positioned at the top of the steering rim at impact. There was significant deformation and abrasion to the top of the rim and to the left instrument panel behind the rim. The driver sustained associated left first metacarpal, left third proximal phalanx,

left radius, left ulna, and left clavicle fractures. There was another driver contact point on the center instrument panel evidenced by abraded plastic and tissue deposits but no associated injury could be positively attributed to it. The driver suffered unspecified closed head trauma and multiple facial abrasions and lacerations. These injuries appear to have been caused by upper steering rim and possibly left instrument panel contact. There were 2 heavy knee impacts to the left lower instrument panel from which the driver sustained an associated right femur fracture. He also sustained a fracture to the right iliac wing. There was an abraded lower steering rim associated with this injury, however the lower steering rim was modified by rescue personnel at the scene. The right front passenger, our case index, was also forced forward at impact. His head contacted the roof at the A pillar junction. This is also the point at which the tree limb had crushed into the roof. By the time the occupant's head reached the contact point, metal edges from the windshield header were exposed. There was torn fabric and brain tissue found on the roof just opposite the tree limb deformation. Associated injuries include a depressed frontal skull fracture with dural laceration, a left frontal lobe hematoma, a brain stem infarction, a left scalp laceration, a left forehead laceration, a major right forehead avulsion, a right eyelid abrasion, a right lower lip laceration, and a laceration inside the mouth. The occupant was reported as having a Glasgow index of 3. The entire right instrument panel was collapsed by occupant contact and covered with blood and other tissue. There was a fabric transfer and a dent in the right front shock absorber housing that suggests a probable knee impact. There was also possible head contact to the hood of V1. Brain matter, and skin deposits were found on the hood as it was shoved into the right A pillar/roof junction area at impact. V1 came to rest facing west still fully engaged with the tree. Both occupants were taken to a trauma hospital for treatment.

T + 5 minutes: The Police were notified that the collision had occurred.

T + 13 minutes: The Police arrived at the scene.

PREHOSPITAL AND HOSPITAL TIMELINE - CASE 169

T+ 3min: Ambulance receives call to respond.

T+15min: Ambulance arrives at scene. Initial field assessment reveals a blood pressure of 80/PALP, a heart rate of 80, a respiratory rate of 36 and a Glasgow Coma Score of 3. The patient had external hemorrhaging in excess of 1000cc. Prehospital care included application and inflation of a MAST suit, administration of oxygen, wound dressing and administration of 1000cc of crystalloid. The patient required extrication from the vehicle.

T+98min.: Patient is evacuated from the scene by state

police medevac helicopter.

T +117min.: Patient arrives at MIEMSS/Shock Trauma. Initial physiological assessment reveals a blood pressure of 108/74, a heart rate of 125, a respiratory rate of 29, and a Glasgow Coma Score of 4. The patient's ISS (Injury Severity Score) was 27. Results of the toxicology screen were positive for alcohol (22 mg/dl).

Initial care provided included the following procedures:

- -Evaluation by a MIEMSS Trauma Team,
- -Fluid Resuscitation,
- -Full diagnostic evaluation including x-rays of the cervical spine, chest and pelvis. In addition to the toxicology screen, an arterial blood gas, a CBC (complete blood count), an SMA-6 (routine blood chemistry) and a UA (urinalysis) were performed. This patient also underwent a head CT Scan.

Injuries noted include the following:

- -Right frontal scalp avulsion (with major tissue loss),
- -Right frontal scalp laceration (Deep),
- -Left Frontal scalp Laceration (Deep),
- -Right forehead avulsion,
- -Left forehead laceration (Deep),
- -Brain injury- brainstem infarction,
- -Brain injury- Right frontal lobe intraparenchymal hematoma,
- -Brain injury- Left frontal lobe epidural hematoma (<100cc),
- -Right frontal skull fracture (open, depressed with dural laceration and cerebrospinal fluid leak),
- -Right eyelid abrasion,
- -Right scleral and global abrasion, contusion and hematoma,
- -Lower lip laceration (deep),
- -Oral cavity floor laceration

Operative procedures included:

- -Placement of Intracranial Pressure (ICP) Monitor, and debridement of right cerebral hemisphere,
- -Craniotomy and evacuation of intracerebral hematoma.

T+ 24 hours - 67 days: The patient remains in intensive care with a Glasgow Coma Score of 4. Complications include a calculus cholecystitis which necessitated a cholecystectomy. Prolonged endotracheal intubation necessitated a tracheostomy and temporary gastrostomy.

T + 67 days: Patient discharged from MIEMSS to an inpatient long term rehabilitation center.

COGNITIVE-COMMUNICATIVE ASSESSMENT - CASE 169

The patient was initially evaluated on T + 27 days. The patient exhibited spontaneous eye opening but did not respond to any stimulation presented. Severe deficits were noted across all assessment areas. The patient was felt to be functioning at an RLAS II- Generalized response level (Rancho Los Amigos Score.)

Aggressive treatment was recommended for low-level stimulation. The patient could not respond to the hearing test and was NPO, or unable to be administered anything by mouth.

The patient received daily treatment sessions and was re-evaluated at the time of discharge to rehabilitation (T + 76 days). While the patient had made no significant gains upon evaluation, he was beginning to exhibit some localization behaviors- moving eyes towards the source of stimuli. The patient continued to function at the RLAS II level. Aggressive therapy was recommended while in rehabilitation. Audiology diagnosed a mild to moderate hearing loss using BSER. The patient continued to be NPO at this time.

The patient was reevaluated at T + 5 months, or 3 months post-discharge. Again, the patient was unable to respond to the assessment items. However, he was exhibiting much more consistent localized responses. The patient was felt to be functioning at an RLAS II, Emerging III Localized Response level. Treatment was recommended to continue. No changes in hearing or swallowing were noted. The patient is to be re-evaluated in 3 months.

CRASH COMPARISON - CASE 169

The following table is the result of an initial search of the NHTSA crash test data base on vehicle make and year:

Table 169-1
CHEVROLET CELEBRITY

MAK	MOD	BOD	T#	YR	LBS.	LENGTH	WIDTH	COG	WBASE	SPEED	V#	CRUSH
01	32	4S	1119	85	2849	188.00	67.80	41	104.80	0.00	2	16.00
			806	84	3395	189.80	70.00	43	105.10	54.80	1	23.80
			810	84	3392	188.50	69.50	44	105.00	37.70	2	11.60
			812	84	3392	188.20	69.50	43	105.00	55.60	2	20.70
			887	84	3374	188.30	67.80	45	104.90	0.00	2	15.40
			645	83	3405	188.30	69.30	44	104.90	31.10	2	27.50
			659	83	2745	188.00	68.40	38	105.00	29.70	1	20.00
			773	83	3410	186.20	60.00	42	105.00	29.90	1	23.80
			776	83	3390	185.00	60.00	45	104.70	29.70	1	22.30
			824	83	3445	188.40	69.70	44	105.20	56.50	2	27.20
			866	83	3437	188.80	69.40	46	105.30	53.90	2	35.30
			451	82	3273	188.30	67.70	32	104.50	35.00	1	26.20
			888	82	2925	188.30	67.80	43	104.90	23.00	1	99.90
		SW	688	84	3590	191.80	67.80	49	104.70	35.00	1	29.00

Some of these are vehicle to vehicle cases but there are some vehicle to barrier in the group. Since we have a wide choice, the selection process takes into account the speed and crush characteristics of the test case. Of these cases, the one that comes the closest to matching the actual case in the damage

profile is that of 688. Case 688 also has the advantage of being a test crash involving a pole which is somewhat closer to a tree than a flat barrier.

Comparison of Crash Test Curves:

The instrumentation curves for this test case are at Figures 169-1 and 2. They were taken from the vehicle center of Gravity AND the engine on the X axis direction (i.e. forward). The peak to peak average G force appears to be about 45 Gs over a period of about 60 milliseconds. Of the two curves, the engine curve shows the more stable results. Usually it is the center of gravity. Rear deck and firewall instrumentation was not in this test so could not be used for validation of the two curves shown.

Comparison of Injuries:

The curves for the head COG for the right front seat occupant (this case index) is at Figure 169-3. It shows a rather steady deceleration pattern as is common for right side occupants in this type of crash test. Remember that this crash test is with a pole and as a result the crash impact is not as sudden as it would be with a tree. The pole is far more elastic. Review of the injury data for the crash test 688 shows that the right hand seat dummy occupant sustained an HIC of 440 and a CSI of 222. This is way lower than that sustained by the actual crash occupant. There is, however an explanation of this. Both the test case and the actual case occupants were restrained, however, in the actual case it was not so much the forward movement of the occupant but the rearward movement of the roof and "A" pillar intrusion that caused the severe injury to the head. Unfortunately, NHTSA crash tests do not involve freak accidents of nature such as a tree limb projecting at just the right height to be lethal. Further, the delta V of the accident was much higher in the actual case (52mph) as against 35 mph in the test case.

Significance of the Crash:

The NASS reports that collisions with objects will result in an AIS >= 3 only 3% of the time. Also there is only a 3% incidence of AIS 3 or greater in rural accidents at speeds in excess of 55mph. From this it would seem that the probability was that the injuries sustained would not have been likely to be very serious.

The accident itself is very common. 43% of all passenger car crashes are in rural areas involving speeds in excess of 55mph. Further 49% of all frontal crashes will result in injuries of AIS = 1 or more while only 2% will result in AIS >= 3. Why then, the severity of this case?

The occupant here was unlucky on two counts. First the fact that

a tree limb projected outward from the trunk of the tree at roof height and at the right side of the car. Second, that the tree limb caused a crush of the roof and "A" pillar and a resulting intrusion of in excess of 12". Actually, the right side dash panel intruded some 24 inches. Statistically, this increases the chances of an AIS >= 3 to 25% or more.

The occupant can consider himself fortunate in that 65% of occupant fatalities are in passenger cars. That may be of little solace though when it turns out that less than 3% are injured AIS 3 or greater by a collision with a fixed object and less than 0.5% are killed by collision with a tree. This occupant was seriously injured by a happenstance of nature (the tree limb) and the relative weakness of a man made object (the "A" pillar and roof of a car).

PSYCHOSOCIAL FOLLOW-UP - CASE 169

3 Months

At T + 3 Months, the patient remained at an out-of-state rehabilitation facility following 67 days of acute care at MIEMSS Shock Trauma. The patient is not responsive to the environment, opening eyes on command inconsistently. A decision to place the patient in a nursing home has been presented to the family, which they have rejected. The mother has changed to part-time employment due to trips to the rehabilitation center where she plays an active role in the patient's therapy at a cost of approximately $200 per week, in addition to psychotherapy and lost wages.

6 Months

Patient was discharged from Shock Trauma after 67 days in acute care to an out-of-state rehabilitation facility totally dependent in all activities of daily living. At discharge patient was not responsive to his environment, only opening eyes on command inconsistently. At 6 months post-trauma, patient re-admitted to Shock Trauma due to an infection. He is able to sit up independently for only one minute, responds to some simple commands inconsistently and attempts to make purposeful gestures with great prodding. He does not initiate any purposeful behavior. Patient hospitalized in acute care for 21 days and returned to rehabilitation facility. Mother, who is primary spokesperson and caretaker, working part-time due to her active role in patient's therapy. Mother also in psychotherapy. Although insurance coverage continues in full, expenses are increased due to travel, lost wages and costs of housing for mother to be near rehabilitation facility.

1 Year

Following 9 months at rehabilitation facility, patient

discharged to a nursing home due to dependency and total care needs. Patient remains non-verbal, although turns to voices and following minimal commands. He is able to sit independently in a wheelchair but has limited motor skills. Patient is to return to hospital for a cranioplasty and will be re-evaluated for rehabilitation potential as he is making some response now. Insurance continues to cover nursing home care and will cover rehabilitation only if medically recommended.

18 Months

Patient remained in nursing home 8 months. Patient is making some progress, e.g. appropriate gestures, following most commands and beginning to verbalize a few words. He was moved to another state where he has been accepted for further inpatient rehabilitation. Insurance will reach one million cap necessitating medicaid coverage. Patient continues to require total care. However, he is reading words, using a computer and finishing sentences appropriately. He is also beginning to use a walker with assistance and his posture and lower trunk toning is improving. Although still lethargic, he is tolerating fuller days. Patient did receive an insurance settlement.

Patient remains severely disabled at 18 months post-trauma but is beginning to make some progress physically and cognitively.

PREVENTION AND INJURY REDUCTION - CASE 169

This crash occurred on a curve that has a radius of 230 feet. By modern standards, this is a severe curve. Couple this type of curved, tree-lined roadway with a vehicle operator who is under the influence alcohol, and you have set the stage for a crash. As we hurry from point to point on these winding roads, we often do not realize how close we sometimes come to exceeding the sideslip threshold and losing control of a car. Complicate the situation with a couple of alcoholic beverages and it is easy to cross this threshold and lose control of the vehicle, or depart the roadway while attempting to remain in control. In this particular case, had the driver reacted even slightly better (no alcohol), he may have missed the tree and departed the roadway in an open field. It was a matter of about 3 lateral feet. A fraction of a second.

From the mechanical aspect, this is another case where a steering hub mounted air cushion restraint device and usage of the manual restraints would certainly have reduced if not eliminated many of the driver's injuries. All 10 of his injuries resulted from contact to either the steering assembly or the left instrument panel. Considering the 52 mile per hour Delta V, he was actually very lucky. His passenger was not so lucky. The right front seat position sustained catastrophic intrusion. It is hard to imagine any preventative measures from a structural standpoint that could deal practically with this impact configuration, however, the passenger's most severe injuries (2

of AIS-5, 2 of AIS-4; all head injuries) might have been greatly reduced in severity if only there were something to pad the contact area. A roof or "A" pillar mounted Air Bag would certainly have helped, and in this case, even a piece of sturdy fabric such as the fabric that Air Bags are constructed of would have shielded the passenger's head from the exposed metal. (additional observations); Upon inspection of the vehicle in this case, the after-crash position of the right "A" pillar was hard to determine due to alterations made by rescue personnel. The fact that one could only estimate the 3 dimensional measurements for the right front passenger's head impact made it hard for the biodynamics team to reconstruct this occupant's motion. The coding indicated that this occupant used the manual lap and shoulder belt, but restraint failure was unknown. This is because there was evidence that the belt was cut from his body, but no evidence of stretched webbing. The biodynamic reconstruction showed heavy occupant loading of the belt webbing. There are 2 possible explanations for the combined evidence. Either the belt failed to lock at impact, or the "A" pillar and right instrument panel longitudinal intrusion was was extensive enough to stop the occupant's forward motion before he fully loaded the restraint system. The field investigator tends to favor the latter explanation. Would a 5 point harness have helped? It is hard to say without knowing the exact position of the "A" pillar.

---- Jerry Jackson

PREVENTION COMMENTS - CASES 169 AND 418

Case 418 was a 38-year-old male driver with a previous history of alcohol who apparently also had been drinking at the time of this accident. He was traveling with the occupant (Case #169) who was a 19-year-old male. The driver was not wearing a seatbelt. He sustained closed head trauma of a minor degree with facial lacerations primarily from the steering rim. He had an ulnar/radius fracture from the left instrument panel, as well as a right iliac wing fracture probably from the steering panel and left femur fracture from impact with the left instrument panel. This patient was driving at a high rate of speed on a curve which was rated for a much lower speed. Alcohol may well have impaired his judgement. The car struck a tree and his passenger was killed. The (driver-case 418) patient would clearly have been protected had worn a seatbelt or other operational three-point restraint system been available and used. An airbag also would have prevented the mild head trauma and would probably have prevented him from driving his left arm into the instrument panel. Better protection from the engine moving backward would probably have prevented the knee from striking the instrument panel causing the subsequent femur fracture.

In this case, the long term outcome was very significant because the closed head injury, although minor in degree produced

severe psychological changes in this patient. It interfered with both his social orientation as well as his goal to continue working. This was compounded as well by his femur fracture a disability in mobility, since he was a telephone lineman result, the long-term impacts of not protecting this patient with a relatively simple device (airbag), were substantial in terms of cost and a bad outcome.

Case 169 was a 19-year-old passenger who was belted with a lap and shoulder belt; he sustained a severe head injury when the car, driven by the 38-year-old (Case 418) probably under the influence of alcohol, struck a tree with intrusion of the right side A-pillar and roof structures into the car. This produced an open skull fracture with exposed brain in Case 169. Secondarily, the patient developed meningitis and had to be treated by extensive use of antibiotics. He had a Glasgow Coma Score of 3 on admission as well as forehead lacerations and avulsions. All of these could have been ameliorated to some degree, if not prevented, by having a passenger airbag especially one that would include the A-pillar. The head injuries might also have been prevented by having a stronger structure to the front of the car which might have prevented the collapse of the passenger compartment A-pillar. The patient's injury was very severe and resulted in a vegetative state that will require persistent and continued custodial care.

The pre-hospital time for case #169 was 114 minutes and there were numerous factors involved in causing this prolonged time; none of which could necessarily have been reduced and part of this delay was attributed to an extended time required for extrication.

COLLISION SCHEMATIC
CASE 169

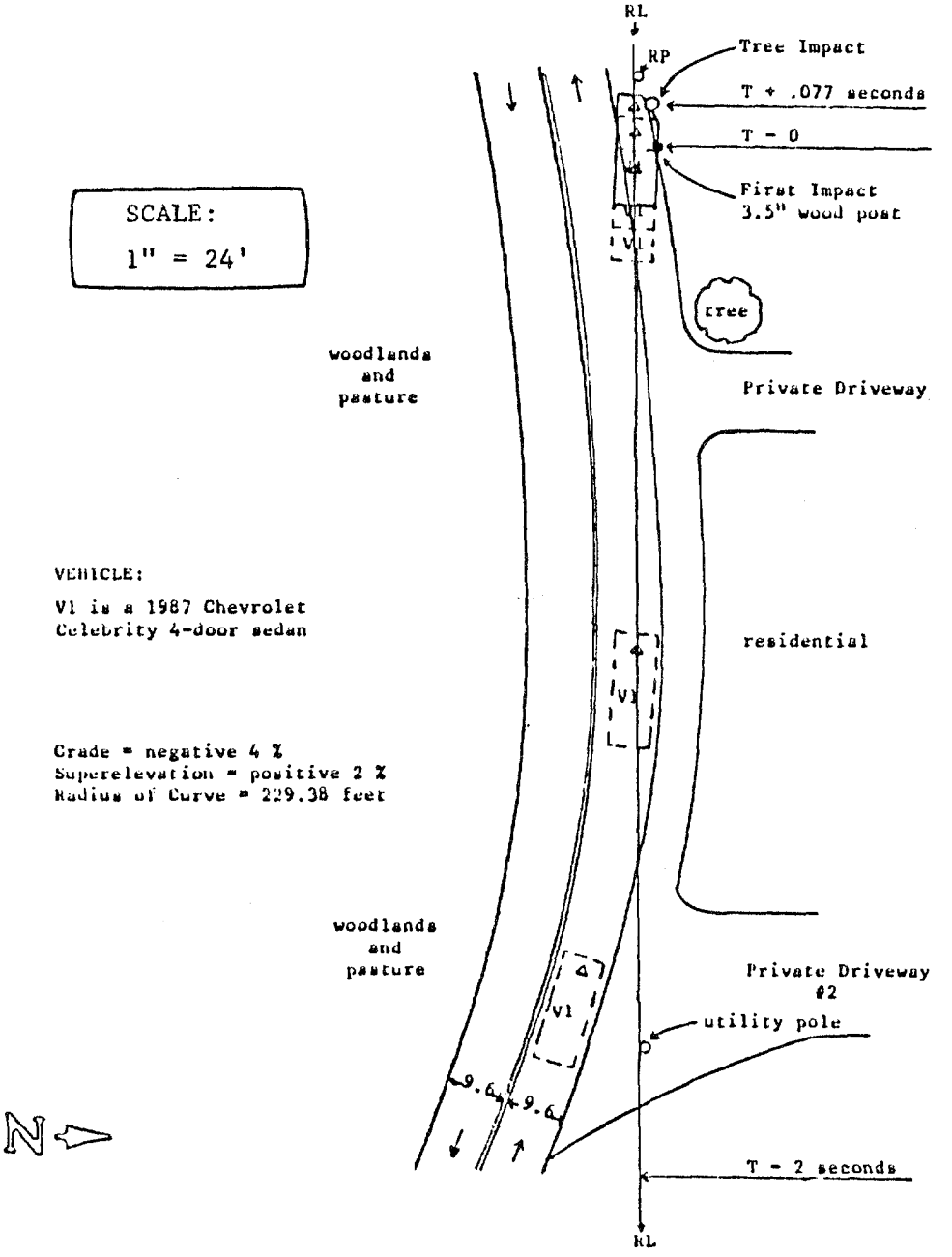

SELECTED PHOTOGRAPHS, CASE 169

1.

Scene. V1 direction of travel. Curve radius = 229 feet. Vertical alignment = negative 4 percent. Superelevation = positive 2 %.

2.



V1 (1987 Chevrolet Celebrity 4 door sedan). Frontal tree impact. Delta V= 52.7 m.p.h. Max crush= 59.4 inches. Roof altered; rescue

SELECTED PHOTOGRAPHS, CASE 169

3.



V1 exterior. Right "A" pillar/roof junction. Direct contact causing catastrophic longitudinal intrusion to RF seat position.

4.



Right front passenger position. Interior "A" pillar/roof junction (AIS-5, AIS-4, AIS-3 head). Passenger used lap and shoulder belt.

SELECTED PHOTOGRAPHS, CASE 169

5.

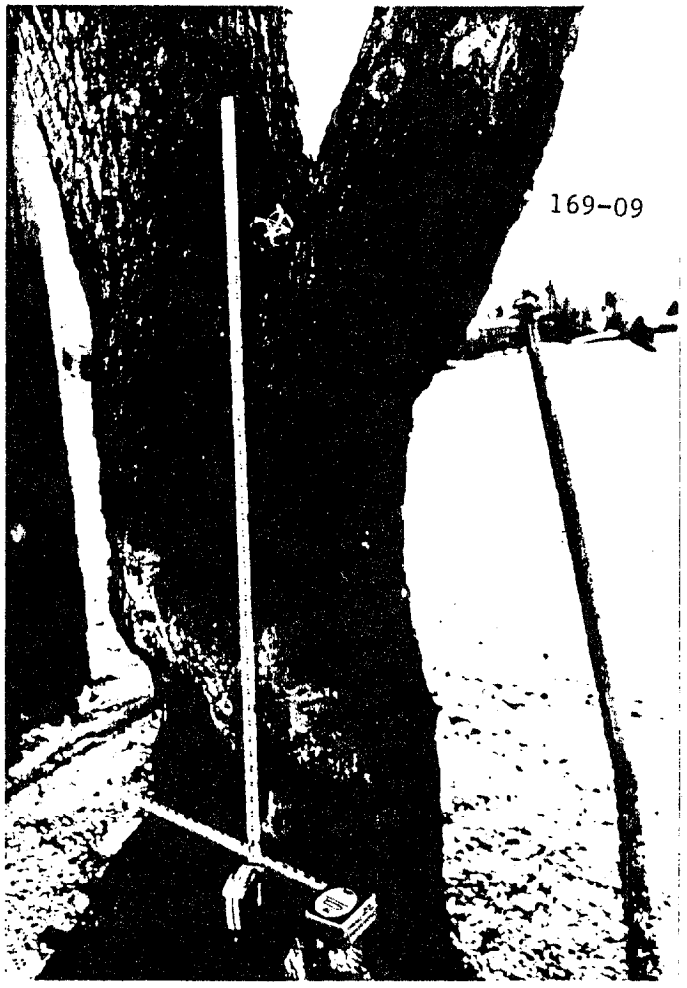

Object contacted. 24 inch diameter tree with protruding limb. Note abrasions to limb; right "A" pillar/ roof junction contact.

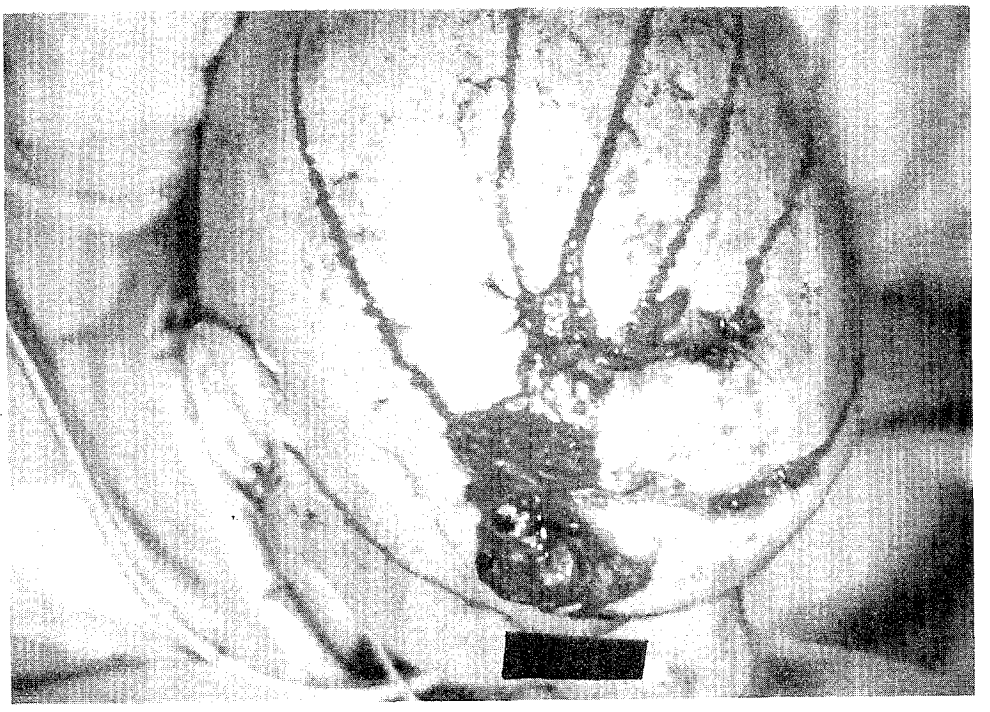

169A Preoperative photo of open right sided skull fracture with significant tissue avulsion.

Contact Point- A Pillar and Roof
Type of Crash- Frontal impact
Estimated Force of Impact- Windshield- 1400 lbs.

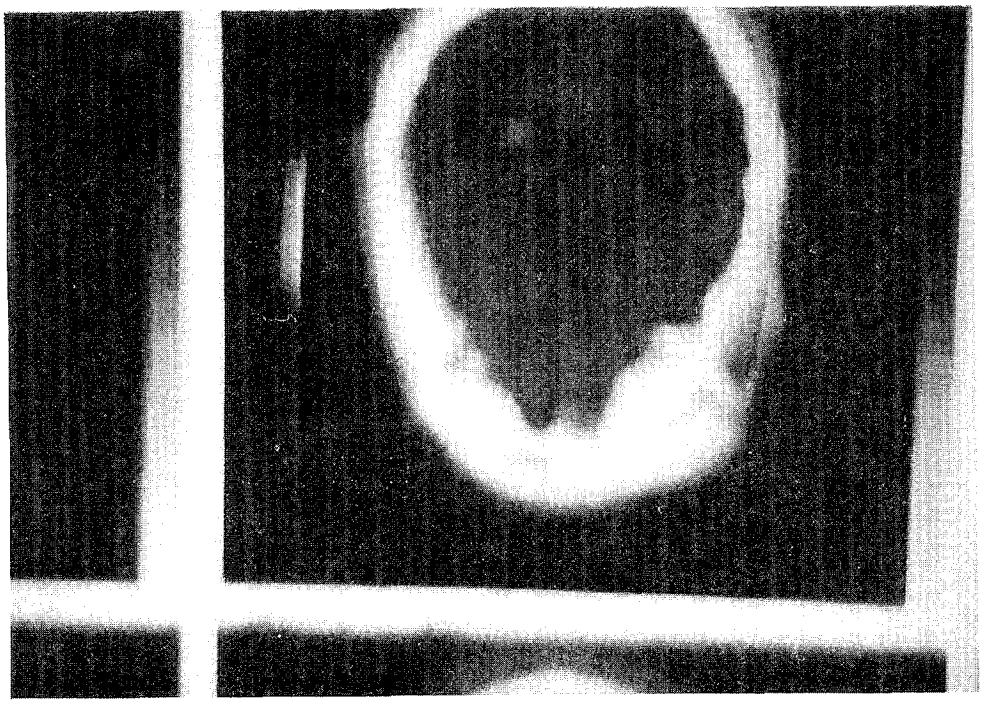

169B Head CT Scan reveals bilateral frontal lobe hematoma.

Contact Point- A Pillar and Roof
Type of Crash- Frontal impact

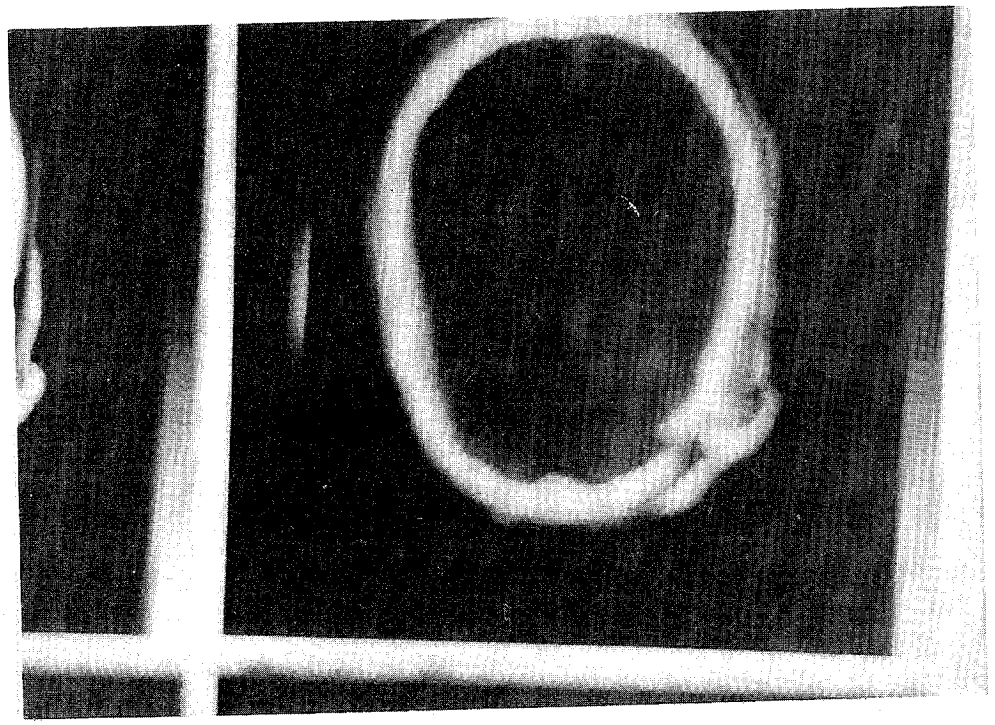

169C Head CT Scan reveals skull fracture.

Contact Point- A Pillar and Roof
Type of Crash- Frontal impact

SUMMARY - CASE 272 (009)

This two vehicle accident occurred on a rainy, winter, weekday morning. The collision involved a 1987 Hyundai Excel GL 4-door sedan with one 20 year old female occupant, and a 1973 Nova 2-door Coupe with a 78 year old male driver and a 79 year old female right rear passenger. The Hyundai was southbound on a 3 lane asphalt arterial street in a suburban area. The street was wet as it was raining, and the street had a posted speed limit of 40 miles per hour. There were 2 southbound lanes and one northbound lane. The Hyundai was in the inside southbound lane. The Chevrolet was traveling east from a private driveway and turning north onto the arterial street. The front bumper of the Chevrolet impacted the front bumper of the Hyundai. The driver of the Hyundai, our case occupant, was using the available 2-point automatic shoulder harness which did not prevent her from contacting the steering wheel and other front interior surfaces. The driver of the Chevrolet was reported as possibly injured. The right rear passenger in the Chevrolet was reportedly possibly injured and not using the available lap belt. The driver of the Hyundai was seriously injured and was transported to a trauma center for treatment. Injuries sustained by the driver of the Hyundai are listed below in OIC format:

BODY CONTACTS AND INJURIES TABLE-CASE 272
20 year old female; driver of 1987 Hyundai; frontal impact

OIC/AIS CODE	ICD-9	CONTACTS OR INJURIES	CONTACT POINT
1. 2HWKB2 041100	850.96	Unspecified loss of consciousness	Steering Rim
2. 2FRFS3 041100	801.0	Open fracture anterior wall right frontal sinus/ fracture medial wall right orbit	Steering Rim
3. 2FCLI2 041100	873.20	Nasal laceration (full thickness)	Steering Rim
4. 2CCCI1 411100	922.1	Chest contusion	Shoulder belt
5. 2MRLL4 162100	864.04	Large stellate interolateral right lobe liver laceration	Steering Rim Shoulder belt?
6. 2MRCI1 162100	911.0	Small Contusion upper right Abdomen	Steering Rim Shoulder belt?
Unknown if Injured		Abraded Plastic, Broken Left Front Glass	Roof Side Rail
No Injury		Deformed Plastic	Knee Bolster
No Injury		Deformed Plastic	Knee Bolster

PSYCHOSOCIAL TIMELINE - CASE 272

Initial Interview

The patient, a 20-year old-unmarried female, was the driver and sole occupant of a car involved in a two-car collision. The patient is a high school graduate, has completed two years of college, and started a new clerical job at T- 3 weeks. The patient also works part-time as a hotel front desk clerk. Although the patient is not medically insured by either employer, she remains covered through her father, who is a recent retiree. Living at home with her father and stepmother, the patient has 2 step-siblings, one of whom (15 years of age) lives with the family, and a 19-year-old who attends college. The patient's natural mother died 9 years ago. The patient also has a natural sibling, a brother aged 31, who does not live locally. The brother's pregnant wife and two-year-old child were killed in an MVA at T -3 months in a car of the same make as that driven by the study patient.

The patient describes herself as an average student with no significant history of medical or psychosocial problems. The patient admits to being a smoker, denies drug usage, and drinks alcohol occassionally (once every three months.) The patient states that she feels that she has had a hard time settling down, being more discouraged about life but hopeful to have a more solid future. She tends to put off major decisions and finds it difficult to verbalize feelings and share problems. She is not a "joiner" of groups and enjoys more solitary activities such as swimming and horseback riding. She feels close to her family and is in daily contact with them.

At this time, the patient's primary concern is returning to pre-functional status which includes concerns regarding facial scarring which may require plastic surgery revisions.

CRASH TIME LINE - CASE 272

T - 2 seconds: This was a 2 vehicle collision involving a 1987 Hyundai Excel GL 4-door sedan (V1), and a 1973 Chevrolet Nova 2-door coupe (V2). V1 was traveling south in the inside southbound lane of a three lane asphalt arterial street. The roadway in this area is asphalt and bordered on the west by an 8 inch high square top curb. The 2 southbound lanes are approximately 14 feet wide each and separated by a broken white line. There is a double yellow line separating southbound and northbound traffic and there is one northbound lane approximately 14 feet in width. The northbound lane is bordered on the east by a solid white line and there is a paved asphalt shoulder approximately 9.6 feet wide to the east of the solid white line.

This roadway is intersected from the west by a private driveway approximately 32 feet in width, however, the curb radius at the intersection gives the driveway a width of approximately 134 feet at the end of radius along the west road edge of the

arterial street. No defects or sight distance problems were noted, however there is a large sign at the northwest corner which could cause a sight problem for vehicles exiting the private driveway from a position behind (to the west of) the stop sign.

The collision occurred on a rainy weekday morning. The roadways were straight, level, and wet with an estimated coefficient of friction of .60. The arterial street had a posted speed limit of 40 miles per hour.

Just prior to impact, V2 was eastbound in the private drive and turning north into the path of V1. V2 was traveling an estimated speed of 12 to 15 miles per hour. V1 was southbound in the inside southbound lane and the driver of V1 applied the brakes at some point before collision. No skidmarks or road markings of any kind were noted at the scene. However, glass particles from the left front window of V1 were found on the road. V1's estimated speed at impact was 33 to 39 miles per hour.

T - 0: The left side front bumper of V2 impacted the right side front bumper of V1. The force acting on V1 was approximately 20 degrees clockwise from straight ahead. The driver of V1, a 20 year old female, was forced forward and slightly to the right at impact. The automatic 2-point shoulder harness was in use, but failed to contain the driver. Abrasions were found on the belt webbing which indicate that the belt lock mechanism did function properly at least initially. However, the driver of V1 either rotated out of the belt or the locking mechanism eventually failed to maintain its hold. Five impact related contact points were documented for the driver of V1. The upper steering wheel rim area was deformed approximately 2 inches from the driver's head. Her facial fractures and laceration correspond in location to the contour of the steering rim and to the direction of force. There was a gouge on the right side of the steering rim approximately 11 inches below the area of the head impact. This gouge could have been caused by jewelry on the right hand of the driver or by a component of clothing such as a button or zipper. There was a small contusion on the skin surface over the liver of the driver that would correspond to this steering rim gouge if a component of clothing were involved. There were two distinct knee impacts to the knee bolster below the left instrument panel. The knee bolster performed as designed and no injuries were documented from these contact points. There was an abraded left roof siderail which indicates that the head of the driver rebounded after impact and contacted the siderail and left front window glass. The glass disintegrated from the head impact.

Only one intrusion was noted to V1. The right toepan intruded longitudinally approximately 3.3 inches. The driver's left shoe was found to have a brake pedal imprint upon the sole. Maximum longitudinal crush to the front of V1 was measured at 14.1 inches, and the estimated speed change at impact for V1 was 19 to 23 miles per hour.

At impact, the front of V2 sustained a maximum longitudinal

crush of approximately 14 inches at the left front bumper corner. Estimated speed change at impact for V2 was 12 to 15 miles per hour. V2 rotated clockwise at impact while pushing V1 into a slight counterclockwise rotation. The front of V2 contacted the right side of V1 in a minor secondary impact. The driver of V2, a 78 year old male, was reported as wearing the lap belt portion of the available separate lap and shoulder belts. He was also reported as possibly injured. The right rear passenger, a 79 year old female was reportedly not using the available lap belt and was also reported as possibly injured. At the time of inspection, V2 was being removed from the tow yard and the interior could not be fully inspected.

T + 3 to 3.5 seconds: V1 came to rest facing southwest in the northbound traffic lane. The driver, after rebounding against the left siderail/window glass, was laying across the front passenger area with her head in the right front seat. She would be transported to a Trauma Hospital with serious injuries. V2 came to rest facing east, straddling the southbound traffic lanes.

T + 1 minute: Police were notified of the collision.

T + 8 minutes: Police arrived at the scene.

PREHOSPITAL AND HOSPITAL TIMELINE - CASE 272

T+ 3min.: Ambulance receives call to respond.

T+ 7min.: Ambulance arrives at scene. Initial field assessment reveals a blood pressure of 60/PALP, a heart rate of 60, a respiratory rate of 12, and a Glasgow Coma Score of 6. Prehospital care provided included administration of oxygen, administration of 1500 cc of colloid solution and application and inflation of the MAST suit.

T+36min.: Patient departs scene by paramedic staffed ground ambulance.

T+76min.: Patient arrives at MIEMSS/Shock Trauma. Initial physiological assessment of the patient reveals a blood pressure of 138/63, heart rate of 77, respiratory rate of 12 and a Glasgow Coma Score of 14. The patient's ISS (Injury Severity Score) was 34. Results of the toxicology screen were negative. Initial care included:

-Evaluation by a MIEMSS trauma team,

-Fluid resuscitation,

-Full diagnostic evaluation including x-rays of the cervical spine, chest and pelvis. In addition to the toxicology screen, an arterial blood gas, a CBC (complete blood count), an SMA-6 (rountine blood chemistry) and a UA (urinalysis) were performed.

-Diagnostic peritoneal lavage with grossly positive results,

Injuries noted include:

-Loss of consciousness,

-Right frontal sinus fracture (complex, open, anterior wall),

-Right forehead avulsion (with minor tissue loss),
-Nasal Laceration (superficial),
-Nasal Fracture (open),
-Right Orbital fracture (medial wall),
-Right upper anterior chest abrasion and hematoma,
-Right upper anterior abdominal abrasion and contusion,
-Midline lower anterior abdominal contusion,
-Right Lobar Liver injury (parenchymal fracture with hemorrhage >1000cc)

Operative care includes:
-Resection of Liver injury,
-Bone graft for Right orbital fracture,
-Frontal sinusotomy,
-Plastic surgery repair of nasal and forehead lacerations.

Nonoperative care includes:
-Closed reduction of nasal bone and septal fractures.

T+ 24hours-9days: Patient spends 5 days in intensive care unit and 4 days in the intermediate care unit. No complications were reported during this patient's acute care hospitalization.

T+9days: Patient discharged to home able to ambulate without assistance.

COGNITIVE-COMMUNICATIVE EVALUATION - CASE 272

The patient received a cognitive- communicative evaluation on T + 7 days. Auditory comprehension, written comprehension, oral expression, written expression, speech and cognition were within normal limits. The patient was functioning at an RLAS VIII- purposeful- appropriate response level (Rancho Los Amigos Score.) No treatment or follow-up was indicated. Hearing and swallowing skills appeared within normal limits.

CRASH COMPARISON - CASE 272

Crash Test Data:

Initial runs on the crash test data base did not yield very much in useful data. Finally, after several trials some second vehicle data in crash tests was found that produced similar damage profiles. These crash tests were #401 and #404.

Data used here for crash curve comparison was the rear deck and firewall curves and then only the "X" axis proved useful. No "Y" component was used.

Crash Test Curves:

The crash curves are shown at Figures 272-1 through 272-4. They show low G forces in action, averaging to 4 Gs or so at 60-80 milliseconds. The speed of the test vehicles was just about the same as the actual crash so the G forces in the actual case must have been pretty close to this.

Crash Test Injuries:

In the analysis of the injuries in the crash test, case 401 resulted in an HIC of only 27 and a CSI of 16. In this case the driver dummy was belted as in the actual case (but the belt apparently worked). In the #404 test, the occupant driver was also belted and an HIC of 48 and a CSI 28 was recorded. This level of injury certainly does not compare with the actual case.

Crash Significance:

Here is another case of severe injuries that are out of line with the conditions of the accident. The case victim was restrained but either she rotated out of the restraint because of the angle of impact or the restraint mechanism failed. Only 1% of restrained occupants are hospitalized as a result of their injuries. Also, while 21% of all crashes in urban areas at 30-40 MPH involve injuries of AIS 1 sverity, only 1% are of AIS 3 or greater.

The maximum intrusion in this case was 3-4 inches. This can not explain the severity of injury either. While 62% of crashes with a 2-4 inch intrusion cause injuries of AIS 1 or greater, only 4% of the time do they cause injuries of AIS 3 or more.

The fact that the steering wheel appeared to be the primary culprit in inflicting the worst injuries is no surprise. It is the single most frequent cause of severe injury (16%). As an interesting set of aside statistics, about 10% of all accidents involve a rain condition and only 2% involve entering a minor arterial from a driveway. This is apparently a low incidence accident with a set of coincidental occurrences accounting for its severity.

PSYCHOSOCIAL FOLLOW-UP - CASE 272

3 Months

The patient has returned to work full-time. The patient states that she is doing well and doing most of the things she did prior to her injury, although she tires more easily and lacks confidence, having more outbursts and feelings of frustration and anxiety. Facial scarring continues to be

troublesome to deal with and she describes social life as less satisfactory than it was prior to the injury. The patient also experiences flashbacks. She feels that she is coping appropriately with the help of her family.

6 Months

Following 9 days acute care hospitalization, this 21-year-old patient was discharged to home without rehabilitation. She returned to full-time work 1 month post-trauma. She is currently doing well and has returned to most of her pre-injury activities. Patient admits to tiring more easily and lacking confidence, with more outbursts and feelings of frustration. She has experienced some "flash-backs" but feel these have lessened over the months and she is coping appropriately with help of family. Facial scarring continues to be troublesome to deal with for patient.

1 Year

Patient continues to work full-time and has returned to pre-injury activities. Patient followed by plastic surgeon and further cosmetic procedures to nose anticipated. Patient continues to have some minor psychological residual stemming from crash coupled with other losses in her young life.

PREVENTION AND INJURY REDUCTION - CASE 272

This crash occurred primarily because of driver inattention, however, a potential problem was noted at the accident scene. There was a business sign (see crash team photograph #5) which could block the vision of eastbound traffic if the vehicle stopped behind the stop sign. It is a law in some areas that a vehicle must stop behind a stop sign before proceeding. After speaking with the local Traffic Engineering office, the team learned that locally, a vehicle is not required to stop behind a stop sign, but it must stop before crossing the road edge of opposing lanes. Sight obstruction has therefore been discounted as a causal factor because there was plenty of room for the vehicle to pull past the stop sign before entering opposing lanes.

With a frontal Delta V of about 20 miles per hour, one would not expect to see the serious injuries that our case sustained (AIS-4, AIS-3) while using the available restraints. While the restraint did not physically fail, it did fail to restrain the driver due to its design. Both front seat positions in this 1987 Hyundai Excel GL 4-door sedan are equipped with automatic 2 point shoulder belts only. There were no lap belts present in the front seat positions. Coupling this arrangement with a 1 O'clock principal direction of force caused the occupant to rotate out of the restraint. Therefore, the driver sustained injuries that one might expect from an unbelted driver. A local Hyundai Service Manager was contacted. He said that some early 1987 models were manufactured without lap belts in the front seat positions, but

that most of the 1987 models that were delivered did include manual lap belts in addition to the automatic 2 point shoulder belts. Our case's injuries would probably have been reduced had additional restraints been available.

---- Jerry Jackson

PREVENTION COMMENTS - CASE 272

This is a 20-year-old female who was belted and impacted the steering wheel with a resultant liver laceration. This injury would have been prevented with the use of an airbag to cushion the impact with the steering wheel.

At fault in the incident was an elderly driver who exited from a side street. Although, its unclear whether he was specifically impaired, there is a suggestion that perhaps with the dynamics of the event and the driver's age that there might have been some lack of quick response due to age. Perhaps more frequent review of elderly drivers would prevent such similar accidents.

The patient seemed to be hypotensive at the scene and there were approximately 29 minutes of field time. The patient's total blood loss, hypotension, and perhaps duration of hospital stay, could have been shortened if the pre-hospital time had been less.

In making a comparison of this patient's vehicle with other vehicles sustaining similar energy impacts, the amount of damage to this make of vehicle suggests that it is perhaps not as crash worthy as others. This requires further investigation.

COLLISION SCHEMATIC, CASE 272

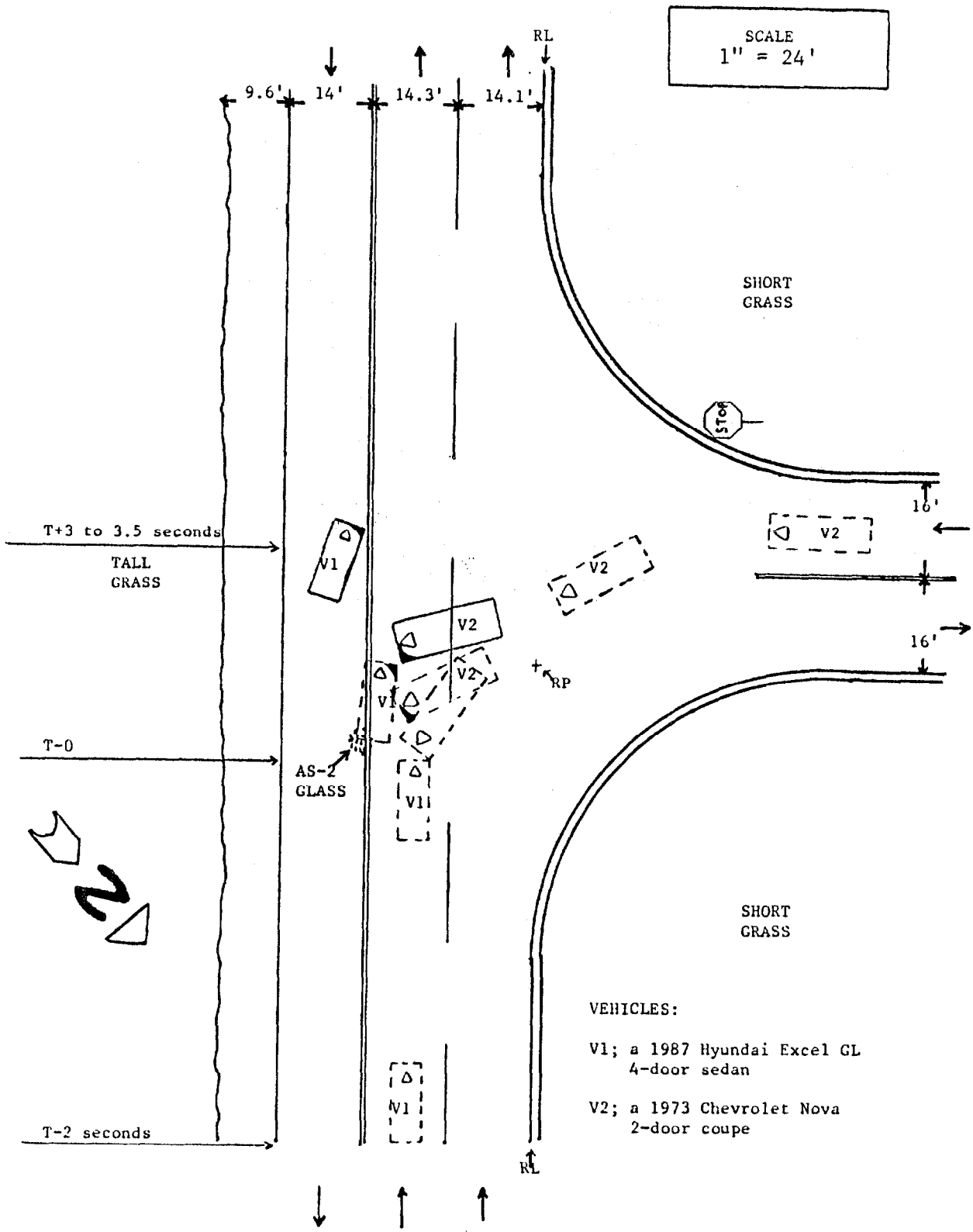

SELECTED PHOTOGRAPHS, CASE 272

1.

Scene. Intersection; Wet 3-lane arterial street/private driveway. V1 direction of travel. V2 came from the right.

2.



V1 (1987 Hyundai Excel GL 4 door sedan). Front impact. Max crush = 14.1 inches. Delta V = 19-23 m.p.h. Toepan intrusion 3.3 inches

SELECTED PHOTOGRAPHS, CASE 272

3.



V1 driver's seat. 2 point passive shoulder belt in use. Lap belt; not equipped. Steering rim (AIS-4,3,2,&1 head,face,chest,abdomen)

4.



V2 (1973 Chevrolet Nova 2 door). Front impact. Max crush = 14 inches. Delta V = 12-15 m.p.h. No intrusion.

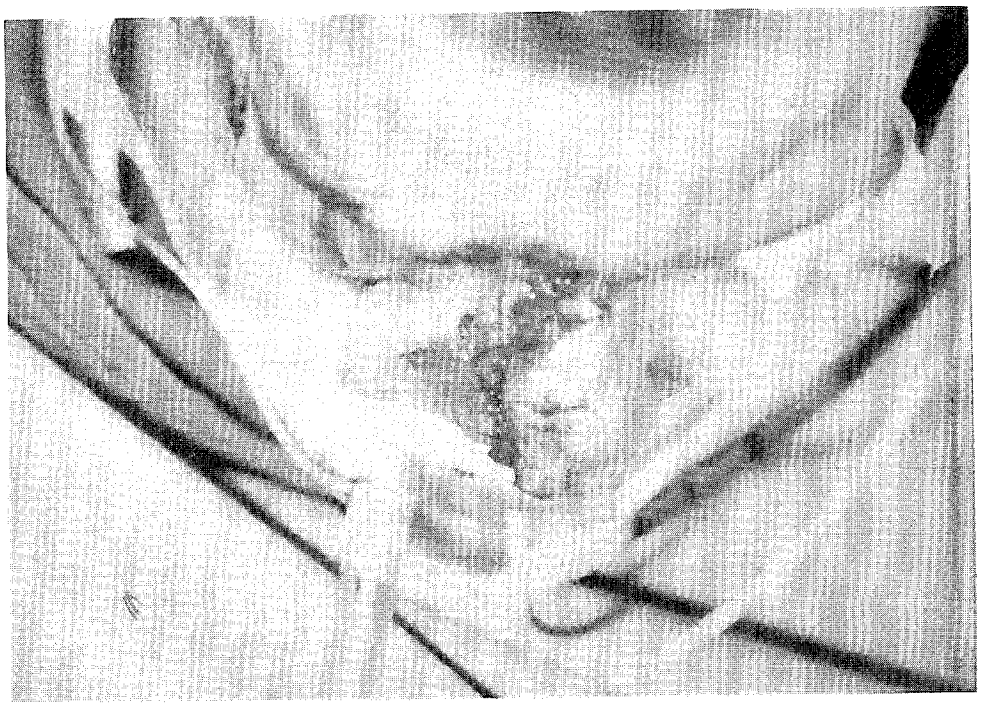

272A Full thickness nasal laceration and open nasal fracture (Looking from above.)

Contact Point- Steering wheel rim
Type of Crash- Frontal impact
Estimated Force of Impact with steering rim- 800 lbs.

272B Open frontal sinus fracture and full thickness nasal laceration.

Contact Point- Steering wheel rim
Type of Crash- Frontal impact
Estimated Force of Impact with steering rim- 800 lbs.

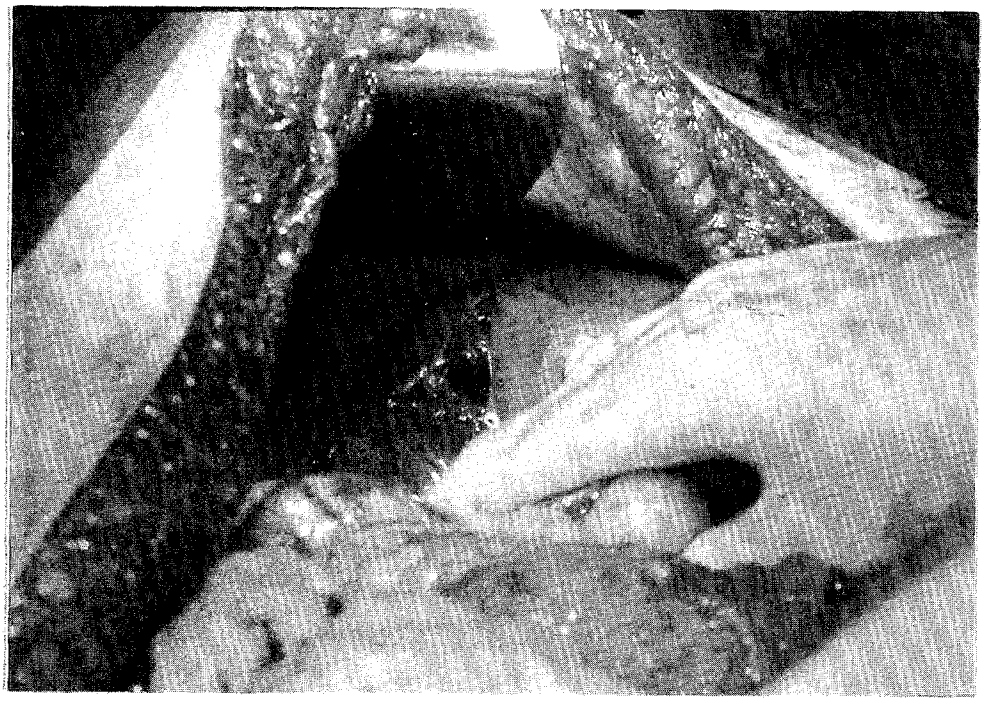

272C Operative photo revealing a large stellate laceration of the left lateral lobe of the liver.

Contact Point- Steering wheel rim/shoulder belt?
Type of Crash- Frontal impact
Estimated Force of Upper torso Impact with rim- 5201bs.

SUMMARY - CASE 052 (010)

This accident occurred in the early morning hours of a weekday in late winter. It involved a 1987 Honda Accord with two occupants impacting an embankment, traffic sign, utility pole and a boat trailer. The driver, while being pursued by the police, lost control of the vehicle as he exited a curve left, began a counterclockwise rotating skid, struck and rotated over a 2 foot high embankment. Vehicle #1 vaulted over a driveway snagging the undercarriage on a stump and began rotating towards the right side. The vehicle rotated 180 degrees (possible 1 1/2 roll-six quarter turns), struck a road sign 7 feet above ground level in the vicinity of the right front bumper. Vehicle #1 continued upside down and impacted a utility pole at the left front fender. The pole fractured into 3 pieces at impact. Vehicle #1 continued its counterclockwise rotation, struck the ground and became airborne again. At this point in the accident sequence, the ground was extremely muddy and the scene evidence masked. The total number of roll overs was unknown until the vehicle landed on its wheels prior to impact. No pre-crash braking evidence was noted. Both the driver and the front seat occupant were ejected as the vehicle continued rolling and rotating, striking a boat trailer 306' after leaving the road. Occupant contact points indicate the driver was ejected through the left front window which was probably broken during the rollovers. No indication was noted of the ejection medium of the passenger, however, it is possibly the side window, also. The driver was taken by land transportation to a major shock trauma unit and the passenger to a local hospital. Neither the driver nor the passenger was wearing the available 3 point shoulder/lap belts and the vehicle is not equipped with a passive restraint system.

BODY CONTACTS OR INJURIES TABLE-CASE 052
20 year old male, driver, 1987 Honda Accord, rollover/ejection

	OIC/AIS	CODE	ICD-9	CONTACTS OR INJURIES	SOURCE
1.	2HUFS2	543200	854.06	Closed Head Trauma w/loss of consciousness	Roof??
2.	2NPZV3	543200	805.06 805.07	Fracture, C6 & C7 Vertebra	Roof??
3.	2CUUU4	979700		Bilateral Hemo Pneumothoraces	Unknown
4.	2MUCK3	973100	866.02	Class III Renal Injury with Nonfunctioning Portions of Both Kidneys	Unknown
5.	2MLAI2	843100	879.2	Avulsion, Abdomen	Ground?
6.	2MLLI2	843100	879.2	Laceration, Abdomen	Ground?
7.	2LLFS3	843100	823.32	Open Fracture L/Fibula	Ground?
8.	2LLFS3	843100	823.32	Open Fracture L/Tibia	Ground?
	Unknown if Injured			Abraded, Melted Plastic	Upper

Unknown if Injured	Abraded Plastic	Left Door Panel Glove Box Door

PSYCHOSOCIAL TIMELINE - CASE 052

Initial Interview

The patient is a 20-year-old single male who was admitted with multiple trauma following a high-speed police chase in which he was the driver, under the influence of alcohol, and collided with a tree.

The patient is the third youngest in a family with seven children. The patient was adopted by his present stepmother and her first husband at the age of one, as were two other siblings, now ages 17 and 20. The patient's adoptive mother has been married for the past fifteen years to the patient's stepfather, who had four children at the time of marriage (now ages 25, 26, 33 and 42.) The parents have one natural son, 13 years of age.

The family describes the patient as a young man who has had difficulty with school and has exhibited acting-out behavior since age 11. The patient quit school during eleventh grade, after being suspended numerous times due to drug abuse. Since then, the patient has drifted from job to job in the construction field. At the time of injury, the patient was unemployed and lived with a friend in his apartment following the breakup of living arrangement with ex-girlfriend, who has a seven-month-old baby. The girlfriend is now pregnant with the patient's child and is currently living with her parents.

Although the patient has no steady income or permanent employment, his parents have not contributed to his support over the past two years. The patient has no health insurance coverage at this time and the family has applied on his behalf for medical assistance.

The mother reports that the son is outgoing and that he has a "hot temper" and is easily frustrated, with a pessimistic view of life. The family has felt, however, that the patient recently began to become concerned about his future, particularly when living with girlfiend. The mother indicates that the patient had an obsession with girlfriend, almost an addictive quality, and that the recent breakup has been devastating for him and partly the preciptating cause of accident. Apparently the girlfriend agreed to meet the patient who walked approximately four miles to meet her (the patient has neither a valid license nor a car) and she never showed up. After locating a friend and having gone drinking at a bar, the patient went to the girlfriend's house at approximately T - hours (0200 hrs). Her parents refused to let him in and called the police. The patient then broke into his former house in the same neighborhood

(his family had moved to a new neighborhood ~ T- 1 year ago), obtained car keys, stole a VCR and a car; police chase ensued.

Since the breakup with girlfriend, the family reports that the patient had been drinking heavily on a daily basis for the two months prior to the accident and had attended Alcoholics Anonymous meetings in the past as well as drug rehabilitation program for multi substance abuse (PCP, marijuana and cocaine.) After hospitailization at a private psychiatric hospital, the patient's drug usage declined, although he used these substances as a coping mechanism when depressed. The patient did make daily phone calls to mother and felt able to share his problems, but was alienated from his father. The patient had no contact with his birth mother. The mother indicates that the patient's siblings also have problems with alcohol abuse.

The mother describes the patient as one who does not want to be dependent on parents and as a young man who has never been interested in material goods. The patient enjoys music, is reportedly an excellent artist and talented enough to pursue art as a career.

The parents are hopeful that the patient will be able to view this present crisis as an opportunity to turn his life around, yet are realistic in acknowledging the long road ahead due to the extent of his paralysis (quadriplegia.) The patient has subsequently had one leg amputated due to complications. Although the patient has no sensation below the wrist, the parents are hopeful that he will regain use of his hands in order to pursue art, which did give him satisfaction prior to the injury.

CRASH TIME LINE - CASE 052

T -2.0 seconds: Vehicle 1, a 1987 Honda Accord 3 door sedan, being driven by a 20-year-old male, was eastbound on a rural 2 lane asphalt road at a speed estimated to be between 70 and 85 miles per hour. As the vehicle exited a left hand curve, the driver over controlled, and the vehicle began a counterclockwise rotating skid. The eastbound lane is 12.1 feet wide and is bordered by an 8.8 foot asphalt improved shoulder. The westbound lane is 10.6 feet wide and is bordered by a 9.7 foot asphalt improved shoulder. The coefficient of friction was estimated at .65, and the speed limit is 50 miles per hour. The left hand curve the driver had just departed has a radius of 1136.9 feet. At the estimated coefficient .65, the critical speed of this curve was computed as 105 miles per hour. Neither the driver, our case occupant, nor the passenger, an 18 year old male seated in the right front seat, was wearing the available lap/shoulder belt; both were ejected. The vehicle is not equipped with passive restraint devices.

T -0.4 to -0.5 seconds: The rear wheels of Vehicle 1, in a broadside counterclockwise skid, departed the south side of the roadway and mounted a two foot embankment.

T -0.2 to T -0.0 seconds: Vehicle 1 continued sliding with the rear wheels on the embankment and vaulting over a depressed driveway and on to the embankment east of the driveway. At a point 55.6 feet from roadway departure, the right rear wheel contacted a stump causing the vehicle to roll 4 quarter turns and contact the ground with the front tires for a distance of approximately 24 feet.

T +0.32 to +0.25 seconds: Vehicle 1 rotated an additional two quarter turns and the right front bumper contacted a road designating sign 7.4 feet above ground level while the vehicle remained inverted.

T +0.4 to T +0.5 seconds: Vehicle 1 continued eastbound inverted and struck a utility pole with the left front fender approximately 7.5 feet above ground level. At impact the pole fractured at ground level and again at approximately 8 feet above ground. Several small trees west of the pole impact showed strike marks and were broken at a height of 40 inches above ground and were carried and distributed by Vehicle 1 after the pole impact. Vehicle 1's speed at pole impact was computed at 56 - 73 miles per hour.

T +.07 to +.10 seconds: Vehicle 1 rotated approximately 45 degrees counterclockwise, continuing the rollover configuration and struck the ground in the vicinity of left rear "C" pillar and hatch door. This impact and its resulting deformation caused the hatch to open. The departure velocity was estimated at between 51 and 76 feet per second (35 - 52 mph).

T +1.97 to +4.1 seconds (estimated): Vehicle 1 continued rolling and rotating counterclockwise an undetermined number of times. During this sequence, the driver was ejected 219.2 feet from the point Vehicle 1 departed the road edge and the passenger ejected 344.8 feet from road edge departure. Due to extremely muddy conditions, the exact vehicle dynamics were masked until the Vehicle reached a point 250.6 feet from road edge departure. At this point definite counterclockwise rotating skidmarks once again became visible.

T +2.6 to +4.4 seconds: Vehicle 1 struck a boat and trailer driving the trailer from under the boat. The vehicle came to rest at a point 325.3 feet from road edge departure. This impact speed was estimated at 10 - 15 mph.

T +7.6 to +9.4 seconds: The police arrived on the scene and started investigative and medical relief efforts. (Vehicle 1 was being pursued by the police at the time of the accident.)

PREHOSPITAL AND HOSPITAL TIMELINE - CASE 052

T+ 1min: Ambulance receives call to respond.
T+ 7min: Ambulance arrives at scene. Initial field

assessment reveals a blood pressure of 70/40, a heart rate of 132, a respiratory rate of 16, and a Glascow Coma Score of 8. The patient had no Glasgow-type motor response but was fully conscious and his eyes were reactive to light (PERL). Prehospital care includes includes fluid resuscitation through bilateral I.V. lines with the administration of 1200cc of crystalloid. Additional prehospital care includes the splinting of extremities, spinal immobilization, administration of oxygen, application and inflation of the MAST suit and the monitoring of vital signs. The patient was found to have been ejected from the vehicle.

T+ 54min: Patient departs scene for MIEMSS/Shock Trauma by police medevac helicopter. (MIEMSS/Shock Trauma is the designated statewide neurotrauma receiving facility and referral center.) The Glasgow Coma Score onboard the helicopter was reported as 14 with a note that the patient had no sensation/feeling below the nipple line.

T+ 59min: Patient arrives at MIEMSS. Initial physiologic assessment of the patient reveals a Glasgow Coma Score of 15. The patient's ISS (Injury Severity Score) = 59. Toxicology screen results were positive for alcohol.

Initial hospital care provided includes:

- Evaluation by a MIEMSS trauma team,
- Fluid resuscitation,
- Full diagnostic evaluation including x-rays of the cervical spine, chest and pelvis. In addition to the toxicology screen, an arterial blood gas, a CBC (complete blood gas), an SMA-6 (routine blood chemistry) and a UA (urinalysis) were performed.
- Diagnostic peritoneal lavage with positive results,
- Application of traction to the cervical spine injury.

Initial clinical findings included the following:

- Fractures of the cervical spine (C6 and C7 bodies, facets and lamina) with quadriplegia,
- Closed head trauma with loss of consciousness,
- Bilateral hemopneumothoraces,
- Left lower abdominal laceration and avulsion with tissue loss
- Bilateral Class III Renal injury with bilateral hematomas and nonfunctioning portions of both kidneys.
- Open Grade III Left Tibia- Fibula fractures (Lower 1/3 transverse left tibia fracture and transverse left fibular fracture)
- Injury to the left posterior tibial artery (Hemorrhage and Ischemia),

Operative care includes the following:

- Insertion of bilateral chest tubes for evacuation and decompression of the bilateral hemopneumothoraces,
- Application of a Hoffman External fixation device for the left lower leg fractures and the irrigation and debridement of the wound.
- Ligation of the posterior tibial artery injury

Nonoperative care includes:

-Placement on a Stryker Frame.

T+24hours - 49days: Patient spends 24 days in critical care, 18 days in the neurotrauma intensive care and 7 days in intermediate care. Complications of the left posterior tibial artery injury include compartment syndrome necessitating the performance of fasciotomies. Due to left tibial bone necrosis, a below the knee amputation of the lower leg was later performed.

T+ 49days: Patient discharged from MIEMSS to an out-of-state inpatient rehabilitation facility with almost total paralysis of the upper extremities and complete paralysis of the lower extremities.

COGNITIVE-COMMUNICATIVE ASSESSMENT NARRATIVE - CASE 052

The patient's cognitive- communicative abilities were initially assessed on T + 30 days. He was exhibiting an upper extremity paresis at the time. He had also been recently extubated and was hoarse. The patient's auditory comprhension and written comprehension skills appeared within normal limits. Oral expressive skills were mildly decreased in the area of word fluency. Written expression skills could not be assessed due to paresis. The patient's speech skills were also reduced due to hoarseness post-intubation. His cognitive abilities were grossly within normal limits. It was felt that he was at an RLAS VIII purposeful- appropriate response level (Rancho Los Amigos Score.) No cognitive-communicative treatment was recommended. The patient failed a hearing screening. As the patient was NPO, or unable to be administered anything by mouth, a swallowing test could not be administered.

Due to the mild deficits noted during the initial assessment, the patient was given a discharge evaluation on T + 55 days. Auditory comprehension, written comprehension, oral expression and cognition skills all tested within normal limits. Written expression skills could not be assessed due to paresis. Speech skills continued to be reduced due to persistent hoarseness. The patient continued to be at an RLAS VIII level. Since the patient was being discharged to an inpatient rhabilitation center, it was recommended that his cognitive-communicative skills be re-evaluated there and treated if indicated. Hearing was re-evaluated and found to be within normal limits. The patient was on a P.O., or oral, diet. Follow-up evaluation is indicated for 3 months post-discharge.

PSYCHOSOCIAL FOLLOW-UP - CASE 052

3 Months

At T + 3 Months, the patient remains hospitalized at an in-state rehabilitation facility. The patient has spent a trial weekend at home with his family. The patient receives SSI and

medical assistance at this time.

The patient had the cervical halo removed at three months and wore a collar for ten days; however, after a fall during recreational therapy, the patient sustained possible nerve damage resulting in some vision problems.

The patient is becoming wheelchair-independent and can almost transfer himself independently, and is now learning bowel training and self-catheterization. He is highly motivated to pusue therapy and works hard at it. He is expected to remain at the rehabilitation facility for approximately 1-2 months and is making plans to enter a vocational rehabilitation center.

The patient is also working on completing his GED and is doing well. He is painting ceramics and giving thought to the future. His girlfriend has remained supportive and is pregnant with the patient's child. The patient is very positive and looking forward to parenting. The patient appears "quick-witted" and , although depressed at times-particularly over architectural barriers, he bounces back. The patient has not used alcohol or drugs since the injury and both the patient and family place more emphasis on religion and opportunity to begin life anew.

6 Months

Patient remained in acute care 53 days and was discharged to inpatient rehabilitation facility where he remained 3 months, becoming wheelchair independent and learning bladder and bowel control. At 6 months patient is living at home with mother and step-father but having great difficulty dealing with anger and coping with paralysis. Patient's girlfriend had baby boy. However, mother and child returned to her parental home to live. Patient has exhibited great dependency on girlfriend and has been extremely demanding on her and mother. Although mother has attempted to set limits on patient's behavior, further psychiatric intervention is indicated. Family may also benefit by Al-anon support and "tough love" psychotherapy. Although it is expected that patient would need to deal with his anger and that his verbal abuse and need for control would be evidenced after discharge from rehabilitation, past personality and addictive behavior patterns would seem to continue. Yet he is attempting to turn his life around in several ways. On the positive side, patient has continued to work on GED, has not returned to drinking or drug use. Patient is "quick-witted" and able to bounce back from depressive episodes. Rehabilitation referral to be made to vocation facility for further evaluation, testing and vocational counseling. Family and patient to participate in psychological therapy.

1 Year

At 7 months post-trauma patient entered Maryland Rehabilitation Center where he remains at 1 year, increasing his activities of daily life for independent living and beginning to evaluate vocational goals. Patient anticipates being at Maryland Rehabilitation Center another 4 months. He is no longer on any

medications, generally has positive life attitude, good sense of humor and pursuing computer drafting training. Family giving thought to moving and having home built that will be more accessible for patient. Patient did complete his high school degree while at rehabilitation and remains drug free with no use of alcohol. Patient continues to receive Social Security Insurance benefits. Patient is 80% independent.

2 Years

Patient lives at home with parents in newly built wheelchair accessible home. He is fully independent in all activities of daily life. Patient plans to return to Maryland Rehabilitation Center for 1 year for vocational course in computers and job placement.

CRASH AND INJURY PREVENTION IDEAS - CASE 052

This single vehicle rollover accident could have been prevented by an electronic speed sensor coupled with an electronic "smart highway" system. The car's compartment integrity remained basically intact. The installation of air cushion restraint systems and automatic seat belts would have kept the two ejected occupants within the car and probably greatly reduced their injuries. The installation of a speed governor for younger drivers would also reduce the speeds available for trying to outrun a police patrol car.

PREVENTION COMMENTS - CASE 052

This patient is a 20-year-old single male with a previous history of both alcoholism and drug abuse who was the driver in a high speed automobile crash. He sustained a C6-C7 vertebral fracture with quadriplegia; although he has some limited motion of the upper extremities, there is no sensation below the wrist bilaterally.

With regard to prevention issues-the patient appears to have had his head and spinal cord injury due to contact with the roof. He also sustained injuries, due to being ejected, to his abdomen and lower extremity which resulted eventually in an amputation of his left lower leg. There are many issues related to his unresolved problems with alcohol and drug abuse in spite of frequent counseling which clearly were major etiologic factors behind the accident.

Some kind of positive alcohol breath test control on the automobile ignition would have prevented this young man from driving his car. A mandatory seatbelt would have prevented him from leaving the car and an airbag might possibly have prevented the head injury, but this is unlikely since the car rotated. However, an adequate seatbelt might have kept him from striking the roof and certainly better padding on the roof might have

prevented the degree of cervical spine loading that produced the spine fracture/spinal cord transection and the head injury that the patient sustained.

The unexplained question here is why there were 47 minutes of ground time between the time the ambulance arrived and the patient was dispatched by the helicopter. This delay procedures may possibly have contributed slightly to his outcome if hypotension played a role in making his spinal cord injury more severe.

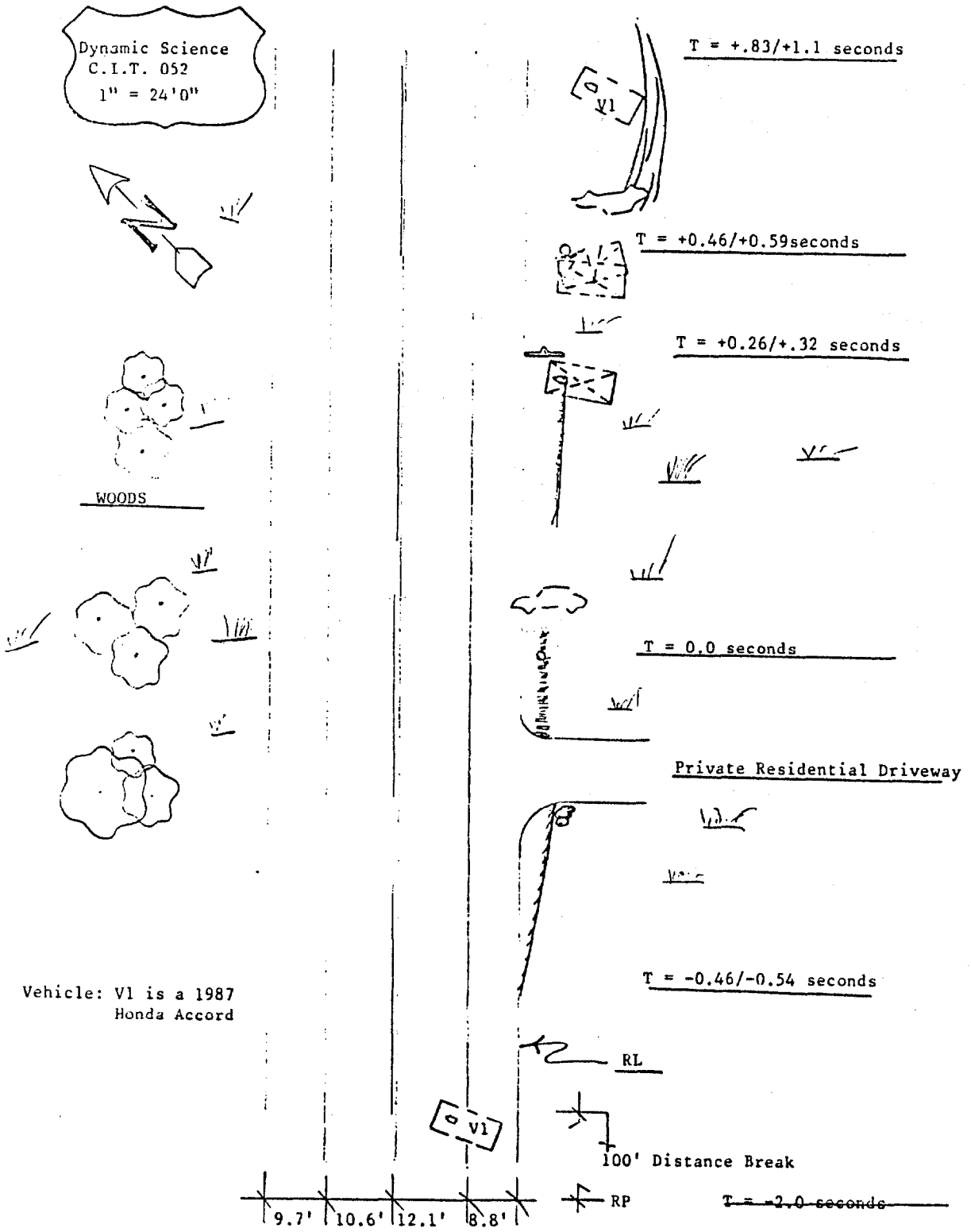

NOTE: VEHICLE 1 EXITED A LEFT HAND CURVE IN A COUNTERCLOCKWISE SKID [4]

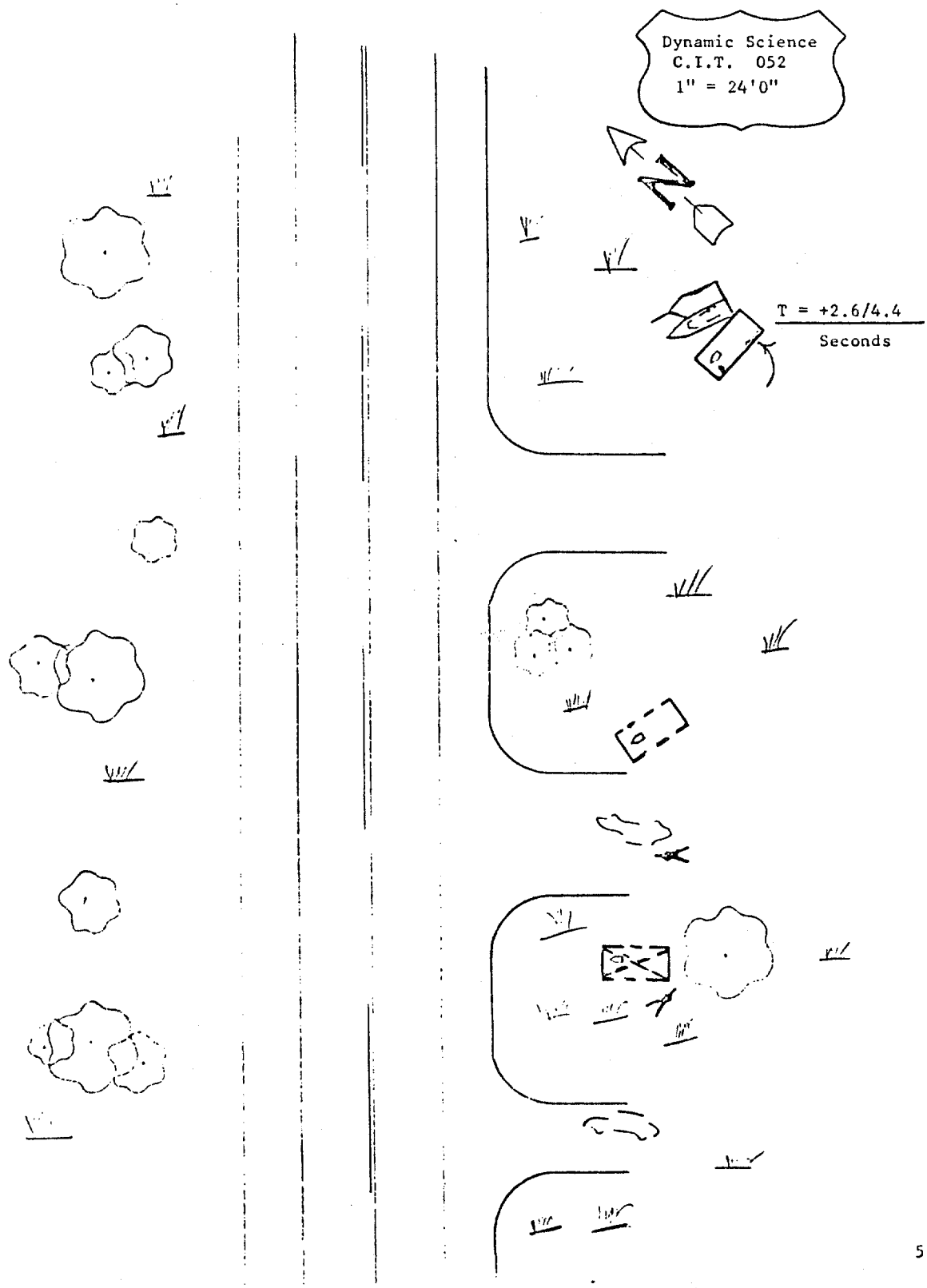
Dynamic Science
C.I.T. 052
1" = 24'0"
N
T = +2.6/4.4
Seconds

SELECTED PHOTOGRAPHS, CASE 052

1.

Scene. Vehicle 1's direction of travel just prior to the start of a counterclockwise skid.

2.

Scene photograph shows points of impact: embankment, telephone pole, and boat and its trailer.

SELECTED PHOTOGRAPHS, CASE 052

3.

V1; 1987 Honda Accord 3 door sedan. Multiple impacts w/fixed objects. Intrusion = 2.1" at left rear side panel.

4.



Max crush = 20.0" at left front bumper. Multiple rollovers and loss of contact with ground (vegetation shearing above ground level).

SELECTED PHOTOGRAPHS, CASE 052

5.



Right front seat occupant sustained a bilateral hemo pneumothoraces (AIS-4) when an unknown contact point was struck. Additional incapacitating injuries were sustained by the case occupant.

SELECTED PHOTOGRAPHS, CASE 486

5.

V3 (1984 Chevrolet Cavalier); sustained 44" direct and induced damage with a maximum crush of 19.25" at C6-right front bumper.

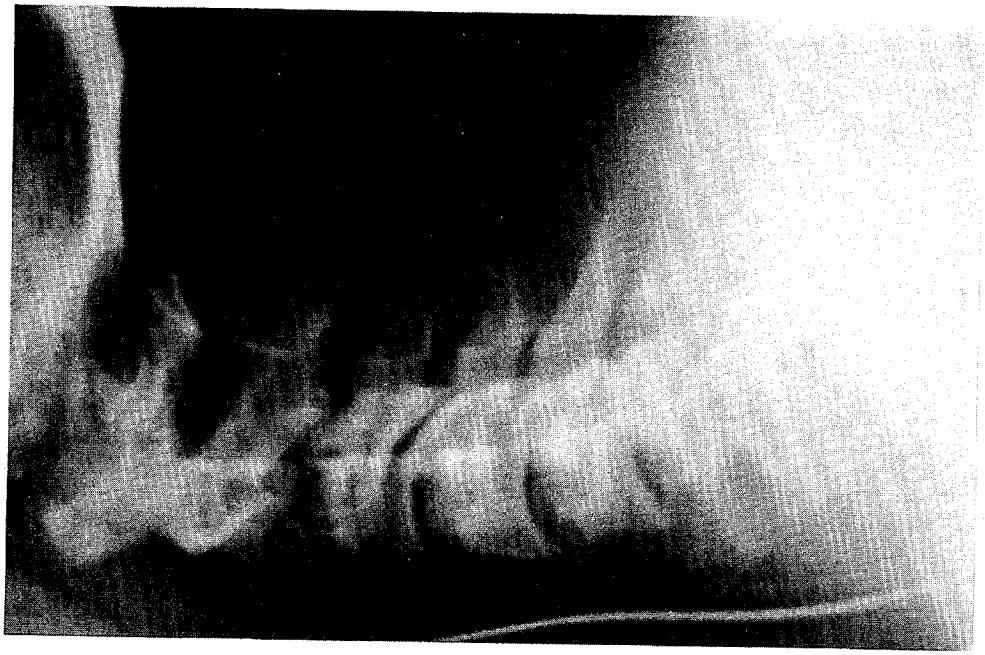

052A X-Ray revealing fractures of the vertebral bodies of cervical spine 6 and 7. This occured with a combination of axial loading and hyperflexion.

Contact Point- Roof??
Type of Crash- Rollover with occupant ejection

052B Abrasions and avulsion of the left lower quadrant of the abdomen.

Contact Point- Ground Contact?
Type of Crash- Rollover with occupant ejection

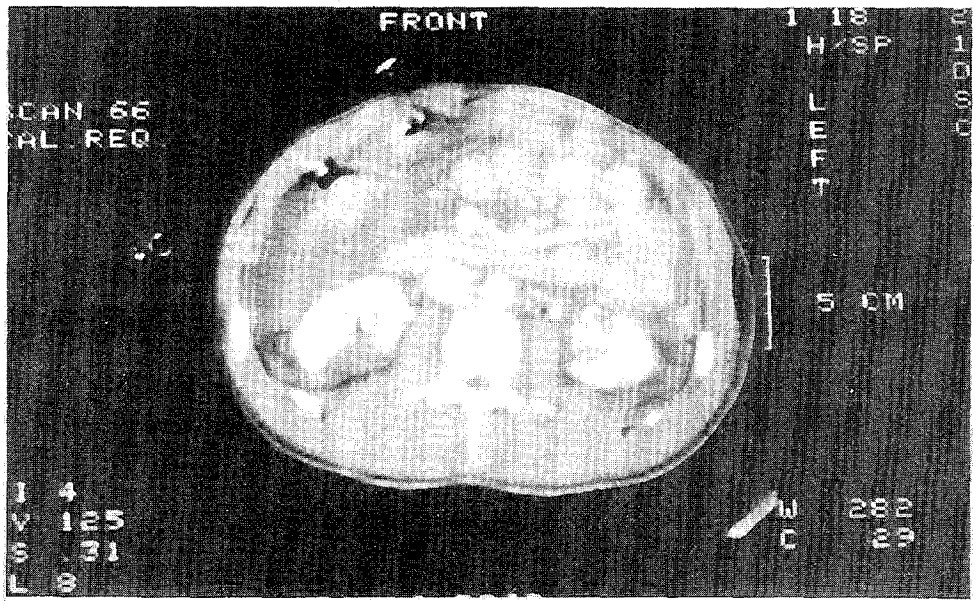

052C Abdominal CT Scan revealing a Class III bilateral renal injury, worse in the right with a perinephric hematoma. The dark areas of the kidney are devascularized.

Contact Point- Unknown
Type of Crash- Rollover with occupant ejection

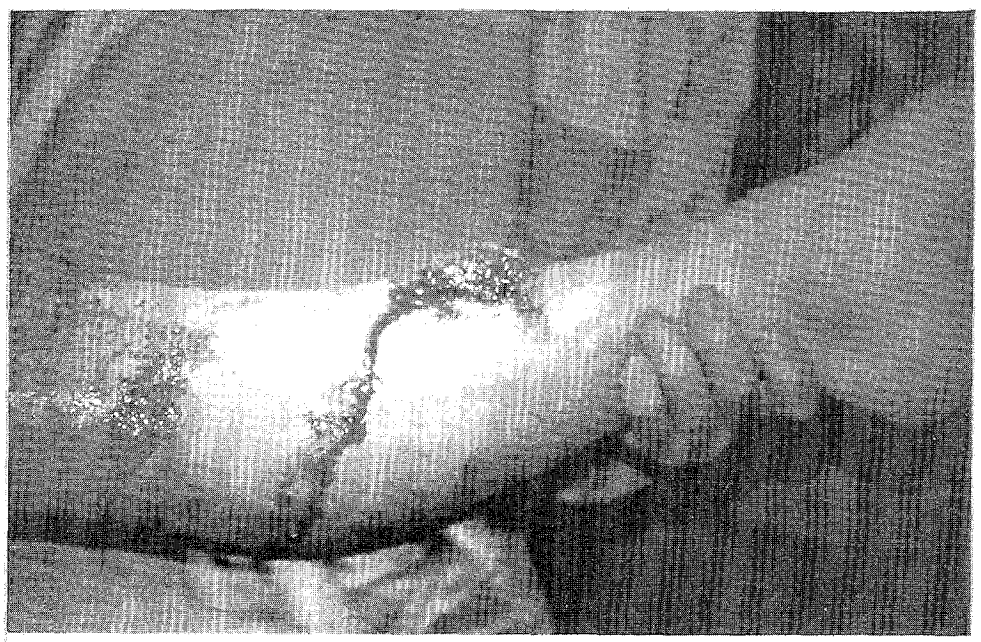

052D Open fracture of the lower 1/3 left tibia and fibula.

Contact Point- Ground contact?
Type of Crash- Rollover with occupant ejection

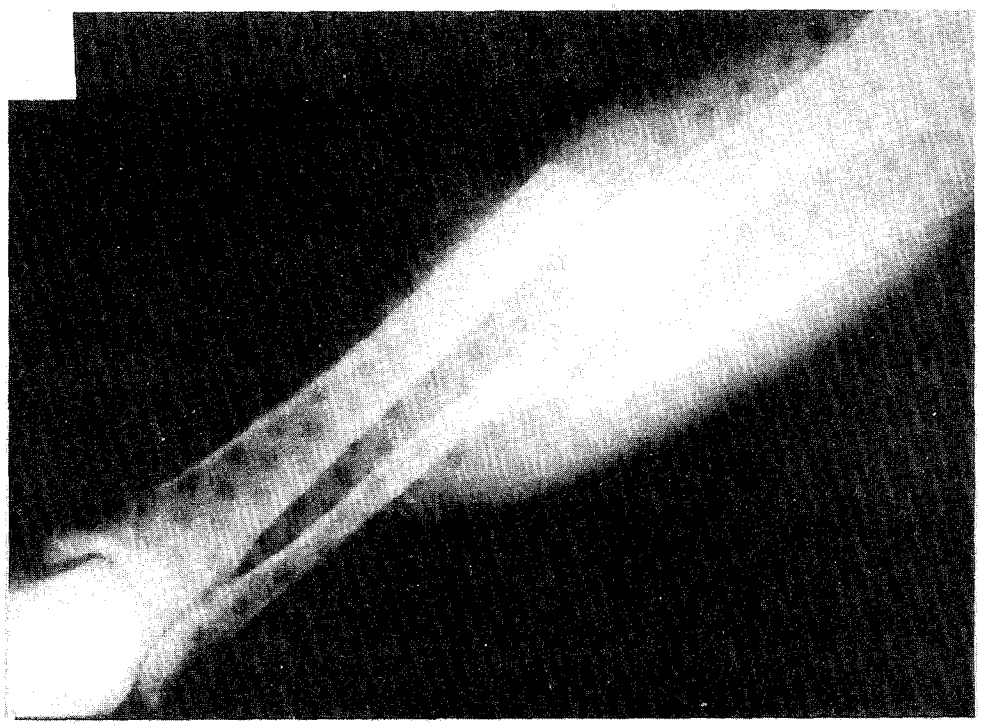

052E X-Ray revealing open, lower 1/3, transverse fractures of the left tibia and fibula. The transverse nature of this fracture suggests a direct blow without the action of axial or rotational forces.

Contact Point- Ground contact?
Type of Crash- Rollover with occupant ejection

SUMMARY - CASE 038 (011)

This 3 vehicle accident occurred on a clear, spring, weekday afternoon. The accident involved a 1987 Chevrolet S-10 Blazer 4x4 with one 40 year old male occupant, a 1985 Pontiac Bonneville 4-door sedan with one 67 year old male occupant, and a 1987 Chrysler New Yorker 4-door sedan with one 24 year old female occupant. The roadway is a major asphalt interstate highway which has 3 southbound lanes which are separated from 3 northbound lanes by a 34 foot wide grass median. The Chevrolet Blazer was southbound in the middle southbound lane. The Chrysler New Yorker was northbound in the middle northbound lane. The Pontiac Bonneville was northbound on the right northbound shoulder and sideswiped a steel guardrail. The Pontiac was deflected and probably steered across the outside northbound lane. The Pontiac's front bumper then contacted the right rear of the Chrysler. The Pontiac continued in a northwesterly direction and crossed the inside northbound lane, the grass median, and the inside southbound lane with no driver input. The front of the Pontiac contacted the front of the Chevrolet in the middle southbound lane. Both vehicles came to rest near the impact point after roughly 120 degrees of clockwise rotation. The Pontiac had approximately 64 inches of maximum longitudinal crush to the right front bumper corner. The driver of the Pontiac, who was not using the available active lap and shoulder belt, sustained fatal injuries upon impact. The Chevrolet had approximately 53 inches of maximum longitudinal crush to the right front bumper corner. The driver of the Chevrolet, who was using the available active lap and shoulder belt, sustained several AIS-2 lower extremity injuries. Both the Pontiac and the Chevrolet were severely damaged and towed from the scene. The Chrysler was not towed as a result of damage and could not be inspected due to pending litigation. A complete list of injuries for this case is listed below in OIC format:

BODY CONTACTS AND INJURIES TABLE-CASE 038
40-year-old male; driver of 1987 Chevrolet Blazer; frontal impact

OIC/AIS CODE	ICD-9	BODY CONTACTS AND INJURIES	CONTACT POINT
2HWKB2 042105	854.06	Closed Head Injury, Loss of Consciousness	Steering Wheel Rim?
2FRLO1 912300	870.0	Laceration < 5cm. Right Eyelid	Flying Glass?
2FLLO1 912300	870.0	Laceration < 5cm. Left Eyelid	Flying Glass?
2HLLE1 912300	872.01	Laceration < 5cm. auricle Left Ear	Flying Glass?
2FILI1 912300	873.43	Superficial laceration Lower Lip	Flying Glass?
2CLAI1 412100	911.0	Abrasion Lower Left Anterior Chest	Shoulder Belt?
2WRAI1 101104	914.0	Abrasion Right Hand	Instrument

				Panel
2WULI1	999799	883.0	Laceration 2nd Metacarpal Superficial	Unknown
2WULI1	999799	883.0	Laceration 3rd Metacarpal Superficial	Unknown
2LLFS2	561108	823.82	Fracture Left Tibia, Obliq. Distal Articular Surface	Toe Pan
2LLFS2	561108	823.82	Fracture Left Fibula Obliq. Distal Articular Surface	Toe Pan
2QLFS2	561108	824.4	Left Bi-malleolar Ankle Fracture	Toe Pan
2QRFS2	561108	825.0	Multiple Right Calcaneus Fractures	Toe Pan
2QRFS2	561108	825.21	Fracture Right Talus Proximal Articular Surface	Toe Pan

PSYCHOSOCIAL TIMELINE - CASE 038

Initial Interview

The patient, a 40-year-old male, was admitted to MIEMSS Shock Trauma with multiple trauma following an MVA on a major highway. The patient was the single occupant and seatbelted driver of a car which was struck by a vehicle, driven by a 67-year-old male, which supposedly crossed over the highway's center line. The driver of the other vehicle (the 67 year old male) apparently suffered a heart attack while at the wheel and was pronounced dead on arrival.

The study patient is the youngest of two children, has an older sister, and describes his nuclear family as close-knit, seeing parents and married sibling frequently. The patient's parents are retired, financially stable with the father participating in the study patient's business part-time.

The patient is in his second marriage, and for the past sixteen years has been living with his wife and two sons, ages 15 and 7, in a semirural area. The patient's property is described as being small acreage containing livestock. The patient is the owner and president of a company he established 3 years ago. Although his primary occupation is that of a master plumber, the patient operates a mechanical contracting business with five employees and does most of the related administrative work at home. The patient has major medical insurance coverage through a private commercial insurance carrier and adequate disability insurance. The patient's wife is a partner in the business and ia able to manage workload during husband's hospitalization. The patient reports increased financial status and business success since the initiation of the firm.

The patient denies any trauma, hospitalization, medical or psychological conditions prior to the injury. The patient admits to being a smoker who is attempting to quit during this hospitalization. He denies use of drugs and uses alcohol

rarely. He describes self as an independent motivated person, a rational-decision maker satisfied with life, and one who is calm and easy-going. The patient is verbal, friendly and outgoing, although he prefers to be alone and tends to work through problems on his own. He will share serious problems with wife. The patient and wife both describe marital relationship as harmonious and close.

The patient has a valid driver's license with no history of driving while intoxicated. The patient also holds a valid motorcycle license and is an advocate of seatbelt and helmet usage. The patient has never taken a driver's education course.

CRASH TIMELINE - CASE 038

T - 10 seconds: This was a 3 vehicle accident which occurred on a clear weekday afternoon. The accident involved a 1987 Chevrolet S-10 Blazer (V1) with one 40 year old male occupant, a 1985 Pontiac Bonneville 4-door sedan (V2) with one 67 year old male occupant, and a 1987 Chrysler New Yorker 4-door sedan (V3) with one 24 year old female occupant. The roadway is a major interstate highway in central Maryland. It is of asphalt construction and was dry and free of defects at the time of the accident. The roadway has 3 southbound lanes which are separated from 3 northbound lanes by a 34 foot wide grass median. Each of the 6 travel lanes is approximately 12 feet wide. The southbound lanes are bordered on each side by a 10 foot wide paved shoulder. The shoulders are delineated from the lanes by a solid white line to the outside and a solid yellow line to the inside. The 3 travel lanes are separated by broken white lines. The northbound lanes and shoulders are marked the same as the southbound lanes and shoulders. There is a positive 2 percent slope for northbound traffic and a negative 2 percent slope for southbound traffic. The posted speed limit is 55 miles per hour. V1 was southbound in the middle southbound lane traveling at an estimated speed of between 54 and 60 miles per hour. V3 was northbound in the middle northbound lane. The speed of V3 could not be accurately estimated, and the driver of V3 refused comment due to pending litigation. V2 was northbound on the right northbound shoulder and approaching a metal guardrail at an estimated speed of between 50 and 65 miles per hour.

T - 3.8 to 4.9 seconds: The right side of V2 contacted a metal guardrail in a sideswipe configuration. Upon inspection of V2, it was noted that there was guardrail contact to the entire right side of V2 at the level of maximum side extension. The damage pattern was very shallow and consisted mainly of surface scratches. No measurable deformation was noted as a result of this impact. At this point, the driver of V2 steered to the left, crossed the outside northbound lane, and entered the middle northbound lane.

T - 3.4 to 4.4 seconds: The front of V2 contacted the right rear of V3 in the middle northbound lane. The extent of damage

to the vehicles from this impact is unknown, however, V3 was not towed due to damage, and V2 was still traveling at an estimated speed of between 50 and 65 miles per hour after this impact and without driver input or disabling vehicle damage. V2 continued in a northwesterly direction crossing the inside northbound lane and shoulder, the grass median, and the inside southbound lane and shoulder. At the scene, rolling tire prints in the grass median were documented. These prints indicated a straight rolling path for V2 as it crossed the median. It is probable that the driver of V2 was either disabled or unconscious as V2 crossed the median and entered the opposing southbound traffic lanes. V1 was southbound in the middle southbound lane at an estimated speed of between 54 and 60 miles per hour as V2 was entering the same lane and traveling in a northwesterly direction toward V1.

T - 0 seconds: The front of V2 contacted the front of V1 in the middle southbound lane. At impact V1 was headed 180 degrees from north and V2 was headed 17 degrees to the west of north. The principal direction of force acting on the driver of V1 was approximately 10 degrees to the right of straight ahead. Maximum longitudinal crush to the right front bumper corner of V1 was approximately 53 inches. The driver of V1 was forced forward and slightly to the right at impact. He was using the active lap and shoulder belt, and it performed as designed. This was evidenced by abraded plastic at the belt latch, a peened buckle, abraded belt webbing and abraded plastic at the B Pillar mount. There was evidence that the driver of V1 rotated partially out of the shoulder belt. There was deformation to the upper steering wheel rim with an associated unspecified loss of consciousness, and an abrasion to the driver's left lower chest which corresponds to abrasions found on the shoulder belt. This indicates that the driver of V1 did exhibit rotation which caused the shoulder belt to ride down on his body. The windshield of V1 was impacted from the outside by the hood of V1. The resulting flying glass was probably responsible for the lacerations to the eyelids and left ear of V1's driver. There was broken and abraded plastic to the center instrument panel and an associated right hand abrasion to the driver. There was deformed plastic and fabric transfers to the lower left instrument panel in two places. This indicates that both knees contacted the instrument panel. However, the deformation was not severe, which is an indication that the lap belt functioned properly. Both the brake and accelerator pedals were deformed by occupant contact. The left toe pan was intruded longitudinally 2.5 inches and the driver sustained fractures to both lower extremities. The right A Pillar and left A Pillar intruded longitudinally 17.8 and 4 inches respectively. The steering column had longitudinal intrusion of an estimated 4.2 inches, and the right toe pan was intruded longitudinally 11.9 inches.

The principal direction of force acting on the driver of V2 was approximately 27 degrees to the right of straight ahead. Maximum longitudinal crush to the right front bumper corner of V2

was approximately 64 inches. The driver of V2 was forced forward and to the right at impact. He was not using the available active lap and shoulder belt. This was evidenced by severe deformation to the lower steering wheel rim and to the left and center instrument panel. Deposits of hair were noted deep inside a cavity in the center instrument panel just to the right of the steering wheel rim. This indicates the possibility that the driver of V2 was "slumped over" at impact and is further evidence that he may have been unconscious before impact. Intrusions to V2 were not measured due to problems with a nearby chained dog, however, upon observation, the toe pan right, center, and left was intruded longitudinally to a point at which it touched the front seat cushions. The right instrument panel was intruded longitudinally to a point at which it touched the right front seatback. The driver of V2 sustained fatal injuries from this impact.

T + .6 to 1 second: V1 came to rest facing northwest after approximately 136 degrees of clockwise rotation. V2 came to rest facing east after approximately 119 degrees of clockwise rotation. At final rest, V1 and V2 were approximately 17 feet apart with the point of impact gouges positioned on the pavement about half the distance between them. Speed change at impact for both vehicles is estimated at between 54 and 64 miles per hour.

T + 2 minutes: Police were notified of the accident.

T + 2 minutes: Police arrived at the scene.

PREHOSPITAL AND HOSPITAL TIMELINE - CASE 038

T+ 1min: Ambulance receives call to respond.

T+ 6min: Ambulance arrives at scene. Initial field assessment reveals a blood pressure of 120/80, a heart rate of 90, a respiratory rate of 24, and a Glasgow Coma Score of 15. Prehospital care includes includes fluid resuscitation with the administration of 500cc of crystalloid. The patient required extrication from the vehicle.

T+36min: Patient departs scene for MIEMSS/Shock Trauma by police medevac helicopter.

T+56min: Patient arrives at MIEMSS. Initial physiologic assessment of the patient reveals a blood pressure of 140/80, a heart rate of 100, a respiratory rate of 20, and a Glasgow Coma Score of 15. The patient's ISS (Injury Severity Score) = 12. Toxicology screen results were negative. Initial hospital care provided includes:

- -Evaluation by a MIEMSS trauma team,
- -Fluid resuscitation,
- -Full diagnostic evaluation including x-rays of the cervical spine, chest and pelvis. In addition to the toxicology screen, an arterial blood gas, a CBC (complete blood count), an SMA-6 (routine blood chemistry) and UA (urinalysis) were were performed.
- -Diagnostic peritoneal lavage with negative results,

Injuries noted include:

-Closed head injury with loss of consciousness,
-Bilateral eyelid lacerations (superficial),
-Laceration of lower lip (superficial),
-Laceration auricle, left ear (superficial),
-Abrasion lower left anterior chest,
-Abrasion of right hand,
-Lacerations of fingers of right hand (metacarpals, superficial),
-Fracture, left tibia (oblique, distal articular surface),
-Fracture, left fibula (oblique, distal articular surface),
-Fracture, right talus (oblique, proximal articular surface),
-Fracture, right calcaneus (multiple types and sites),
-Fracture, left ankle (bimalleolar).

Operative care includes:

-Open reduction of left tibia and fibula.

T + 24hours - 9 days: Patient spends 3 days in intensive care and 6 days in intermediate care. No complications were reported during this patient's acute care hospitalization.

T+ 9 days: Patient discharged from MIEMSS to home unable to ambulate.

Other victims in the same crash include a 67-year-old male, who was the driver and lone occupant in vehicle #1. Victim was transported to a local county hospital where he was pronounced D.O.A. A second victim is a 24 year old female and the driver and only occupant of vehicle #2. This patient was also transported to a county hospital for treatment.

COGNITIVE-COMMUNICATIVE ASSESSMENT - CASE 038

The patient was initially evaluated on T + 6 days. He exhibited mild auditory comprehension and verbal expression deficits. Other areas assessed were within normal limits (written comprehension, written expression, speech and cognition.) The patient was functioning at an RLAS VIII Purposeful- Appropriate response level (Rancho Los Amigos Score.) Treatment was recommended for deficits. The patient failed hearing screening and was on a P.O. diet.

The patinet received treatment and was given a discharge evaluation as an outpatient on T + 14 days. He exhibited improvement in his auditory comprehension and verbal expression scores. The other areas continued to be within normal limits. The patient was discharged from treatment and given suggestions to improve his short-term memory. The patient was diagnosed with a mild to moderate hearing loss and was on a P.O. diet. A follow-up evaluation will be attempted at three months post discharge.

BIODYNAMICS STUDY
CRASH COMPARISON, Case 038

On the initial search of the NHTSA vehicle database, using the vehicle make and model as search keys, there were 4 tests that were found.

Table 038-1
Initial Search

MAK	MOD	BOD	T#	YR	LBS.	LENGTH	WIDTH	COG	WBASE	SPEED	V	CRUSH
01	24	PU	1271	88	3169	184.30	65.00	45.50	108.00	0.00	2	15.50
			1063	87	3228	178.00	63.50	47.50	108.00	35.10	1	27.00
			459	82	3198	178.50	64.60	52.40	108.00	29.40	1	18.40
			507	82	2553	183.80	64.80	45.60	108.50	29.30	1	17.00

Of the above 4, none were found useful, because the speed of the actual case was much higher, and the crush distance was not the same. In the second query, the criteria were broadened in consultation witht he simulation engineer and 4 general search criteria were used,

- Weight - between 2500 and 3500 pounds.
- Test configuration - Vehicle to vehicle
- Closing speed - 40 m.p.h. or greater
- Impact angle of between 345 degrees and 15 degrees (plus or minus 15 degrees of straight ahead)

The resulting output produced 48 rows of data, of which 8 looked hopeful due to their proximity to actual crash conditions. These eight are shown in Table 038-2.

Table 038-2
Second Pass Search

TEST	V#	MAKE	MODEL	WEIGHT	V.SPD	CLO.SPD	CONFIG	I.ANGLE
274	1	Toyota	Celica	3020	34.80	69.60	VTV	0
	2	Ford	Mustang	3040	34.80	69.60	VTV	0
286	1	Toyota	Corolla	2670	35.40	70.80	VTV	0
	2	Chevy	Chevette	2630	35.40	70.80	VTV	0
447	1	Volvo	DL	3200	34.70	69.40	VTV	0
	2	Chevy	Citation	3170	34.70	69.40	VTV	0
456	1	Ford	Mustang	3120	35.30	70.60	VTV	0
	2	Plym.	Horizon	2770	35.30	70.60	VTV	0

Since there are no obvious best matches, a comparison of the damage profiles was made to see how close they come to the actual case. Table 038-3 Shows the damage profile.

Figure 038-2
Vehicle Damage Profile

TEST	V#	MAKE	MODEL	CRUSH POINT 1	CRUSH POINT 2	CRUSH POINT 3	CRUSH POINT 4	CRUSH POINT 5	CRUSH POINT 6
274	1	Toyota	Celica	27.20	0.00	0.00	0.00	0.00	0.00
	2	Ford	Mustang	27.80	0.00	0.00	0.00	0.00	0.00
286	1	Toyota	Corolla	22.90	0.00	0.00	0.00	0.00	0.00
	2	Chevy	Chevette	30.90	0.00	0.00	0.00	0.00	0.00
447	1	Volvo	DL	26.10	26.00	27.20	29.00	0.00	0.00
	2	Chevy	Citation	22.10	26.20	27.00	24.70	0.00	0.00
456	1	Ford	Mustang	21.80	15.20	0.00	0.00	0.00	0.00
	2	Plymouth	Horizon	26.50	26.30	0.00	0.00	0.00	0.00

The resulting vehicle damage data is shown in Table 038-4, below.

Table 038-4
Vehicle Damage Data

TEST	V#	VDI	PDOF	LENCNT	DAMST	CRHDST	OFFSET	IMPPNT
274	1	12FDEW3	0	64.40	99.90	1.60	0.00	9999
	2	12FDEW3	0	69.10	99.90	2.60	0.00	9999
286	1	12FDEW3	0	63.40	99.90	3.20	0.00	9999
	2	12FDEW3	0	61.80	99.90	1.60	0.00	9999
447	1	12FDEW3	0	64.20	0.00	26.70	0.00	9999
	2	12FDEW3	0	63.10	0.00	25.00	0.00	9999
456	1	12FDEW3	0	999.90	99.90	23.20	0.00	0.00
	2	12FDEW3	0	999.90	99.90	27.40	0.00	0.00

Crash Pulse Comparisons:

The test data on the vehicle sensors for these crashes are at Tables 038-4 through 038-6. There was no data on the fourth vehicle test case as there was apparently sensor failure or, for some reason the sensors were not used. The sensors used from the other crash tests were either engine or COG. As can be seen from the charts, the engine shows more vibration due to the engine mounts but overall the pulses of the three crashes are fairly consistent in amplitude (average -109 G's average) and duration (about 20 milliseconds).

Crash Test Injuries:

The pulses taken from the head center of gravity of the driver occupants of the test cases are shown at Figure 038-7 through 038-9. As can be seen these show widely varying G forces while displaying fairly consistent duration. Part of the wide

variation in G's is due to the fact that the test case with the lowest G force involves an air bag restraint. The others are 3 point seat belts. If one takes that into account and discards the air bag curve, then the remaining curves are not that different. In the crash tests, test 286 had an HIC of 1248 and a CSI of 926. The HIC was a windshield hit, while the chest was due to first impact with the steering wheel. Test Case 274 Had an HIC of 881 and a CSI of 562 with both caused by the steering wheel. Test case 456 had an HIC of 711 and a CSI of 324, both steering wheel induced. Case 447 involved an air bag and is not comparable except insofar as to show the drastic reduction in HIC and CSI to 299 and 222 respectively.

The actual crash did involve a serious head injury. However, because the case occupant rotated out of his seat belt to the right due to the angle of impact, he had only abrasions to the chest. There were no severe chest injuries. There was some question in the accident report as to whether the head injury was due to hitting the steering wheel. The test evidence above and the fact that there was a lack of evidence of a windshield strike lends support to the contention that it was indeed the steering wheel that caused the injury.

Significance of Crash:

Passenger cars account for about 65% of all fatalities. Of these, drivers are the fatality 58% of the time and persons over 64 (as in this case) only 12% of the time. 54% of all vehicles involved in fatal accidents occurred on Interstate highways and 35% occurred on the roadway portion of the Interstate. Also, 39% of all frontal accidents will be fatal.

Interestingly, though, only 20% of all accidents where the first harmful event was the striking of a fixed object are fatal and in this case the car hit a side rail and another car before engaging in the head-on event. It is therefore unusual for an accident that began as this one did to result in a fatality.

As for the NASS, 64% of all drivers involved in accidents are restrained. Head-ons result in an AIS >= 3 about 2% of the time and 3% will result in an AIS >= 3 where the speed is 55MPH or more. Further, where there is an intrusion of 12" or more, as there was in this case, there will be an AIS >= 3 in 25% of the cases. As a further interesting statistic, the steering wheel is the largest single cause of AIS >= 3 injuries (16%). This further strengthens the evidence that the occupant struck the steering wheel.

In summary, this was a very common occurrence and about 210,000 people per year (2% of all occupants involved) are hospitalized as a result of accidents of this kind.

PSYCHOSOCIAL FOLLOW-UP - CASE 038

6 Months

Patient was discharged home 10 days post-trauma with continued physical therapy and no weight bearing activities. Hospital bed, trapeze and wheel chair arranged for home care. At 3 months post-trauma patient had not returned to work and continues with physical therapy. His physical limitation (inability to ambulate without difficulty) has created numerous frustrations and anxiety and he states the impact on his family will not be forgotten. Patient's wife is taking over his contracting business, which can be managed from home as well as all household and other jobs. At 3 months post trauma, disability insurance had not come through and family living on savings and reduced income from business. Additional costs beyond acute hospitalization included outpatient rehabilitation, home modification, consideration of career change, additional hospitalization, legal costs, new car and over-the-counter medicines and supplies.

At 6 months patient transferred his medical care to Johns Hopkins Hospital and underwent (surgery) removal of ankle hardware from right foot. He had returned to work at 20% time, spent in office doing administrative work only. Patient cannot bear much weight and continues to use crutches when standing for any period of time. He must ambulate with use of cane, often at slow gait. Patient continues to experience increasing pain in feet and may need to have bone fused in 1-2 years although this is considered as last resort due to likelihood of decreased mobility in foot.

Patient continues with outpatient physical therapy 2 times weekly although it is felt that he has gained maximum strength due to limited mobility and endurance. Patient and family report reduced social activities and fewer outings with children. Patient unable to play any sports with children and trips and vacations usually enjoyed by all were cancelled. Wheel chair mobility became exhausting and frustrating for family.

Household and farm tasks have all been taken over by son and wife, as have majority of business duties such as bidding for jobs and on-site visits as well as all physical labor. Patient's brother has taken over care of livestock and family considering selling farm acreage due to patient's inability to do the work.

Patient, although having difficulty coping with frustrations, has not returned to smoking and alcohol use. Financial impact has been severe as disability insurance took 3 months to be processed and after receiving full benefits for 2 months, checks discontinued when he returned to work part time. Although patient was an innocent victim in crash, other vehicle insurance hasn't claimed liability stating driver had heart attack which was "act of God". Patient has had to gather extensive paperwork and evidence to prove otherwise and litigation pending.

Patient has experienced some reduced hearing and aid

recommended although not deemed necessary. His main difficulty occurs in crowds or where there are background noises. Patient and family concur that memory affected, mostly short-term. Patient also exhibits concentration problems and needs a few minutes to gather thoughts.

1 Year

At one year, patient has returned to 60% employment continuing to have difficulty with ambulation and pain. His original contracting business has dissolved and patient doing consultant work unable to physically do on-site bidding work or physical labor. He admits to depressive episodes, increased irritability and flashbacks. Financial impact has been severe with constant battles with insurance companies and on-going litigation. Patient likely to require further surgical intervention in future.

PREVENTION AND INJURY REDUCTION, CASE 038:

The driver of V2 was possibly experiencing medical problems which were the main contributing factor to this crash. The driver of V2 reportedly died from impact related forces, however, the contact points inside the vehicle suggest that he may have been "slumped over" at the time of the most severe impact. He was a 67 year old male whose medical history is unknown.

In this case, a vehicle struck a guardrail and was deflected into opposing traffic on a major highway. Wider use of Jersey Barriers or any type of barrier that would prevent vehicles from crossing into opposing traffic would substantially reduce the occurrance of head-on collisions on major highways.

Our case vehicle held up extremely well considering the high Delta V (about 55 m.p.h.). One would normally expect to see more intrusion. The integrity of the case vehicle (a 1987 Chevrolet S-10 Blazer), and the at-impact rotational forces that acted on it worked in favor of the driver whose highest injury severity was AIS-2. Many high Delta V/low injury crashes have one similarity: There is substantial rotation of the vehicle, and the person whose injuries seem less serious than one would expect was positioned near the rotational pivot point. The forces therefore go around the occupant instead of at the occupant. In this collision, V2 did not experience as much rotation and its driver was killed.

In this particular crash, not even a driver's Air Bag system would have helped the driver of V2 due to his pre-impact posture, but if he had been using the available manual lap and shoulder belt, his posture may have been different and his head almost certainly would not have been buried deep inside the instrument panel. Our case (the driver of V1) was using his manual lap and shoulder belt and in reviewing crash team photograph number 25, one can see that the belt stopped his forward motion just as his

SELECTED PHOTOGRAPHS, CASE 038

1.

Scene. V2 direction of travel. Tire prints crossing median of 6 lane divided highway toward impact point.

2.



V1 (1987 Chevrolet S-10 Blazer). Head-on frontal impact. Delta V= 54 - 64 m.p.h. Max crush = 53.1 inches.

SELECTED PHOTOGRAPHS, CASE 038

3.



V1 exterior. Right front door structure failure. Right "A" pillar intrusion= 17.8 inches. Right toepan intrusion= 11.9 inches.

4.



V2 (1985 Pontiac Bonneville 4 door sedan) Head-on frontal impact. Max crush= 64 inches. Delta V= 54 - 64 m.p.h. Driver; fatal.

SELECTED PHOTOGRAPHS, CASE 038

5.

V1 Driver's position. Steering rim (AIS-2 head). Left toepan (AIS-2 both lower extremities).Driver using lap and shoulder belt

SELECTED PHOTOGRAPHS, CASE 038

6.



V1 Driver's position. Center Instrument Panel (AIS-1 hand). Center Instrument Panel intrusion= 11.7 inches.

NOTE:

No Injury Photographs
Available For This Case

SUMMARY - CASE 366 (012)

This multi-vehicle accident occurred in the early morning hours in March, 1989. The collision involved a 1985 Dodge Omni 4 door sedan (Vehicle 1) being driven by a 26-year-old male, impacting a parked 1975 unoccupied Pontiac Firebird (Vehicle 2). The forces of this impact, with Vehicle 1's speed estimated at between 54 and 60 mph, resulted in severe injuries to the driver. He required treatment at the scene, air evacuation, admittance and treatment at a major shock trauma hospital. At impact number 1, the frontal plane of Vehicle 1 struck the rear plane of Vehicle 2 and both vehicles slid forward 45 feet to a second impact, Vehicles 1 and 2 with Vehicle 3. Vehicle 3, a 1986 Chevrolet Monte Carlo was parked and also unoccupied. At impact number 2, forward movement of Vehicles 1 and 2 stopped, and Vehicle 3 was pushed into Vehicle 4, a 1979 Mercury Capri. At impact number 3, Vehicle 4, which was parked and unoccupied was pushed forward and struck a curb. The driver of Vehicle 1 was not wearing the available lap/shoulder belts, and the vehicle is not equipped with a passive restraint system. The forces involved at impact number 1, were sufficient to cause the driver to strike and partially penetrate the windshield with his head. The driver exited his vehicle and collapsed at the right front wheel. Injuries sustained by the driver of Vehicle 1 are listed below in OIC format:

BODY CONTACTS & INJURY TABLE-CASE 366
26-year-old male driver, frontal/rear impact

OIC/AIS CODE	ICD-9	CONTACTS OR INJURIES	CONTACT POINT
2HWKB2 011100	854.06	Closed head trauma w/loss of consciousness <15 mins.	Windshield
2FULI2 011100	910.0	Facial lacerations	Windshield
2FUAI2 011100	873.49	Facial lacerations	Windshield
2MRLL5 061100	864.04	Liver laceration (Type III)	Steering Wheel & Steering Column
UNKNOWN IF INJURED		Blood & Skin Transfer	R/F Seat Bottom
		Skin Transfer & Gore	L/F Door, Upper Padding
		Skin/Gore Transfer	L/F Door
		Abraded Plastic, Skin	Hardware Middle Panel Instrument
		Abraded Plastic, Skin	Radio Knob
		Probable Skin Transfer	R/View Mirror
		Cracked, Displaced	
		Distorted Plastic, Knob	Light Switch

Bent

Lower Half
Inst. Panel

PSYCHOSOCIAL TIMELINE - CASE 366

Initial Interview

The patient, a 26-year-old married male, was the single occupant driver of a car who apparently fell asleep while at the wheel, just prior to the collision which resulted in his being admitted to MIEMSS Shock Trauma for multiple trauma.

The patient is the third youngest of six children. Married with three children, twin boys (age 5) and a three-year-old daughter, the patient lives with his family in an apartment in a suburban county. The patient also has a six-year-old daughter from a previous relationship who is being raised by the patient's mother.

The patient and family report a difficult and stressful past eighteen months. The patient had been involved in another motor vehicle accident while driving a car for the security company where he was employed. He has received Workman's Compensation; however, this has been terminated awaiting final settlement. The patient's wife is not employed and the family lacks both income and benefits. The wife has been advised to apply to social services for financial aid, medical assistance and food stamps. The extended family has been supportive and able to assist minimally. The patient has since lost job with security company due to residual back problems and has enrolled in computer training school.

The patient admits to frequent use of alcohol although denies problem with same. The patient denies usage of illicit drugs. The patient is a non-smoker and admits to having had problems in high school, having been suspended numerous times for behavioral problems and "typical teenage" drinking. He did, however, receive his high school diploma. The patient also describes alcohol abuse by father.

The patient describes self as fatalist with a philosophy of "whatever happens- happens," and tends to be discouraged in outlook on life. Although he took driver's education in high school, he is not a regular seatbelt wearer.

The patient was hospitalized for ten days and discharged to home without prescribed rehabilitation.

CRASH TIMELINE - CASE 366

T - 2 seconds: Vehicle 1, a 1984 Dodge Omni 4 door sedan, being driven by a 26 year old male, was southwest bound at a speed estimated at 54 - 60 miles per hour. The roadway at the accident location is 2 lane asphalt construction with a negative grade of 4.1% and a superelevaton of negative 6.25%. It is bordered on the east and west sides with designated parking lanes. Vehicle 2, a 1975 Pontiac Firebird, Vehicle 3, a 1986

Chevrolet and Vehicle 4, a 1979 Mercury Capri were parked and unoccupied on the west side of the roadway. The weather at the time of the accident was clear; the roadway was dry and has an estimated coefficient of friction of .65. Just prior to impact the driver of Vehicle 1 stated that he had fallen asleep. The superelevation probably enhanced the vehicle drifting out of the westbound traffic lane and into the parking lane. No pre-braking skids were evident nor any evidence of evasive action prior to impact.

T - 0 seconds: The frontal plane of Vehicle 1 impacted the rear plane of Vehicle 2. The forces involved caused both vehicles to slide forward 45 feet and the frontal plane of Vehicle 2 impacted Vehicle 3's rear plane (impact number 2). Vehicle 1 sustained a maximum crush of 17.5 inches located at the left front bumper corner. Vehicle 2 was parked with the transmission selection lever in the park position and sustained a maximum crush of 20.75 inches located at the right rear bumper corner. During the rapid deceleration, the unrestrained driver of Vehicle 1 made contact with ten documented points inside the vehicle. The most serious of these appeared to be an upper torso contact with the steering wheel and a head contact with the windshield. Preliminary injury data indicated a closed head injury with an unspecified loss of consciousness, facial abrasions and lacerations consistent with the windshield contact. The steering wheel damage is consistent with the reported type III liver laceration.

T + 0.5 seconds: Vehicle 1 and Vehicle 2 impacted Vehicle 3 and came to a full stop while fully engaged. Vehicle 3 was propelled forward a distance of approximately 12 feet and struck Vehicle 4 frontal plane V3 to rear plane V4.

T + 1.0 seconds: At impact number 3, Vehicle 3 struck Vehicle 4 propelling Vehicle 4 approximately 20 feet and over a curb.

T + 1:00 minutes: The police were notified.

T + 6:00 minutes: The police arrived.

PREHOSPITAL AND HOSPITAL TIMELINE - CASE 366

T+ 2min: Ambulance receives call to respond.

T+ 7min: Ambulance arrives at scene. Initial field assessment reveals a blood pressure of 90/70, a heart rate of 60, a respiratory rate of 18, and a Glascow Coma Score of 15. Prehospital care includes includes fluid resuscitation with the administration of 700cc of crystalloid. Prehospital care also included spinal immobilization, administration of oxygen, placement and inflation of the MAST suit, airway management and monitoring of vitals. The patient required extrication from the vehicle.

T+ 36min: Patient departs scene for MIEMSS/Shock Trauma by police medevac helicopter.

T+ 54min: Patient arrives at MIEMSS. Initial physiologic

assessment of the patient reveals a blood pressure of 150/60, a heart rate of 56, a respiratory rate of 17, and a Glascow Coma Score of 15. The patient's ISS (Injury Severity Score) = 21 . Toxicology screen results were negative.

Initial hospital care provided includes:

- -Evaluation by a MIEMSS trauma team,
- -Fluid resuscitation,
- -Full diagnostic evaluation including x-rays of the cervical spine, chest and pelvis. In addition to the toxicology screen, an arterial blood gas, a CBC (complete blood count), an SMA-6 (routine blood chemistry) and UA (urinalysis).
- -Peritoneal lavage with positive results.

Initial clinical findings included the following:

- -Closed head trauma,
- -multiple facial lacerations and abrasions,
- -Complex lacerations to the right eyelid and upper cheeks,
- -Left lobar liver laceration with parenchymal fracture,
- -Left kidney contusion.

Operative care included:

- -Surgical repair of the liver injury with lobectomy
- -Plastic surgical repair of the eyelid laceration,
- -Plastic surgical repair of the cheek laceration.

T+ 24hours - 9 days: Patient spends 4 days in critical care, 1 day in intensive care, and 4 days in intermediate care. No complications were reported during this patient's acute care hospitalization.

T+ 9days: Patient discharged from MIEMSS to home.

PSYCHOSOCIAL FOLLOW-UP - CASE 366

6 Months

Patient discharged home following 10 days acute hospitalization with no rehabilitation. Patient continued to receive unemployment compensation and Social Services while enrolled in full-time computer training school. Patient is not working but hopes to do so when finished with school. Patient continues to exhibit stomach pains and feels further medical treatment indicated; encouraged patient to make appointment at the Clinic. Patient has medical assistance.

1 Year

Patient completed computer training program although only working part time in this field. He is currently receiving disability benefits from service injury. Patient reports that he has resumed pre-injury activities; however, continues to be plagued by stomach pains and breathing problems exacerbated by his drinking. No evidence of cognitive difficulties. Patient totally independent in activities of daily living. He currently has no health insurance coverage.

CRASH AND INJURY PREVENTION IDEAS - CASE 366

This accident occurred when the driver fell asleep late at night. When a driver exceeds his capabilities by driving when fatigued, under the influence of alcohol or both, the use of electronic devices could play an important part in prevention. By alerting the driver the vehicle was on a collision path or by simply waking him, this accident may have been prevented. A deceleration device displayed prior to imminent impact, coupled with air cushion restraints, passive seat belts, or other restraint devices which the driver or occupants cannot defeat, would have significantly reduced the injuries.

--Crash Investigation Team

PREVENTION COMMENTS - CASE 366

The patient was a 26-year-old male who apparently fell asleep at the wheel and impacted his car into a parked unoccupied vehicle. The estimated impact was between 54 and 60 miles per hour and the two slid forward approximately 45 feet to a second impact with a third vehicle. The patient was not wearing a seatbelt and impacted his upper abdomen and lower thorax on the steering wheel producing a laceration of the left lobe of the liver with parenchymal fracture and then impacted his head on the windshield resulting in a closed head injury and lacerations of the face and eyelid.

This would have been largely prevented by an airbag and seatbelts, since the airbag probably would have protected him against the liver laceration and the facial impact with the steering whell, and the seatbelt would have prevented his whole body from moving forward so that his head could not contact the windshield.

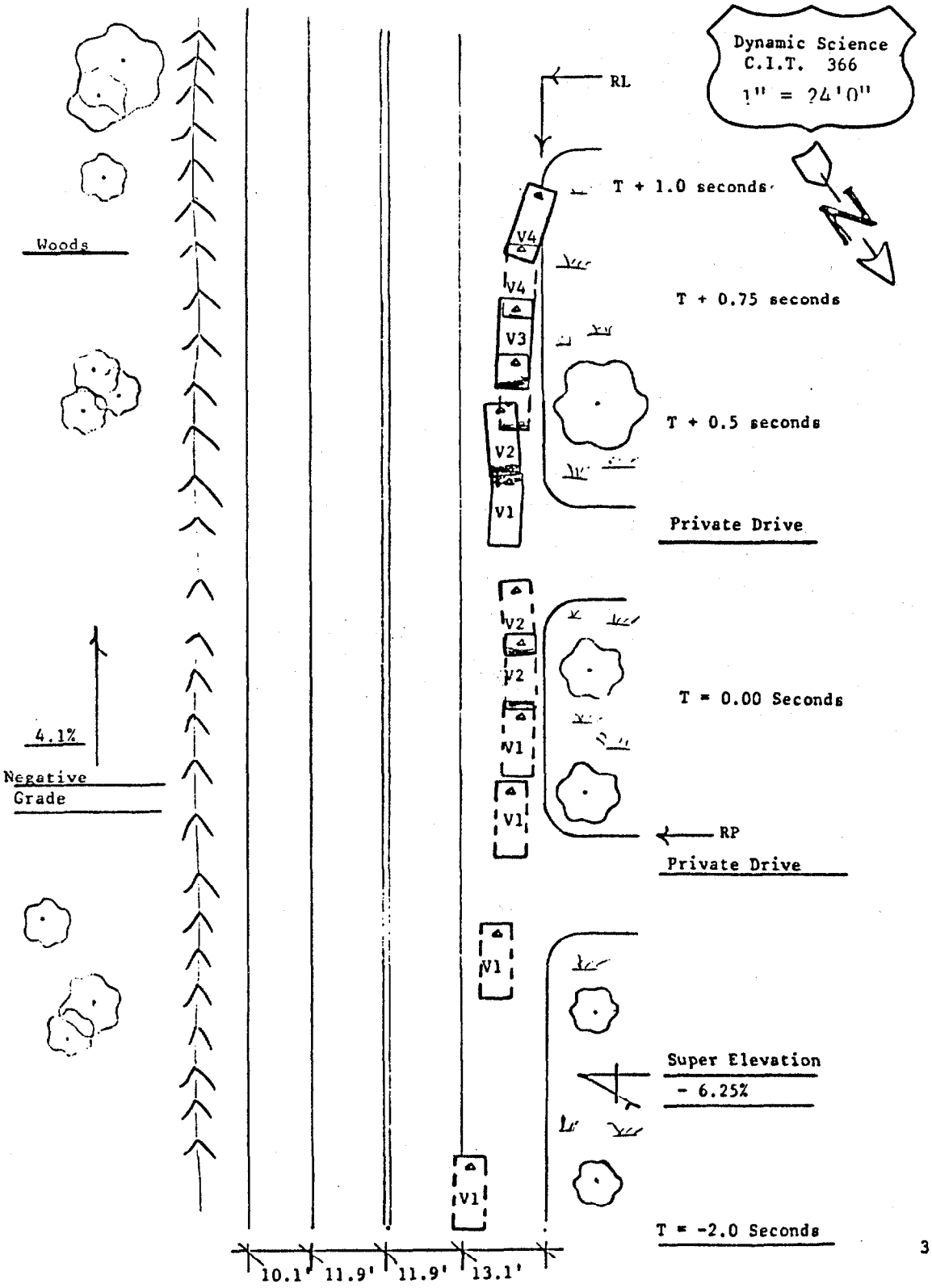
Dynamic Science
C.I.T. 366
1" = 24'0"
RL
T + 1.0 seconds
V4
V4
V3
V2
V1
T + 0.75 seconds
T + 0.5 seconds
Private Drive
Woods
V2
V2
V1
V1
T = 0.00 Seconds
4.1%
Negative
Grade
RP
Private Drive
V1
Super Elevation
- 6.25%
V1
T = -2.0 Seconds
10.1'
11.9'
11.9'
13.1'

3

SELECTED PHOTOGRAPHS, CASE 366

1.

Scene photograph showing Vehicle 1's direction of travel; single vehicle collision w/multiple unoccupied vehicles. Impact areas are between two parked cars. Frontal plane to rear planes.

2.



V1; (1985 Dodge Omni 4 door sedan). Delta-V = 26-30 m.p.h. Max Crush = 17.5" at left front bumper. Intrusion at toe pan - 4.5".

SELECTED PHOTOGRAPHS, CASE 366

3.



Driver of V1 sustained closed head trauma w/LOC <15 mins (AIS-2) when head contacted windshield; liver laceration, (AIS-5) contact w/steering wheel & column, and less severe injuries.

4.

V2; (1975 Pontiac Firebird); Max Crush - 20.75".

SELECTED PHOTOGRAPHS, CASE 366

ADDITIONAL INFORMATION:

Impact #2 - V3; (1986 Chevrolet Monte Carlo)

V1 (1985 Dodge Omni) and V2 (1975 Pontiac Firebird) slid into V3; then V1 and V2 stopped.

Impact #3 - V4; (1979 Mercury Capri)

V3 (1986 Chevrolet Monte Carlo) was pushed into V4.

No photographs are available for V3 and V4.

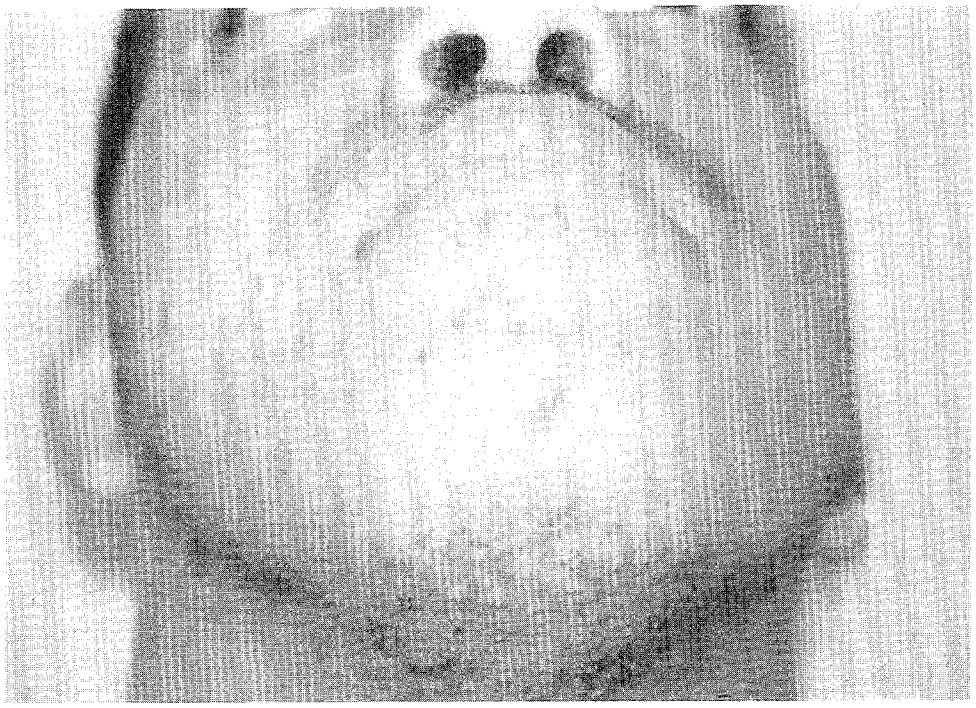

366A At four weeks, site of major chin laceration which required plastic surgery.

Contact Point- Windshield
Type of Crash- Frontal/rear impact

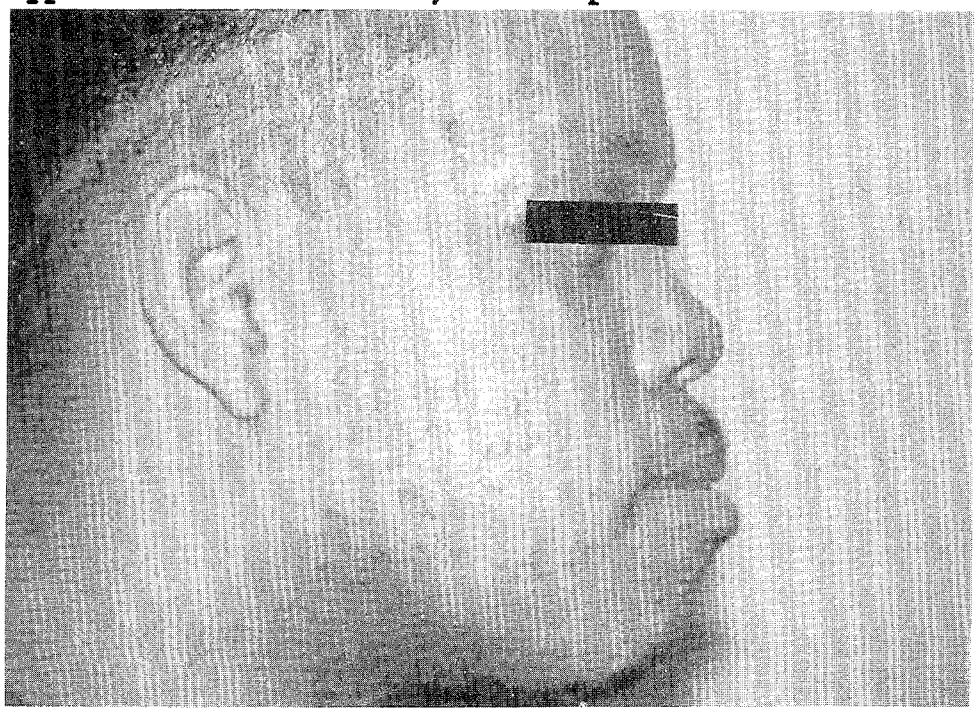

366B At four weeks, site of extensive periorbital laceration which required plastic surgery.

Contact Point- Windshield
Type of Crash- Frontal/rear impact

SUMMARY - CASE 199 (013)

This 2 vehicle accident occurred on a clear, spring, weekend day. The accident involved a 1989 Nissan Stanza 4 door sedan with one 26-year-old male occupant, and a 1987 BMW 325 2 door sedan with one 28-year-old female occupant. The roadway is an urban 2 lane concrete collector street which has one northbound and one southbound lane. Each lane is approximately twenty-two feet wide and the lanes are separated by a continuous double yellow paint line. The roadway is bordered on the east and west by 8 inch square top curbs. The Nissan, our case vehicle, was northbound in the northbound lane. The BMW was was southbound in the southbound lane. The Nissan crossed the center line and the driver locked the brakes. The Nissan began counterclockwise rotation which was intensified by a negative 7 percent roadway slope. The Nissan skidded approximately 88 feet and impacted the front of the BMW in the southbound lane. Maximum lateral crush to the right side of the Nissan was measured to be 39.2 inches. Maximum longitudinal crush to the front of the BMW was measured to be 16.2 inches. Speed change at impact was estimated to be 30 miles per hour for each vehicle. Both vehicles rotated clockwise at impact. The Nissan mounted the west curb, impacted a 6 inch diameter tree at the left rear fender, and came to rest at the west road side facing north. The BMW came to rest near the impact point and was facing west.

The driver of the BMW was not using the available lap and shoulder belt. The driver of the Nissan sustained an AIS-5 chest injury and later expired. Seat belt usage for this occupant could not be determined from the vehicle inspection. Both vehicles were towed from the scene with disabling damage. A complete list of injuries for the driver of the Nissan is listed below in OIC format:

BODY CONTACTS AND INJURIES TABLE-Case 199
26-year-old male driver, 1989 Nissan Stanza, side impact

OIC/AIS	CODE	ICD-9	CONTACTS & INJURIES	CONTACT POINT
1. 2HULI1	302101	873.0	Scalp Lacerations	Right Side Interior
2. 2FULI1	302101	873.40	Facial Lacerations	Right Side Interior
3. 2HWKB2	302101	854.0	Closed Head Injury	Right Side Interior
4. 2HUFS2	302101	801.06	Fracture, Temporal Skull with loss of consciousness	Right Side Interior
5. 2CRFS5	302101	807.09	Multiple Rib Fractures with Flail Chest and	Right Side Interior
		860.4	Hemopneumothorax (right side)	
6. 2MRLL4	302101	864.4	Liver Laceration with Massive Tissue Destruction (Right	Right Side Interior

			Lateral Lobe)	
7. 2MRLK2	302101	866.02	Kidney Laceration (right-superficial)	Right Side Interior
8. 2PAFS2	302101	808.2	Pelvic Fractures, Pubis (Superior/ Inferior) with	Right Side Interior
		902.9	Associated Hemorrhage	
9. 2PPDJ3	302101	835.01	Sacroiliac Dislocation	Right Side Interior
Unknown if Injured			Blood, hair	Left Front Seat Back and B Pillar

PSYCHOSOCIAL SUMMARY - CASE 199

Psychosocial information could not be obtained for this study patient from either the patient or the patient's family. The patient arrived at MIEMSS/Shock Trauma unresponsive and expired at T + 5 days never having regained consciousness.

CRASH TIME LINE - CASE 199

T - 2 Seconds: This was a 2 vehicle accident which occurred on a clear, dry weekend day. The accident involved a 1989 Nissan Stanza 4 door sedan (V1) with one 26 year old male occupant, and a 1987 BMW 325 2 door sedan (V2) with one 28 year old female occupant. The roadway is an urban 2 lane concrete collector street which has one northbound and one southbound lane. Each lane is approximately 22 feet wide and the lanes are separated by a double yellow paint line. The roadway is straight in the area of the collision and has a positive 7 percent southbound slope and a negative 7 percent northbound slope. The concrete surface is worn smooth and has an estimated coefficient of friction of .70. The road is bordered on the east and west by 8 inch square top curbs. The posted speed limit is 30 miles per hour.

V2 was southbound in the southbound lane and traveling an estimated speed of between 29 and 35 miles per hour. V1 was northbound in the northbound lane and traveling an estimated speed of between 57 and 63 miles per hour.

T - 1.1 Seconds: V1 crossed the center line and the driver of V1 locked the brakes. V1 began counterclockwise rotation which was intensified by the negative 7 percent northbound slope. V1 skidded approximately 88 feet and rotated approximately 60 degrees prior to impact. Analysis of the skid marks from the front tires of V1 indicates that the lateral distance between the skids corresponds to the track width of V1 (57.5 inches) at the beginning of the skid, but the skids curve slightly and their lateral separation becomes more narrow (45 inches) at the point of impact. The degree of counterclockwise rotation was obtained

from this evidence. The tread pattern signature also indicates that the driver of V1 actively steered right in an effort to steer out of the slide. However, his brakes were locked and V1 did not respond to driver steering. Just prior to impact, V1 was northbound in the southbound lane and was positioned approximately 60 degrees to the west of north. V1 was traveling an estimated speed of between 41 and 47 miles per hour. V2 was southbound in the southbound lane and was still traveling at an estimated speed of between 29 and 35 miles per hour. The driver of V2 was not using the available lap and shoulder belt and there was no evidence of avoidance actions prior to impact. Whether or not the driver of V1 was wearing the available lap and shoulder belt could not be determined by vehicle inspection.

T - 0 seconds: The right side of V1 impacted the front of V2. The front of V2 rode over the sill of V1 and completely severed V1's right "B" pillar. Maximum lateral crush to the right side of V1 was measured at 39.2 inches. The right front door panel intruded laterally 31.8 inches. The right rear door apparently came off of V1 during impact, and the driver was forced to the right. No actual body contact points were found on the right side interior surfaces, however, the driver sustained multiple serious injuries to the right side of his body. The driver contacted the left front seatback and left "B" pillar during rebound. This was the only contact point found on the interior of V1. V1 rotated clockwise during impact and mounted the west curb.

V2 came to rest near the impact point after approximately 125 degrees of clockwise rotation. There was a maximum longitudinal crush of 16.2 inches to the front of V2 and there was integrity loss through the windshield from occupant contact. Speed change at impact was estimated to be 30 miles per hour for each vehicle.

T + 1.2 seconds: V1 continued over the west curb and impacted a six inch diameter tree which was 5 feet west of the curb. This impact caused minor deformation to the left rear fender of V1 and probably did not contribute to any injuries sustained by the driver of V1. However, the driver may have rebounded to the right side of the vehicle after the tree impact. There was a pool of blood on the right sill of V1 which suggests that the driver may have been hanging out of the right front window opening at final rest. V1 came to rest on the west road side facing north.

T + 5 minutes: Police were notified of the accident.

T + 15 minutes: Police arrived at the scene.

PREHOSPITAL AND HOSPITAL TIMELINE - CASE 199

T+ 13min: Ambulance receives call to respond.

T+ 16min: Ambulance arrives at scene. Initial field assessment reveals a blood pressure of 106/palp, a heart rate of 160, a respiratory rate of 12 , and a Glascow Coma Score of 3. Prehospital care includes includes fluid resuscitation with the administration of 1100cc of crystalloid. Other prehospital care

included spinal immobilization, application and inflation of the MAST suit, administration of oxygen, airway management and the monitoring of vital signs. The patient required extensive extrication from the vehicle. Extrication time was approximately 30 minutes.

T+ 49min: Patient departs scene for MIEMSS/Shock Trauma by police medevac helicopter.

T+ 55min: Patient arrives at MIEMSS. Initial physiologic assessment of the patient reveals a blood pressure of 128/62, a heart rate of 98, a respiratory rate of 8, and a Glascow Coma Score of 4. The patient's ISS (Injury Severity Score) = 50. Toxicology screen was positive for alcohol. Initial hospital care provided includes:

-Evaluation by a MIEMSS trauma team,
-Fluid resuscitation,
-Emergent endotracheal intubation,
-Full diagnostic evaluation including x-rays of the cervical spine, chest and pelvis. In addition to the toxicology screen, an arterial blood gas, a CBC (Complete Blood Count), an SMA-6 (Routine Blood Chemistry), and UA (urinalysis) were performed.
-Peritoneal lavage with positive results.

Initial clinical findings included the following:

-Closed head trauma,
-Multiple right side rib fractures,
-Right hemopneumothorax,
-Right kidney laceration,
-Pelvic fractures with associated hemorrhage, (Right Lateral compression injury-Grade III, Right Superior/Inferior Pubis Ramus fracture),
-Right sacroiliac dislocation,
-Right clavicle fracture,
-Right open depressed skull fracture.

Operative care included:

-Layered closure of scalp laceration.
-Open reduction of pelvic fracture with placement of external fixation (Hoffman Apparatus),
-Resection and Packing of complex liver injury,
-Insertion of suprapubic catheter for aspiration of bladder,

T+24hours - 6 days: Patient spends 6 days in critical care. Surgical complications include the following: liver hemorrhage, pulmonary, bone marrow and renal failure, and delayed diagnosis of a membraneous urethral tear.

T+ 6days: Patient expires.

PSYCHOSOCIAL FOLLOW-UP - CASE 199

Patient expired in hospital 5 days post trauma of injuries received in crash. Patient left wife and 2 young children.

PREVENTION AND INJURY REDUCTION - CASE 199

Crash team photographs numbered 20 through 23 show the extent of side intrusion that can occur as a result of "B" pillar failure. Compare these photographs to photos numbered 30, 33, and 36 which show the extent of damage to the front of the other vehicle (BMW). Had the driver of the BMW been using the available manual lap and shoulder belt, she may have escaped serious injury while the driver of the vehicle with side damage sustained injuries that proved fatal. In angle collisions when the "B" pillar separates from the sill, the striking vehicle's front bumper commonly rides over the sill and intrudes into the door panels with little resistance. In this case, the BMW had maximum frontal crush of 16.2 inches compared with our case vehicle's maximum side crush of 39.2 inches. This puts the right front door panel almost into the driver's seat position at maximum engagement. Luckily, there was not a right front seat passenger in the case vehicle.

Even with this severe intrusion, the driver might have fared much better if his body had been restrained from lateral movement. The use of a manual lap and shoulder belt in these lateral impacts does not stop the torso of the occupant from moving laterally. Had the driver been restrained by a 4 or 5 point harness, his lateral motion would have been restricted. The obvious advantage of the multi-point harness is that it can restrain the occupant from moving in a variety of directions while spreading the restraint loading over a larger area of his body. The obvious drawbacks of this type of restraint are higher manufacturing costs and the possibility of a lack of consumer use.

I think that the key to preventing or reducing injuries in this type of side impact lies in the structure of the vehicle. One should consider the integral Roll Cage concept which would in effect turn the pillars, latches, and hinges into strong structural areas. If we could only reduce intrusion in cases such as this one from catastrophic to serious, we could then apply any number of interior occupant protection devices with much more effective results.

---- Jerry Jackson

PREVENTION COMMENTS - CASE 199

This patient was a 26-year-old unbelted, inebriated driver involved in a lateral collision that resulted in 39" of intrusion to the right side of his vehicle. He had been thrown from the driver's seat towards the point of impact. The patient had marked closed head injury, multiple right rib fractures and liver laceration with massive destruction of the right lateral lobe. He also had direct superficial kidney lacerations and pelvic fracture with hemorrhage and a sacro-iliac dislocation of the right side. He died of his injuries.

The severity of his injuries and probably his death would have been prevented by a seatbelt system that prevented his excursion toward the point of impact and intrusion. A vehicle built to resist lateral intrusion may also have reduced his injury severity.

COLLISION SCHEMATIC
CASE 199

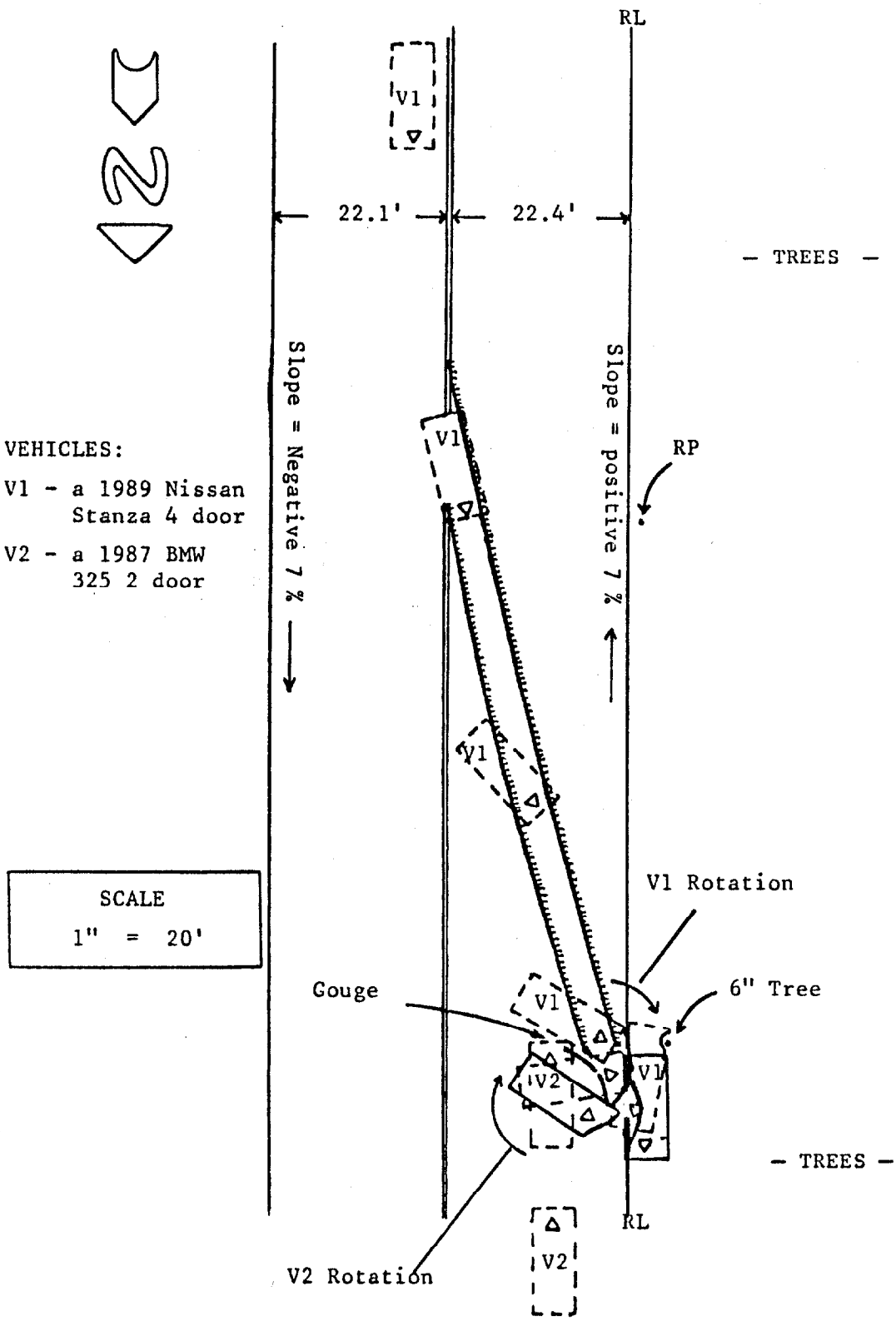

VEHICLES:

V1 - a 1989 Nissan Stanza 4 door

V2 - a 1987 BMW 325 2 door

SCALE
1" = 20'

SELECTED PHOTOGRAPHS, CASE 199

1.



Scene. 2-lane concrete urban collector street. V1 direction of travel. Photo shows V1 skids crossing centerline toward impact.

2.



V1 (1989 Nissan Stanza 4 door sedan) Side impact; "B" pillar failure. Max crush = 39.2 inches. Delta V = 30 m.p.h.

SELECTED PHOTOGRAPHS, CASE 199

3.



V1 Driver seatbelt use unknown. Roof altered; rescue. RF door intrusion 32", (AIS-5 chest, AIS-4,& 3 Abdomen/pelvis AIS-2 head)

199-31

4.



V2 (1987 BMW 325 2 door sedan) Front impact. Max crush= 16.2 inches. Delta V = 30 m.p.h. Bumper severed V1's "B" right pillar.

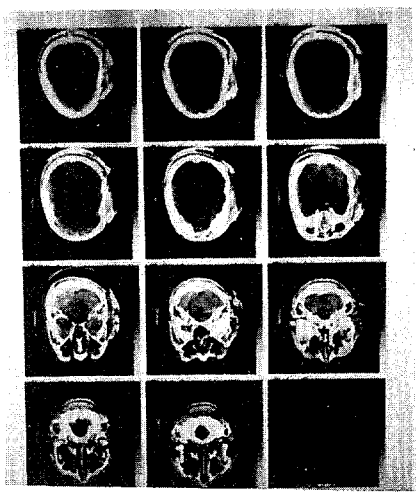

199A Head CT Scans revealing a right temporal area skull fracture.

Contact Point- Right side interior
Type of Crash- Right lateral impact

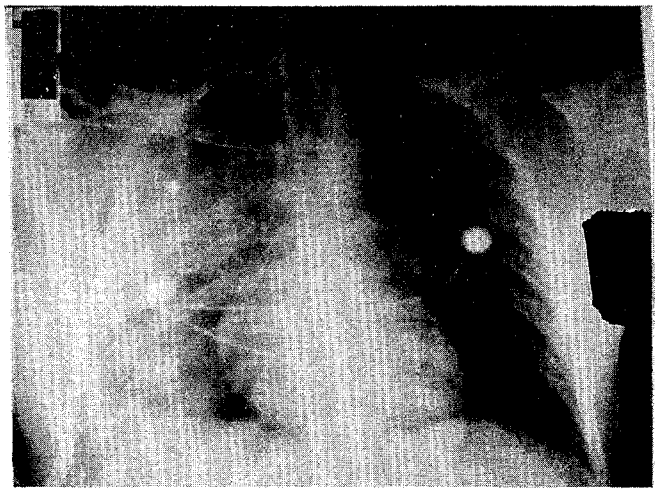

199B Chest X-Ray revealing multiple right sided rib fractures and contusion of the right lung parenchyma.

Contact Point- Right side interior
Type of Crash- Right lateral impact

199C Pelvic X-Ray revealing a superior inferior ramus fracture and wideninig of the right sacroiliac joint.

Contact Point- Right side interior
Type of Crash- Right lateral impact

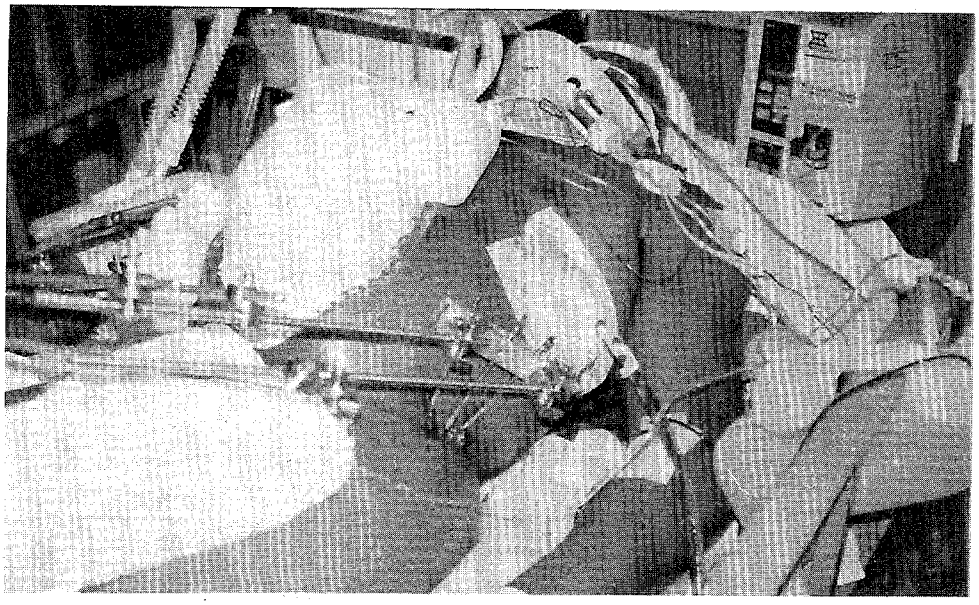

199D Hoffman external fixator apparatus for stabilization of pelvic fracture. The patient has been endotracheally intubated, is being ventilated by a respirator and is cervically immobilized with a Philadelphia collar. A large Gore-Tex graft is in place to approximate the abdominal wall. Also in place is a left chest tube.

Contact Point- Right side interior
Type of Crash- Right lateral impact

SUMMARY - CASE 124 (014)

This multi-vehicle accident occurred on a weekday in the early morning hours of spring. The accident involved a 1985 Ford Ranger pickup (V1) being driven by a 19 year old male and a 1984 Ford L9000 tractor-trailer combination (V2) being driven by a 42 year old male. The driver of the tractor trailer allowed the vehicle to drift across the 42 foot grass median from the northbound lanes into the paths of several southbound cars. The tractor-trailer unit struck a 1982 Datsun pickup (V3) in lane 3, a 1977 Chevrolet Corvette (V4) in lane 2, and the 1985 Ford Ranger pickup (V1) in lane 1. After impact #1, V3 rotated counterclockwise and struck a 1987 Jeep Cherokee (V5). A passenger riding in the bed of V3 was ejected and killed. At impact #2, V1 struck V4, killing the driver. The tractor trailer continued northbound striking V1; jackknifed while dragging V1 to its final rest position against the west bank of the southbound lanes. A passenger in V1, who was not wearing his lap/shoulder belt, was ejected and killed. The medium of ejection was not determined. No evidence of braking was noted by any of the vehicles prior to impact. The driver was entrapped by deformed steering components and sheet metal. The driver of V1 sustained multiple severe injuries, was treated at the scene, and evacuated by helicopter to a shock trauma center for admittance and further treatment. A 1988 Ford Festiva (V7) took evasive action but was unable to avoid striking the rear dual wheels of the tractor trailer (V2). V6, a 1987 Mitsubishi Cordia also took evasive action which successfully avoided V2 but experienced partial loss of control and skidded to a stop striking the passenger who had been ejected from V3.

Body Contacts and Injuries Table - Case 124

	OIC/AIS Code	ICD-9	Contacts & Injuries	Contact Point
1.	2HWKB5 142111	850.56	Glasgow coma score w/loc >24 hrs	A-pillar & l/side window frame
2.	2FLLI2 261111	873.42	Laceration-forehead (left)	Left window and frame
3.	2HRUB3 142111	853.06	Closed head injury w/right frontal-parietal intraparenchymal hemorrhage	left window, frame & A-pillar
4.	2CLAI2 261111	911.0	Abrasion-left lower anterior chest sill	Left door, window
5.	2CLCP3 142111	861.21	Pulmonary contusion left/upper & lower lobe	Left door hardware, arm rest
6.	2MLAI2 202111	911.0	Abrasions-left upper quadrant posterior abdomen	Left door hardware, arm rest
7.	2MRLL4 061111	864.02	Liver laceration superficial < 1 cm	Steering wheel and assembly

8.	2MLRQ4	271111	865.0	Laceration spleen parenchyma w/major vessel involved with--	Left door, hardware & armrest
9.			459.0	Retroperitoneal hemorrhage (moderate)	Left door, hardware & armrest
10.	2PADJ2	201111	839.69	Pubic symphysis dislocation-pelvis (midline)	ft interior surfaces
11.	2PRFS2	202111	808.2	Fracture pelvis-right anteropost. compression/grade II	Left interior surfaces
12.	2TLFS3	201111	821.01	Femur fracture-left/ closed	Left interior surfaces
13.	2LLFS2	091111	823.00	Tibial fracture-left/ plateau	Left interior surfaces
14.	2KLFS2	091111	822.0	Patellar fracture left/oblique	Left interior

PSYCHOSOCIAL TIMELINE - CASE 124

Initial Interview

The patient, a 20-year-old male, was one of two occupants of a pickup truck which was hit by a tractor trailer after crossing the highway's center median. The study patient was the unseatbelted driver, and sustained multiple trauma and was brought to MIEMSS Shock Trauma. The other passenger, who was killed, was en route to a construction job with the study patient at the time of the accident.

The patient is a high school graduate who lives at home with his parents and a 10-year-old sister. Since high school, the patient's primary occupation has been that of a laborer and carpenter. He has worked for the past year for the highway department doing construction work. His approximate annual income is $20,000 and he has complete health insurance coverage. Prior to the injury, the patient was said to have no major medical or physical problems and neither the patient nor his family has experienced any major life changes during the past twelve months. The patient is said to be close to his family, frequently interacting with large extended family. The patient has a girlfriend of two years who is a primary support figure and well integrated into the patient's family.

The patient's parents indicate that the patient has been charged with driving while intoxicated in the past and was involved in a motor vehicle accident at age 17 which was related to drinking. The patient attended Al-Anon meetings following the accident. Although the car was destroyed, the patient suffered only minor injuries and had no residual effects. The patient is a non-smoker and the family denies his usage of ilicit drugs but state that he drinks alcohol. The patient's alcohol use is confined to weekend drinking.

The patient expired at T + 5 days due to multiple trauma.

CRASH TIME LINE - CASE 124

T - 5.0 seconds: Vehicle 1, a 1985 Ford Ranger pickup and Vehicle 6, a 1987 Mitsubishi Cordia, were southbound in lane 1 of a 6 lane divided, asphalt paved expressway a speed estimated at 55 -65 miles per hour. Vehicle 4, a 1977 Chevrolet Corvette, V5, a 1987 Jeep Cherokee and Vehicle 7, a 1988 Ford Festiva were also southbound in lane 2 at an estimated 55 - 65 miles per hour. Vehicle 3, a 1983 Datsun pickup was southbound in lane 3. Vehicle 2, a 1984 Ford L9000 tractor trailer combination unit, was northbound at a speed estimated at 55 - 65 miles per hour separated from southbound traffic by a 42.0' depressed grass median. The roadways had an estimated dry coefficient of friction of .70. The southbound lanes have a negative grade of -2%, the northbound lanes have a positive grade of +2%. The condition of the grass median at the time of the accident was wet earth/grass with standing water in the center of the depression of .5 to 1.0 inches. A coefficient of friction of .45 was assigned to this median condition.

T - 1.1 seconds (estimated): Vehicle 2 crossed the median into lane 3 of southbound traffic and struck Vehicle 3. The 1983 Datsun pickup had direct damage pattern extending from the left front 1/3 of the frontal plane converting to the entire left side of Vehicle 3. Vehicle 3 rotated counterclockwise into the path of Vehicle 5 traveling in lane 2. Vehicle 5 struck Vehicle 3 and both vehicles slid to final rest at the west edge of the southbound lanes. Both the driver and passenger in the right front of Vehicle 3 were killed. A third passenger riding in the enclosed cargo bed of Vehicle 3 was ejected during the final portion of the slide to stop and was subsequently run over by Vehicle 6.

T - .6 seconds: Vehicle 2 continued northwesterly across lane 3 into lane 2 and struck vehicle 4, the 1987 Chevrolet Corvette. At impact Vehicle 2 struck the left side of Vehicle 4 slightly forward of the left front wheel and continued through the driver's compartment. The driver of Vehicle 4 was also killed at impact. Vehicle 2 continued into lane 1.

T - 0.0 seconds: Vehicle 2 struck Vehicle 1 within the left third of the frontal plane with the direct damage converting to the entire left plane. Vehicle 1 was carried to final rest by the left frontal plane of Vehicle 2. Vehicle 2 was in the final stages of a full left hand jackknife.

T + 2.7 seconds: The passenger seated in the right front of Vehicle 1 was ejected and fatally injured. The driver of Vehicle 1 suffered severe multiple injuries, AIS-5. He was treated at the scene while being extracated from the vehicle, flown to a shock trauma unit, and admitted for further treatment.

T + 1:0 minutes: The police and medical units were notified

of the accident.

T + 3:0 minutes: Police and rescue personnel arrived and began investigative and medical relief efforts.

PREHOSPITAL AND HOSPITAL TIMELINE - CASE 124

T+ 2min: Ambulance receives call to respond.

T+ 12min: Ambulance arrives at scene. Initial field assessment reveals a blood pressure of 140/palp, a heart rate of 120, a respiratory rate of 40, and a Glascow Coma Score of 3. Prehospital care includes includes fluid resuscitation with the administration of 2700cc of crystalloid. Other care provided included endotracheal intubation, spinal immobilization, splinting, bleeding control and airway management/vitals monitoring. The patient required extrication from the vehicle. Extrication time was approximately 60 minutes.

T+ 71min: Patient departs scene for MIEMSS/Shock Trauma by police medevac helicopter.

T+ 76min: Patient arrives at MIEMSS. Initial physiologic assessment of the patient reveals a Glascow Coma Score of 3. The patient's ISS (Injury Severity Score) = 50 . Toxicology screen results were negative. Initial hospital care provided includes:

- -Evaluation by a MIEMSS trauma team,
- -Fluid resuscitation,
- -Diagnostic peritoneal lavage with positive results,
- -Full diagnostic evaluation including x-rays of the cervical spine, chest and pelvis. In addition to the toxicology screen, an arterial blood gas, a CBC (complete blood count), an SMA-6 (routine blood chemistry) and a UA (urinalysis) were performed. The patient also underwent a head CT Scan.

Initial clinical findings included the following:

- -Right frontal parietal intracerebral hemorrhage,
- -Superficial abrasion of the left cheek,
- -Laceration of the left forehead,
- -Left pulmonary contusion,
- -Ruptured spleen,
- -Liver laceration,
- -Pubic symphysis dislocation of pelvis,
- -Closed left (proximal 1/3) femur fracture,
- -Left tibial plateau fracture, and
- -Left patellar fracture.

Operative care included:

- -Surgical reduction of pelvic fracture,
- -Placement of external pelvic fixation,
- -Fasciotomy of left upper leg and placement of traction on left femur,
- -Placement of an intracranial pressure monitoring device,

-Resection of the Right Cerebral Hemisphere,
-Resection of the spleen,
-Repair of the major liver injury.

T+24hours - 4 days: Patient spends 4 days in critical care. Complications include the following: massive brain edema and multi-organ failure.

T+ 4days: Patient expires.

PSYCHOSOCIAL FOLLOW-UP - CASE 124

Patient expired 5 days post-trauma of injuries received in crash.

CRASH AND INJURY PREVENTION IDEAS - CASE 124

This accident occurred when a tractor-trailer unit crossed a depressed median and entered the opposing lane of traffic. The installation of continuous Jersey Barriers and electronic sensing units may have prevented this accident. The truck driver traveled in a near straight line across a 42' grass median and took no evasive action from first impact to final rest. Drivers need constant reinforcement concerning safe driving programs. The use of these programs at license renewal time, mandatory in nature, could make the driver more aware of defensive driver tactics and the need to stay alert. Increased side impact protection and a lowering of bumper heights on large trucks may also have reduced the number of fatalities and severe injuries.

PREVENTION COMMENTS - CASE 124

This is a 19-year-old male driver of a Ford Ranger pick-up that was struck in a complex accident by a large tractor trailer carrying a heavy load of steel. The impact which took place on the left frontal/lateral aspect of the car completely demolishing the front side and with marked intrusion of the left side of the car into the passenger compartment. The patient sustained a severe and eventually fatal head injury due to contact with the A-pillar which produced not only a forehead laceration but a significant interparenchymal hemorrhage of the right frontal parietal area. In addition, he had contact of left chest and upper abdomen with the left door hardware and window which produced pulmonary contusions, severe splenic laceration requiring resection, and a superficial liver laceration on the contrecoup side. There was also a significant pelvic fracture with retroperitoneal hemorrhage which was probably related to again, striking the left door hardware; and a fracture of the left femur and tibial plateau fracture which are related to striking the surfaces of the anterior left side of the car.

From a prevention point of view the most important factors, of course, are related to issues outside the present car. The first is that the driver of the tractor trailer had a positive toxicology level and was also taking some medication. He claimed to have blacked out, although he had a previous drunk driving conviction before. Secondly, he had to cross a 42 foot median and if there had been an adequate barrier, this would probably have stopped or substantially impeded the velocity and force impact of the tractor trailer which would have saved not only this driver but several others. From the point of view of this patient's car, even with the relatively high sides of the Ford pick-up, the massive injury was caused by marked intrusion of the left side of the car. The major problems, of course, was the A-pillar which produced the fatal head injury and the major intrusion of the left door which produced the visceral injuries. This last factor contributed to his final demise by adding a component of hypotension and volume loss (shock) to the initial head injury, which has been shown to markedly increase mortality under these circumstances. Patient was unbelted and there was no airbag. Both of these might have prevented to some degree or at least ameliorated the severe head injury secondary to the A-pillar if the airbag had been on the steering wheel or the A-pillar. It probably would not have prevented the splenic or liver injuries or the femur injury which came from lateral intrusion. These perhaps might have been prevented by better strengthening the locking mechanism of the door and having some kind of steel protection (positive roll-over cage); although the weight and force delivered by this large truck probably would have managed to produce an injury in any circumstances, but it might not have been fatal.

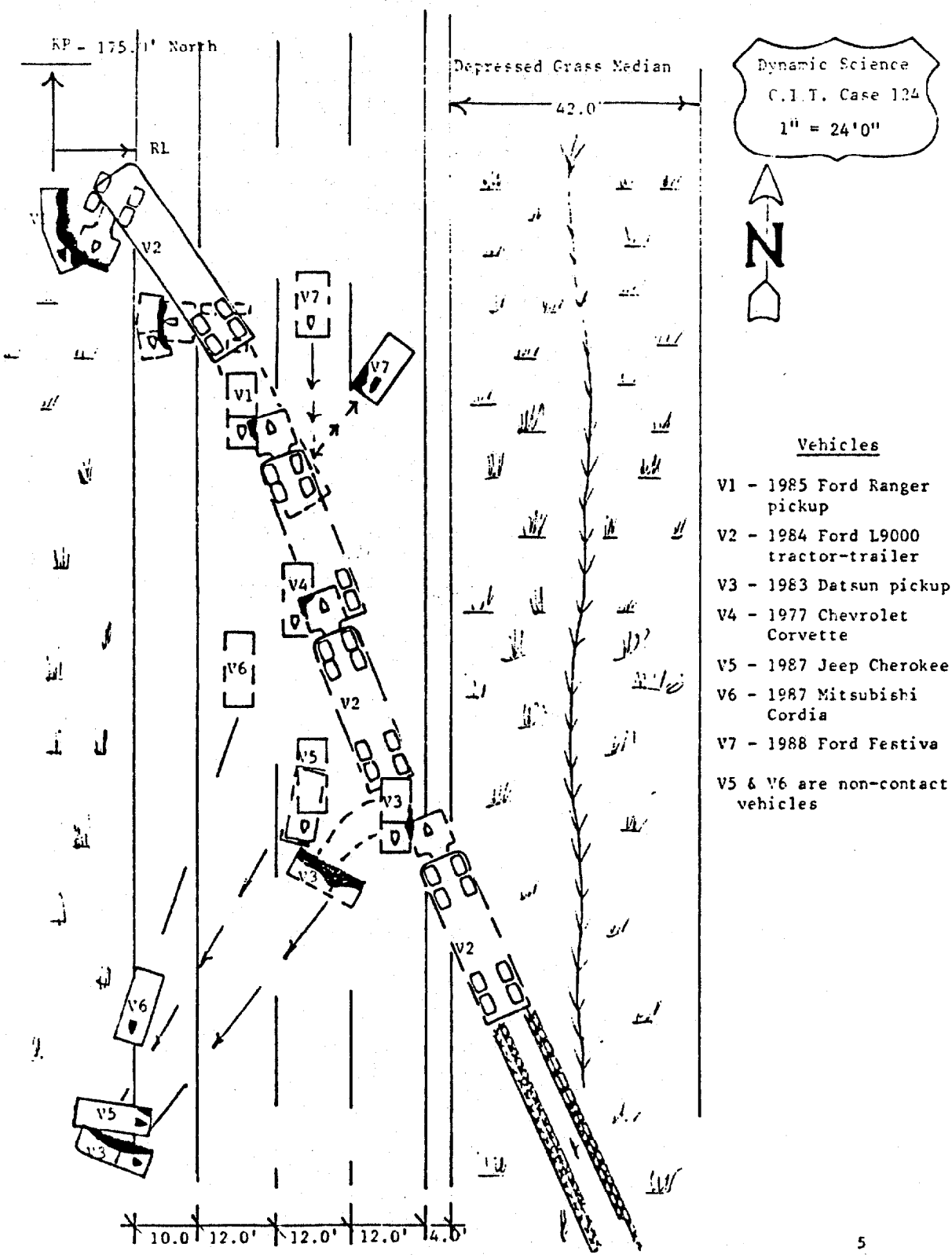
KP - 175.1' North
RL
Depressed Grass Median
42.0'
Dynamic Science
C.I.T. Case 124
1" = 24'0"
N
V1
V2
V3
V4
V5
V6
V7
10.0'
12.0'
12.0'
12.0'
4.0'
Vehicles
V1 - 1985 Ford Ranger pickup
V2 - 1984 Ford L9000 tractor-trailer
V3 - 1983 Datsun pickup
V4 - 1977 Chevrolet Corvette
V5 - 1987 Jeep Cherokee
V6 - 1987 Mitsubishi Cordia
V7 - 1988 Ford Festiva
V5 & V6 are non-contact vehicles

SELECTED PHOTOGRAPHS, CASE 124

124-01

1.

Vehicle 1's direction of travel. Note the curve to the left in the road.

124-51

2.



V2; 1984 Ford L9000 tractor-trailer combination. Damage to entire frontal plane.

SELECTED PHOTOGRAPHS, CASE 124

3.

V1; 1985 Ford Ranger pick up. Max intrusion 40.0" at "A" pillar. Head-on lateral impact. Crush could not be measured due to catastrophic damage from being struck and dragged beneath truck.

4.

V1 driver sustained a Glascow coma score w/LOC > 24 hrs. (AIS-5) when head struck "A" pillar & L/S window frame; liver & spleen lacerations (AIS-4) steering wheel, left door, hardware, armrest

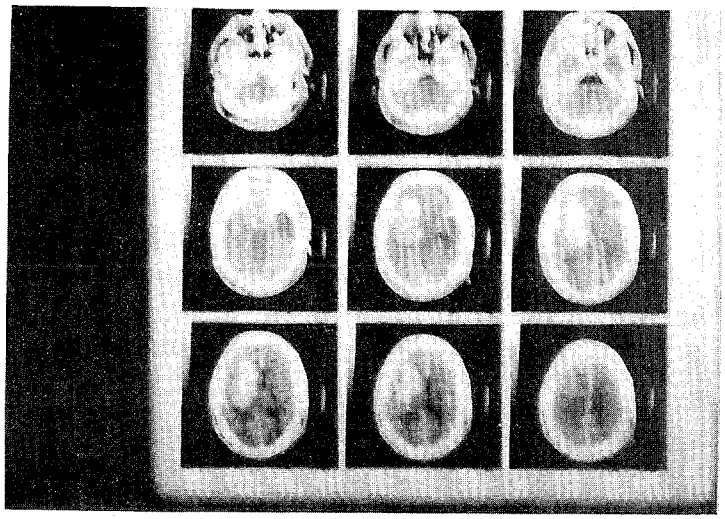

124A Head CT Scans revealing massive right frontal and parietal hemorrhages which are causing a shift of the brain tissue from right to left.

Contact Point- Left window frame and A pillar
Type of Crash- Left lateral impact



124B Multiple abrasions of the left face and laceration of the chin. The patient has been endotracheally intubated, is being ventilated by a respirator and has an oropharyngeal airway in place. The patient is also cervically immobilized with a Philadelphia collar.

Contact Point- Left window frame and A pillar
Type of Crash- Left lateral impact

124C Chest X-Ray revealing a left pulmonary contusion.

Contact Point- Left door, window, door hardware, armrest
Type of Crash- Left Lateral impact

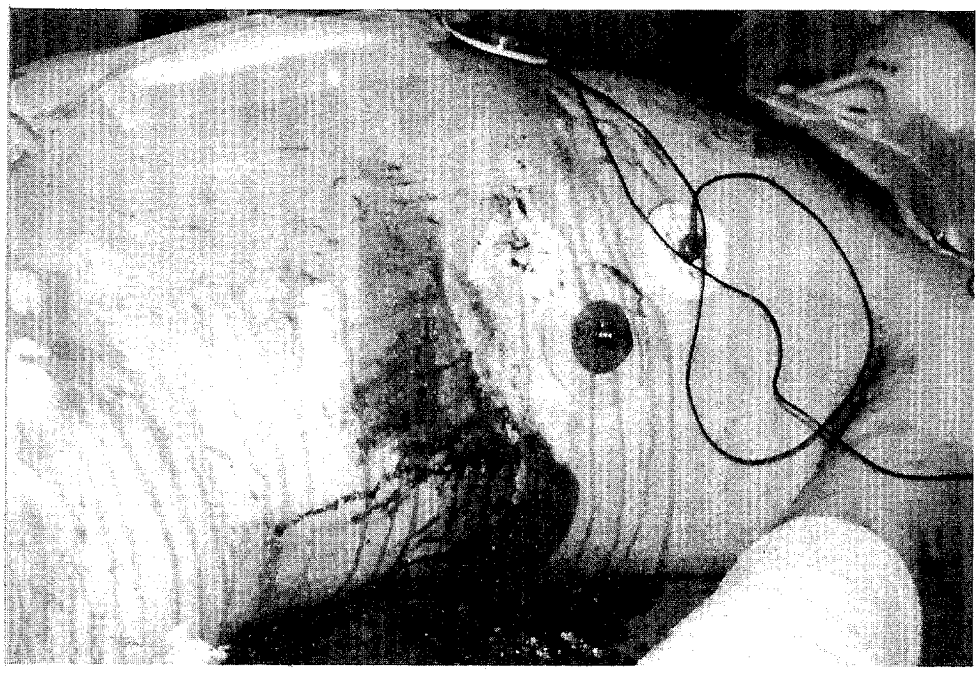

124D Abrasions to the left upper quadrant of the abdomen and flank.

Contact Point- Left door, window, door hardware, armrest
Type of Crash- Left lateral impact



124E Operative photo showing resected spleen with a deep parenchymal laceration.

Contact Point- Left door, door hardware and armrest
Type of Crash- Left lateral impact

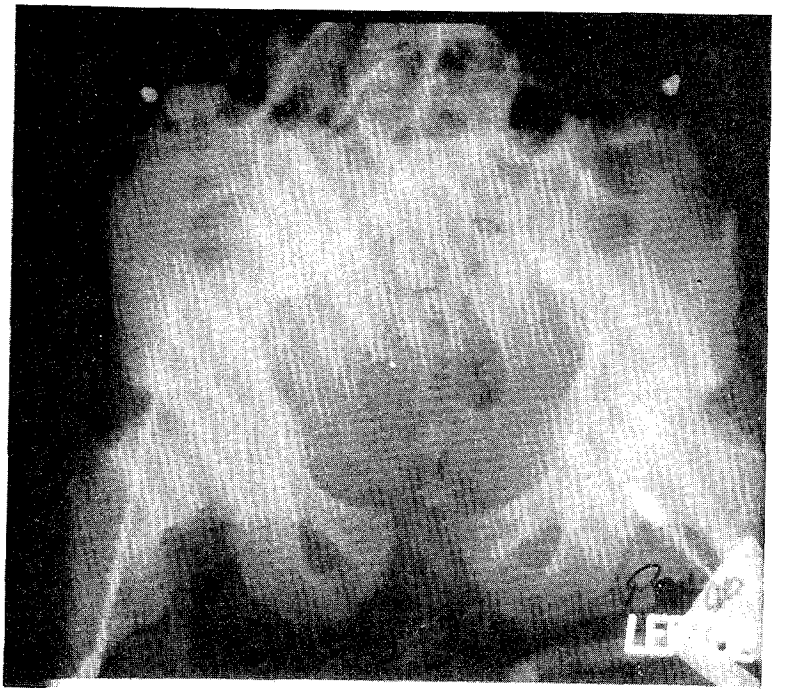

124F X-Ray revealing a right antero-posterior Grade II type compression fracture. The syphysis pubis is widened.

Contact Point- Left interior surfaces
Type of Crash- Left lateral impact

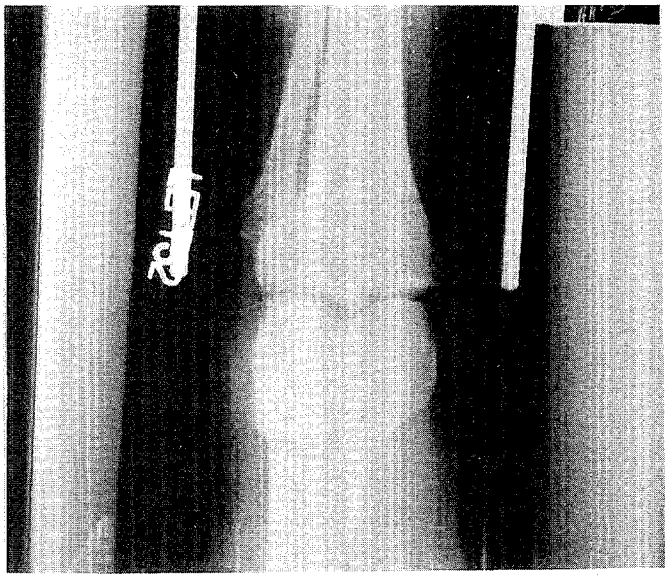

124G X-Ray revealing a closed, lower 1/3, comminuted fracture of the left femur, with intact superficial femoral artery as demonstrated by angiography.

Contact Point- Left interior surfaces
Type of Crash- Left lateral impact

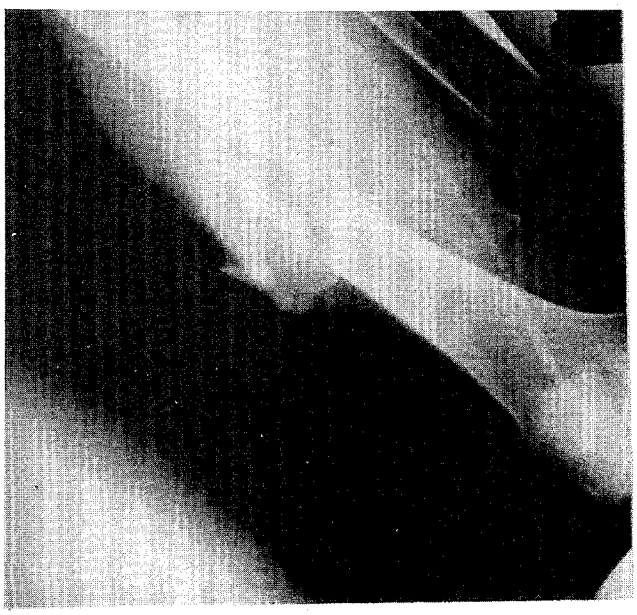

124H X-Ray revealing a left tibial plateau fracture and a fracture of the patella. The fracture is seen to directly involve the weight bearing surfaces of the knee.

Contact Point- Left interior surfaces
Type of Crash- Left lateral impact

SUMMARY - CASE 361 (015)

This single vehicle accident occurred on a clear, spring, weekday night. The collision involved a 1979 Mercury Marquis 2 door sedan with one 45-year-old female occupant. The vehicle was southbound on a 2 lane rural asphalt highway which was bordered on both sides by farmland. The vehicle entered a right-hand curve at an estimated speed of between 40 and 50 miles per hour, continued straight, and departed the roadway at the northbound shoulder. The vehicle impacted the ground at the bottom of a 26 inch deep ditch, continued south an additional 95 feet, and struck a 9.5 inch wide utility pole. The pole broke at impact and the vehicle came to rest approximately 25 feet south of the pole and was still facing south. There was no evidence of any braking either before or after impact. Maximum longitudinal crush to the front bumper of the vehicle was measured at 18 inches and the estimated speed change at the pole impact was between 12 and 20 miles per hour. The driver was not wearing the available lap and shoulder belt and was seriously injured. A complete list of injuries for this case is listed below in OIC format.

BODY CONTACTS AND INJURIES TABLE Case-361
45 year old female; Driver; 1979 Mercury Marquis; Frontal impact

OIC/AIS CODE	ICD-9	CONTACTS & INJURIES	CONTACT POINT
1. 2HWKB2 542100	854.2	Closed Head Injury with loss of consciousness = 10 minutes	Roof?
2. 2HRUB3 542100	852.1	Small Right Parietal Subarachnoid Hemorrhage	Roof?
3. 2FCFS2 023100	802.1	Open Nasal Fracture	Rear View Mirror??
4. 2FIFS3 023100	801.2	Left Medial Maxillary Sinus Fracture	Rear View Mirror??
5. 2MILD2 041100	863.89	Mesenteric Tears (involving 1.5 feet of Ilium)	Steering Rim
6. 2BIFS2 041100	806.4	Burst Fracture Lumbar 1	Steering Rim
UNKNOWN IF INJURED		Blood, Hair (head contact)	
UNKNOWN IF INJURED		Abraded, Broken Plastic (knee contact)	Instrument Panel Center & Left

PSYCHOSOCIAL TIMELINE - CASE 361

Patient is a 45-year-old female who was admitted to Shock Trauma after the car in which she was the only occupant, missed a curve in the roadway and hit a pole. Patient was unbelted driver

and had been drinking prior to the accident which occurred at night. Patient sustained a fracture to the first Lumbar vertebra, closed head trauma, a fractured nose and a small bowel injury.

Patient is the third youngest of eight siblings, her parents are deceased and her relatives live out-of-state. She is currently separated from her third husband of 2 years, after being assaulted by him seven months prior to this injury. Patient is presently living in a trailer park, which is somewhat isolated, with three children: ages 16, 19, and 21. She was laid off work three days prior to injury, having been employed as an assembly line worker in a major industrial firm some 30 miles from home.

At the time of injury, patient was enroute to pick up her oldest son from work. She had dropped him off earlier, as he does not drive due to a seizure disorder, after which she went to a local bar until it was time to pick him up. Patient admits to a recent increase in drinking as a way of coping with her marital separation, legal problems, income loss and present unemployment. Patient denies use of other drugs and is a nonsmoker. She admits to being raised by an alcoholic father. In addition, patient's support system is limited as she moved to rural Maryland from a western state, four months prior to injury, in hopes of a reconciliation with her husband.

Patient has no health insurance coverage and has been advised to apply for Medical Assistance and unemployment insurance. Although the patient has a valid out of state driver's license, she has never had a driver's education course and admits to rarely wearing seatbelts.

CRASH TIME LINE - CASE 361

T - 2 seconds: This was a single vehicle accident which occurred on a clear, dry, weekday afternoon. The accident involved a 1979 Mercury Marquis 2 door sedan with one 45 year old female occupant. The roadway is an asphalt 2 lane rural highway which has 1 northbound and 1 southbound lane. The lanes are each approximately 14 feet wide and are separated by a broken yellow paint line for southbound traffic, and a solid yellow paint line for northbound traffic. The travel lanes are bordered on the east and west by paved shoulders which are each approximately 10 feet in width. The roadway is situated in an area of open farmland.

The vehicle was southbound in the southbound lane and was traveling an estimated speed of between 40 and 50 miles per hour. The vehicle entered a right-hand curve which had a radius of 473 feet and a superelevation slope of a positive 5 percent. The driver failed to steer the vehicle through the curve and crossed the center line, the northbound lane, and the east shoulder. Scene evidence suggests that the vehicle traveled in a straight line as it departed the roadway. The driver was not wearing the available lap and shoulder belt.

T - .68 to .85 seconds: The vehicle departed the east road edge and continued to travel south on dirt and grass. The vehicle was experiencing a steep negative lateral slope as it rolled into a ditch.

T - 0: The vehicle impacted the ground at the bottom of the ditch. The ditch ran longitudinally along the east side of the roadway and had an average depth of 26 inches. The impact primarily involved the undercarraige of the vehicle, however, there was an estimated speed change at impact of between 4 and 14 miles per hour. There were considerable downward and forward forces acting on the driver and head contact was made to the interior roof as the driver rebounded from this impact. The driver also sustained an associated head injury. The vehicle continued south across the dirt and grass at an estimated speed of between 32 and 36 miles per hour.

T + 2 to 2.4 seconds: The vehicle impacted a 9.5 inch wide utility pole approximately 95 feet south of the ditch impact. The pole broke at impact and caused a maximum longitudinal crush of 18 inches to the center front bumper of the vehicle. Estimated speed change at impact was between 12 and 20 miles per hour.

The driver was still seated at the driver's position at this impact and was forced forward into the steering rim. The entire rim/hub was bent forward at the connecting point with the steering column. Normally the rim itself would deform in a frontal impact such as this, but in this case, as the top half of the rim moved forward, the bottom half moved upward thus exposing the lower edge of the rim to the driver's abdomen. The driver sustained serious abdominal injury and an associated burst fracture of the first lumbar vertebra.

The only intrusion to the vehicle was a 3.7 inch longitudinal intrusion to the left toe pan. Estimated vehicle speed just prior to the pole impact was between 22 and 27 miles per hour.

T + 3.8 to 4.2 seconds: The vehicle came to rest approximately 25 feet south of the pole impact and was still facing south. There was no evidence of any braking during this accident. There was a knee impact to the left instrument panel as evidenced by abraded and broken plastic. There was also occupant contact to the rear view mirror. The mirror and the windshield behind the mirror were cracked and the mirror was dislodged. The driver sustained serious facial injuries, but both the steering rim and the mirror are possible sources of those injuries. The only other occupant contact point found was a deposit of hair and blood on the center instrument panel. This suggests that the driver lay over to the right after impact. The driver was reportedly found in that position at the accident scene.

T + 7 minutes: Police were notified of the accident.

T + 19 minutes: Police arrived at the scene.

PREHOSPITAL AND HOSPITAL TIMELINE - CASE 361

T+ 7min: Ambulance receives call to respond.

T+ 28min: Ambulance arrives at scene. Initial field assessment reveals a blood pressure of 110/63, a heart rate of 86, a respiratory rate of 16, and a Glascow Coma Score of 15. Prehospital care includes administration of oxygen, vital signs monitoring. The patient required extrication from the vehicle.

T+ 48min: Patient departs scene for MIEMSS/Shock Trauma by police medevac helicopter.

T+ 84min: Patient arrives at MIEMSS. Initial physiologic assessment of the patient reveals a blood pressure of 70/50, a heart rate of 135 , a respiratory rate of 16, and a Glascow Coma Score of 14. The patient's ISS (Injury Severity Score) = 22. Toxicology screen results were positive for alcohol.

Initial hospital care provided includes:

- -Evaluation by a MIEMSS trauma team,
- -Fluid resuscitation,
- -Peritoneal lavage with grossly positive results,
- -Full diagnostic evaluation including x-rays of the cervical spine, chest and pelvis. In addition to the toxicology screen, an arterial blood gas, a CBC (complete blood count), an SMA-6 (routine blood chemistry) and UA (urinalysis) were performed.

Initial clinical findings included the following:

- -Closed head trauma,
- -Right parietal subarachnoid hemorrhage,
- -Open nasal fracture,
- -Left medial maxillary sinus fracture,
- -Mesenteric tears of the small bowel,
- -L1 Spinal burst fracture.

Operative care included:

- -Plastic surgical repair of the open nasal fracture,
- -Surgical repair of the L1 burst fracture with an iliac crest bone graft and placement of Harrington Rod from L2 to T-10,
- -Exploratory laparotomy with small bowel resection (~1.5 feet of ileum) and stapled anastomosis.

T+ 24hours - 13days: Patient spends 4 days in critical care, 1 day in intensive care and 8 days in intermediate care. No complications were reported in the acute care hospitalization of this patient.

T+ 13days: Patient discharged from MIEMSS.

COGNITIVE-COMMUNICATIVE ASSESMENT - CASE 361

The patient's cognitive-communicative skills were assessed on T + 2 days. No deficits were noted in the areas of auditory comprehension, written comprehension, verbal expression, speech or cognition. Written expression skills could not be assessed due to the patient's positioning at the time of evaluation. The patient was felt to be functioning at an RLAS (Rancho Los Amigos Score) VIII level (Purposeful-Appropriate Response.) Hearing and swallowing skills were within normal limits. No treatment

or follow-up was indicated and the patient was discharged from speech language pathology services.

CRASH ANALYSIS - CASE 361

Introduction:

Initial passes through the data base provided almost no usable data. The search had to be widened considerably before the tests 518 and 709 were found and then the only similar characteristics was the damage profile (Crush). Data was also used from an existing data set for weight approximations (i.e. a Mercury Marquis is the same car as the Ford LTD).

Crash Impulse Curve:

Crash test curves from cases 518 and 709 in the Test Data Base were used as a basis because of similar damage profiles (crush of 18 inches frontal). Data on Cadillacs, Mercurys and Fords did not produce anything close to the crash. As a result we had to go as far afield as a Chevy Vega. The simulation team combined this with some available historical data on the weight and other physical characteristics of Cadillacs and Ford LTDs to provide adequate input to the model. The Center of Gravity and Firewall curves were used. The results of the retrieval of the crash curves are at Figures 361-1 to 361-4. The simulation engineer estimates the forces at 16G over a time of 150 milliseconds. As always, the curves show significant oscillation even when smoothed and filtered.

In the evaluation of the forces in play, two distinct motions were considered. The first was a vertical motion to represent the ditch and the second was the horizontal motion into the pole. The latter, of course, was the more severe. Incidentally, the crash curves from the test data base case # 518 (361-1 and 2) are typical of some of the poor and unusable data from the data base.

Comparison of Injury Levels:

The case 709 from the data base showed an HIC of 280 and a CSI of 377. The dummies in this test case were, however, restrained and so would not achieve the injury levels of an unrestrained test.

Significance of the Case:

This is a fairly typical case of an involvement of alcohol and some fairly routine consequences. Statistics tell us that 55% of all accidents in which alcohol is involved result in injuries of AIS greater than or equal to 1 and 29% result in an AIS of greater than or equal to 3. As a matter of fact, about 7% of

alcohol related accidents where a pole was the first object hit resulted in a fatality. Considering the fact that the case occupant was also not restrained, she is lucky to be alive.

It is interesting to note, however, that females age 35-49 are a low instance group for the involvement of alcohol (2.3%) and only 1% during the daytime on a weekday. This probably occurred as a result of the unemployed status of the driver.

The rest of the conditions of the accident are fairly common. About 18% of all accidents in rural areas at 25 MPH or less have an AIS of 1 or more. This rises to 24% for fair weather afternoon conditions. Collisions with stationary objects (a pole in this case) is the single largest event in alcohol related accidents (49%). Further, where the passenger compartment intrusion is 2-6 inches as it was in the case there is a 66% chance of an AIS of 1 or more. Similarly, the fact that the case occupant was in the drivers seat and apparently contacted the steering wheel and windshield place this case in a very common group of occurrences where the likelihood of an AIS of at least 2 is rather high (13%).

In summary, this case occupant could very well have been a fatality. Had the crash been at a slightly higher speed this case could have been a contribution to the FARS data base. Negotiating a curve is the number two most common maneuver in producing a fatality. Further, two door hardtop coupes account for 32%of all fatalities. It is the highest among all vehicles.

PSYCHOSOCIAL FOLLOW-UP - CASE 361

6 Months

Patient discharged home from Shock Trauma with outpatient physical therapy 13 days post-injury. Patient lives in mobile home and is ambulating without assistance and independent in all activities of daily life. No residual effects evidenced with memory, communication, or cognition. Her three teenage children were primary caretakers. At 3 months post-trauma, patient resumed driving. She was also re-admitted to hospital for further nose surgery. Evidence of back pain continued and patient not able to return to former assembly line work due to need for lifting and stretching, or waitress work, due to decreased mobility. Although use of alcohol had increased initially post-trauma, patient has enrolled in alcohol treatment program.

Although patient was without her own income the entire 6 months post-trauma and remained unemployed she was not eligible for Social Services financial aid due to income of sons ages 19 and 21. Despite son's lay-off and loss of $1900 wages, family was only able to receive medical assistance.

Patient continues to experience personal problems, e.g.

difficulty with daughter who is requesting legal emancipation and divorce proceedings which are being finalized.

Patient also states increase in allergies since nose injured. Financial impact has been severe since injuries and family has been totally disrupted.

1 Year

At 8 months post-trauma patient had returned to part time employment doing clerical work and again layed off as company went out of business. Patient currently working part time taking care of elderly homebound lady and doing well having resumed pre-injury activities. Although in some pain, patient has no outward physical effects from injury but continues to be restricted in lifting, etc. Patient has continued with AA Program and is secretary of the organization.

PREVENTION AND INJURY REDUCTION - CASE 361

This is yet another case in which a vehicle, whose driver was under the influence of alcohol, departed a curved roadway and struck a fixed object. Luckily for the driver, the vehicle decelerated substantially before striking the utility pole, and the pole broke at impact which reduced the impact forces. Some of our case's injuries occurred as a result of her bouncing around inside the vehicle before the pole impact. Only 2 of the injuries appear to have been sustained at the pole impact. Had she used the available manual lap and shoulder belt, several of her injuries may have been avoided. With the deployment of a steering hub mounted Air Bag, she may have escaped injury completely since the Delta V was relatively low (12 to 20 miles per hour). This assumes of course that the Delta V was high enough to trigger deployment had an Air Bag been present. The roadway was well marked and evidence suggests that the driver may have fallen asleep. She entered the curve and just continued in a straight line. Possibly future windshield mounted sensors could detect eye movement and sound an alarm if the eyes did not follow the vehicle's path. There are similar systems under development in the aerospace and defense industries. Sensors are mounted either in the airplane's windshield or in the pilot's helmet visor. The pilot can perform a wide range of weapon deployments or maneuvers using eye movement. While the passenger car system could be much simpler in design, the concept is basically the same.

---- Jerry Jackson

PREVENTION COMMENTS - CASE 361

This patient was a 45-year-old occupant who had a single

vehicle accident on a rural highway when she departed the left side of the road probably because she was asleep secondary, possibly, to alcohol ingestion since she had a positive toxicology screen. She crossed a ditch and impacted with a utility pole. The patient was not wearing the lap and shoulder belt. She had a closed head injury and transient loss of consciousness probably from impact with the roof resulting in a Glasgow Coma of 15, however with a very small right parietal subarachnoid hemorrhage that did not require any operative therapy. She had a nasal fracture which was related to her face striking the rear view mirror as well as a left medial maxillary sinus fracture and she had some esoteric tears from the steering rim. Most significant injury was probably the burst fracture of L1, which probably was related to axial loading from the head striking the roof since the seat was impacted back. This would be much more consistent with the injury than impact with the steering rim, since this latter would not generally tend to cause a burst fracture.

Obviously, in this case, an adequate system to prevent an inebriated driver from driving the car and would have perhaps obviated the entire issue to begin with. Secondly, some kind of restraint that would have tended to keep the car from leaving the road by having some kind of lateral barrier might, have protected her; but more important, if she had been wearing her lap and shoulder belt she probably would not have impacted the roof with her head to the same degree since the car did not turn over. This patient also probably would not have had the maxillary and nasal fractures since she would have been prevented from striking the rear view mirror since both the head injury and the burst fracture probably were related to axial loading. An airbag also might have prevented her from having the facial fractures and lacerations, but probably would not have prevented her from striking her head and axially loading her vertebral column since it wouldn't have protected her from moving toward the roof. However, the seat appears to have some failure since it was shifted back into the second portion of the car and therefore a stronger seat support preventing backward deviation in a forward crash might have prevented her from being ejected toward the roof.

COLLISION SCHEMATIC
CASE 361

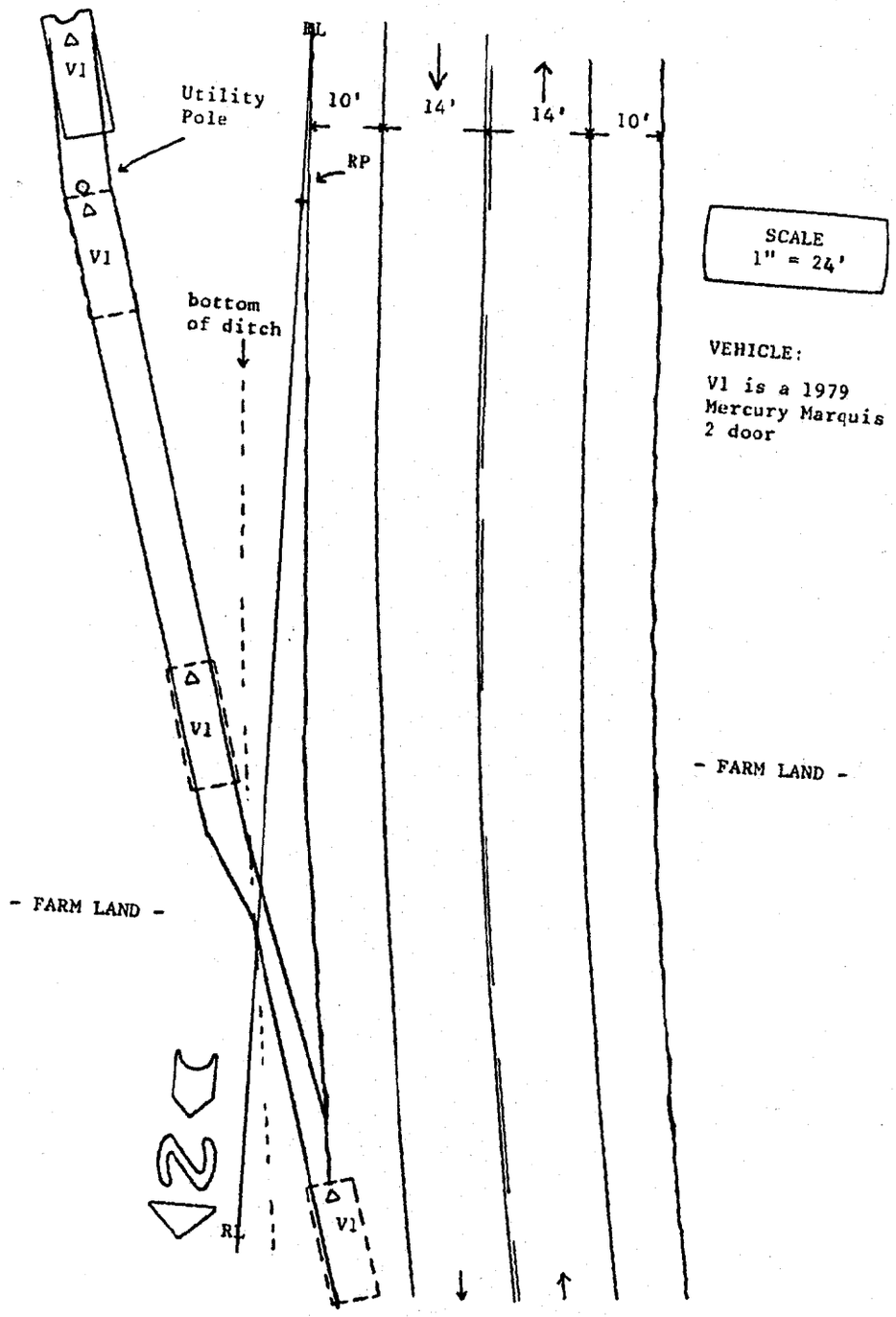

SELECTED PHOTOGRAPHS, CASE 361

1.



Scene photograph. V1 approach direction and new utility pole which replaced the pole broken by impact.

2.

V1 (1979 Mercury Marquis 2 door sedan). Frontal pole impact. Max Crush = 18 inches. Delta V = 12 to 20 m.p.h. (pole broke).

SELECTED PHOTOGRAPHS, CASE 361

3.

V1 interior. Driver contacted steering rim (AIS-2 abdomen & back) roof (AIS-3 head), rear view mirror (AIS-3 face).

4.



V1 interior. Driver contacted center instrument panel (face) and left instrument panel (knee). No resulting injuries noted.

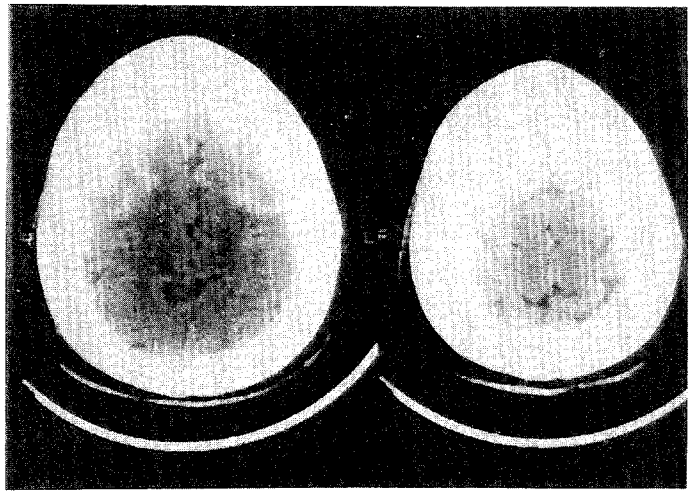

361A Head CT Scan revealing a right parietal subarachnoid hemorrhage.

Contact Point- Roof?
Type of Crash- Frontal impact
Estimated Force of Impact with Roof- 230 lbs.

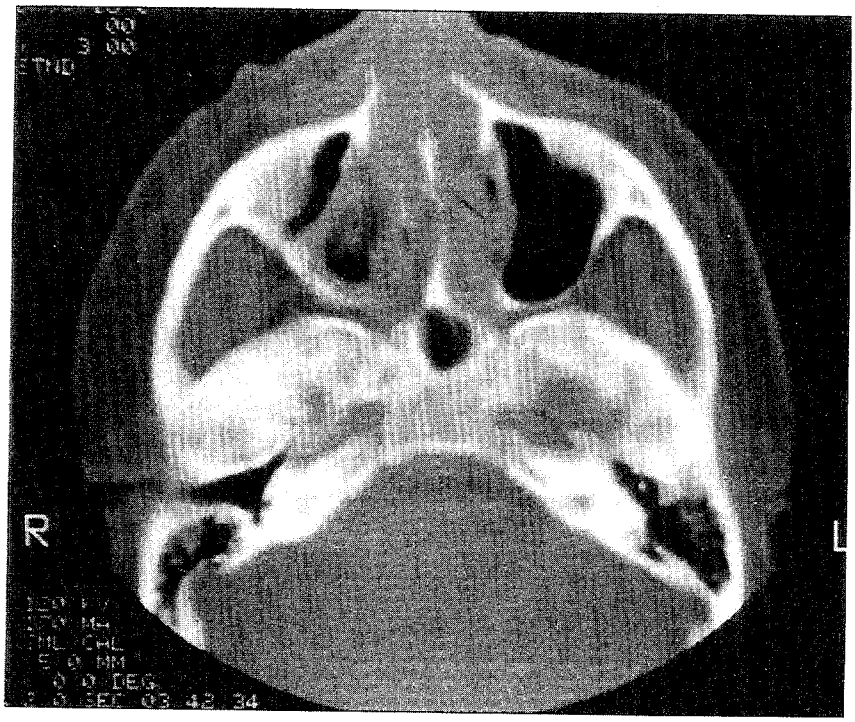

361B CT Scan revealing a nasal fracture and blood in the right maxillary sinus.

Contact Point- Rear view mirror??
Type of Crash- Frontal impact

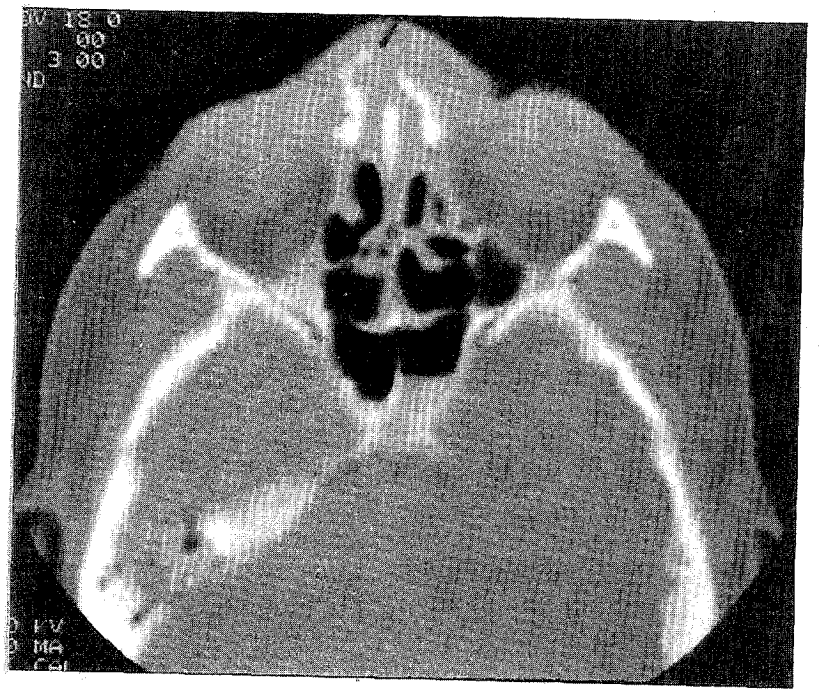

361C CT Scan revealing a left medial maxillary sinus fracture.

Contact Point- Rear view mirror
Type of Crash- Frontal impact

SUMMARY - CASE 251 (016)

This 2 vehicle accident occurred on a clear, spring, weekday afternoon. The accident involved a 1980 Toyota Celica ST 2 door coupe with one 54-year-old female occupant, and a 1985 Chevrolet Scottsdale 4x4 pickup with one 20-year-old male occupant. The accident was located at the intersection of a suburban arterial street and the northbound lanes of a major state highway. The arterial street has 1 eastbound lane, 1 westbound lane, and 1 eastbound "left turn only" lane which allows eastbound traffic to enter the 2 northbound highway lanes. The intersection is controlled by a semi-actuated signal using wire-type magnetic loop detectors. The Toyota, our case vehicle, was traveling west through the intersection. The Chevrolet was traveling east in the eastbound "left turn only" lane and attempting to turn north into the northbound highway lanes. The left front bumper of the Chevrolet contacted the left side of the Toyota just rearward of the left front bumper corner. The Chevrolet rotated counterclockwise into the Toyota's left side and came to rest approximately 14 feet from the point of impact after 90 degrees of rotation. The Toyota was pushed rearward and to the right at impact and came to rest approximately 7 feet from the point of impact. Maximum lateral crush to the left side of the Toyota was measured at 9.9 inches, however, the crush was centered at the A pillar which was the source of severe (AIS-5) head injury to the driver of the Toyota. The driver of the Toyota was using the available lap and shoulder belt. Both vehicles were towed from the scene with disabling damage. A complete list of injuries for this case is listed below in OIC format:

BODY CONTACTS AND INJURIES TABLE-Case 251
54 year old female; Driver; 1980 Toyota Celica; Side impact

OIC/AIS CODE	ICD-9	CONTACTS & INJURIES	CONTACT POINT
1. 2HLLI2 221101	873.0	Laceration, Left Temporal Parietal Scalp >= 5cm	Left A Pillar
2. 2HLFS3 221101	800.61	Fracture, Left Temporal Parietal Skull >= Skull Thickness with Lacerated Dura; Depressed	Left A Pillar
3. 2HLUB5 221101	800.71	Left Temporal Parietal Subdural Hematoma > 100cc	Left A Pillar
4. 2HIFS2 221101	801.01	Fracture, Basilar Skull, Left Middle Fossa	Left A Pillar
5. 2FLAO1 221101	918.0	Abrasion, Left Eyelid	Left A Pillar
6. 2FRAI1 221101	910.0	Abrasion, Right Malar Emminence	Left A Pillar
7. 2FLAI1 221101	910.0	Abrasion, Left Malar Emminence	Left A Pillar
8. 2FCFS4 221101	802.4	Lefort III Fracture; Right side	Left A Pillar
9. 2FLFS3 221101	802.9	Open Fracture, Left	Left A

			Inferior Orbit	Pillar
		802.4	Includes Left Zygoma Fracture	
10.	2HRAE1 222101	910.0	Abrasion, Left External Auditory Canal	Left A Pillar?
11.	2NPFS2 221201	805.02	Fracture, Cervical Spine C2 Odontoid Type I	Left A Pillar
12.	2KRLI1 101100	916.0	Laceration, Right Knee, 5cm	Instrument Panel; Center
13.	2KLLI1 091102	916.0	Abraded, Broken Plastic	Instrument Panel; Left
	UNKNOWN IF INJURED		Abraded Upper Left Rim (head or chest ?)	Steering Rim

PSYCHOSOCIAL SUMMARY - CASE 251

The patient is a 54-year-old female who was admitted to MIEMSS Shock Trauma after her car was hit by a small pickup truck whose driver had been drinking. The study patient was the driver and sole occupant and had been travelling home from work as a secretary at the U.S. Naval Academy. The patient sustained a depressed skull fracture and basal skull fracture with significant facial trauma.

The patient has been married for 33 years, having two married adult children and 5 grand-daughters. Family has had a long history of connection with the military services. Her daughter, who is visiting, is an officer in the Air Force. Her husband, a Korean War veteran, handles government contracts with military installations. The family has moved frequently throughout marriage, having resided in Maryland for the longest period of time-almost 14 years. However, due to the demands of jobs and history of relocation, the couple has few social outlets and remain an isolated unit dependent on one another.

The patient is described as a bright energetic woman, very independent and highly optimistic. She is also very close to husband and children, sharing an active role in the birth of her grandchildren.

The patient is also very health-conscious, adhering to proper diets, rarely using alcohol and is a non-smoker. The patient has developed a strong interest in marathon running and is almost obsessive about daily running and winning races. The family states that she has received great success from local and national running events and wins most of her races. The family feels that the patient's discipline, energy level and motivation will enhance her recovery from the brain injury. The family is adamant about taking the patient home versus continued therapy at a rehabilitation institute which is recommended.

The patient is a conscientious seatbelt wearer and had experienced no past traumas, having a good driving record. However, the patient experienced depression and years of

adjustment following her older brother's death which had a devastating effect on the patient in the early years of her marriage. Her husband and son have both been involved in serious auto collisions, but neither experienced major injuries.

CRASH TIMELINE - CASE 251

T - 2 seconds: This was a 2 vehicle accident which occurred on a clear, dry weekday afternoon. The accident involved a 1980 Toyota Celica ST 2 door coupe (V1) with one 54 year old female occupant, and a 1985 Chevrolet Scottsdale 4x4 pickup with one 20 year old male occupant. The accident was located at the intersection of a suburban arterial street and the northbound lanes of a major state highway. The arterial street has 1 eastbound lane, 1 westbound lane, and 1 eastbound "left turn only" lane which allows eastbound traffic to enter the 2 northbound highway lanes. Both roads are of asphalt construction, and the intersection is controlled by a semi-actuated signal which uses wire-type magnetic loop detectors. The skew angle of the intersection is 50 degrees from right angles, and the roads are relatively straight and level. The estimated coefficient of friction is .70. The northbound highway lanes are each approximately 12 feet in width and the highway is bordered by paved shoulders. The lanes of the arterial street vary in width between 11.6 and 15.1 feet. Both vehicles in this case were traveling on the arterial street which has a posted speed limit of 35 miles per hour. Just prior to impact, V2 was traveling east in the eastbound "left turn only" lane at an estimated speed of between 22 and 28 miles per hour. V2 was attempting to turn north into the northbound highway lanes. V1 was westbound and was crossing the intersection in the westbound lane. The driver of V1 was braking and steering to the right in an attempt to avoid V2. V1 was traveling an estimated speed of between 2 and 5 miles per hour just prior to impact. The driver of V1 was wearing the available manual lap and shoulder belt. The driver of V2 was not wearing the available manual lap and shoulder belt.

T - 0 seconds: The left front bumper corner of V2 contacted the left side of V1 just rearward of the left front bumper corner. The direction of force acting on V1 was approximately 32 degrees to the left of straight ahead. The maximum lateral crush to the left side of V1 was measured at 9.9 inches, however, there was a considerable longitudinal component to the impact. This is evidenced by "A" pillar intrusion. The left "A" pillar of V1 was intruded laterally 7.4 inches and longitudinally 12.5 inches. The head of the driver of V1 impacted the "A" pillar at maximum engagement. By this time, the impact related damage to the "A" pillar had caused the plastic "A" pillar cover to dislodge so that the driver's head contacted bare metal. Hair and tissue were found on this metal. The driver of V1 sustained several serious head and neck injuries (AIS-2 to AIS-5) as a result of "A" pillar contact. As V2 rotated counterclockwise into the left side of V1,

the left toe pan and left instrument panel of V1 intruded longitudinally 9 inches and 11.4 inches respectively. The knees of the driver of V1 contacted the left and center portions of the instrument panel and the driver did sustain bilateral knee lacerations. Abrasions were found on the upper left steering rim of V1 and the driver sustained an abrasion to the right cheek which was probably associated. Estimated speed change at impact for V1 was 24 miles per hour, however, the angle of the impact and the fact that the damage was centered at the "A" pillar did not work to the driver's benefit.

V2 sustained a maximum longitudinal crush of 19 inches to the extreme left front bumper corner. The direction of force acting on V2 was approximately 10 degrees to the left of straight ahead, but since V2 was turning left, it rotated counterclockwise approximately 90 degrees during impact and ultimately achieved full frontal contact to the left side of V1. No intrusion was noted to the interior of V2 and the only contact point was a bent upper steering rim due to driver hand loading. Estimated speed change at impact for V2 was 16 miles per hour.

T + .79 to 1.1 seconds: V1 was forced rearward and to the right after impact and came to rest approximately 7 feet from the point of impact and was still facing west. V2 rotated counterclockwise approximately 90 degrees after impact and came to rest approximately 14 feet from the point of impact and was facing north.

T + 1 minute: Police were notified of the accident.

T + 2 minutes: Police arrived at the scene.

PREHOSPITAL AND HOSPITAL TIMELINE - CASE 251

T+2min: Ambulance receives call to respond.

T+8min: Ambulance arrives at scene. Initial field assessment reveals a heart rate of 65 and a Glascow Coma Score of 12. Other ground ambulance data is unavailable. Ground prehospital care includes airway maintenance, spinal immobilization and administration of oxygen. The patient required extrication from the vehicle.

T+ 72min: Patient departs scene for MIEMSS/Shock Trauma by police medevac helicopter. Vital signs onboard the helicopter were blood pressure of 127/75, heart rate of 52, respiratory rate of 11 and a Glasgow Coma Score of 9. An intravenous line for crystalloid fluid administration was established on board the helicopter.

T+ 84min: Patient arrives at MIEMSS. Initial physiologic assessment of the patient reveals a blood pressure of 120/70, a heart rate of 60, a respiratory rate of 25, and a Glascow Coma Score of 13. The patient's ISS (Injury Severity Score) = 21. Toxicology screen results were negative. Initial hospital care provided includes:

-Evaluation by a MIEMSS trauma team,

-Fluid resuscitation,
-Peritoneal lavage with negative results,
-Full diagnostic evaluation including x-rays of the cervical spine, chest and pelvis. In addition to the toxicology screen, an arterial blood gas, a CBC (complete blood count), an SMA-6 (routine blood chemistry) and UA (urinalysis) were performed.

Initial clinical findings included the following:
-Depressed Left Temporo-Parietal Skull Fracture,
-Basilar Skull Fracture,
-Right Lefort III Fracture,
-Fracture of the Cervical Spine (C2),
-Left Zygoma Fracture,
-Nasopharyngeal Laceration,
-Lacerations to both knees.

Operative care includes:
-Evacuation of blood from the left cerebral hemisphere.

T+24hours - 18 days: Patient spends 14 days in critical care and 4 days in intermediate care. No complications were reported during the acute care hospitalization of this patient.

T+ 18 days: Patient discharged from MIEMSS to home with family against medical advice. MIEMSS physicians had recommended further treatment at an inpatient rehabilitation facility.

COGNITIVE-COMMUNICATIVE ASSESSMENT - CASE 251

The patient's cognitive-communicative skills were initially evaluated on T + 6 days. The patient had a tracheostomy and was given an electrolarynx. She was unable to attend for a very long period of time. Significant deficits were noted across all areas: auditory comprehension, written comprehension, verbal expression, speech and cognition. The patient was felt to be at an RLAS V level- confused and inappropriate response level (Rancho Los Amigos Score). Recommendations were for inpatient treatment of deficit areas. The patient's hearing could not be evaluated and she was NPO.

The patient received therapy for deficit areas and a discharge evaluation was given on T + 15 days as the patient was being considered for rehabilitation. At the time, the patient was speaking and able to complete the entire evaluation. Moderate deficits continued to be noted across all areas and patient was felt to be at an RLAS VI level- confused/appropriate response level. Recommendations were for the patient to receive inpatient rehabilitation. A mild to severe hearing loss was diagnosed and the patient was on a P.O. diet. The patient should be re-evaluated at 3 months post-discharge.

CRASH COMPARISON - CASE 251

Crash Test Data:

Initial runs on the crash test data base did not yield very much in useful data. Finally, after several trials some second vehicle data in crash tests was found that produced similar damage profiles. These crash tests were #088 and #205.

Data used here for crash curve comparison was the rear deck and firewall curves and then only the "X" axis proved useful.

Crash Test Curves:

The crash curves are shown at Figures 251-1 through 251-4. They show low G forces in action, averaging to 4 Gs or so at 60 milliseconds. This considering that the speed of the test vehicles was almost twice the actual speed at impact in this case. The G forces in the actual case must have been less than this.

Crash Test Injuries:

In the analysis of the injuries in the crash test, case 088 resulted in an HIC of only 122 and a CSI of 0. In this case the driver dummy was belted as in the actual case. In the #205 test, the occupant driver was not belted and an HIC of 1234 was recorded. Even unbelted, the crash test does not indicate an injury of the severity in the actual case.

A curve of the head center of gravity was not used because it was of little value since the direction of forces were a compound x and y direction toward the "A" pillar. Crash tests do not show this well in angular impacts.

Crash Significance:

This crash, involving a 54-year-old female at an intersection simply should not have been as severe in its injuries as the actual case was. The accident occurred at low speed with the crash victim in the case having slowed to less than 10 mph and the other vehicle barely starting to accelerate. The involvement of alcohol seems of little or no consequence in the injury other than as a contributing factor to the bad judgement involved in turning into it.

First of all the crash case was restrained and less than 1% of restrained occupants receive injuries of AIS 3 or more and only 1% are even hospitalized at all. Also, both the angular incidence of crash and the low speed account for less than 1% of even AIS 1 injuries, in fact only 27% of all crashes at 25mph or less account for any kind of injury.

Why, then was this one so severe? The basic answer has to lie in the coincidence of the pick-up truck hitting the car exactly at

the "A" pillar and thus causing the "A" pillar to collapse inward and intrude into the passenger compartment of the Toyota some 12 to 19 inches. This just as the driver was thrown forward by the impact. Again, as in some other cases we have seen (e.g. case 169) a particular event causes a part of the vehicle to intrude and cause serious injury and again it is the "A" pillar. Nothing else in this accident seems to be able to account for the AIS 5 injury severity. This case goes against all the statistics otherwise. By age, speed, road conditions, restraint use, sex and signal control conditions, this accident should not have been this bad. Maybe Toyotas (and other sedans) need roll-bar construction in the roof supports.

PSYCHOSOCIAL FOLLOW-UP - CASE 251

6 Months

This 54-year-old married white female was hospitalized at Shock Trauma for 18 days due to head injury, at which time the family decided to take the patient home to arrange own therapy program. Decision was taken against medical advice, however family adamant and confident in their ability to provide for patient. Patient felt discharge home with family gave her courage and desire to return to normal life.

At 3 months post-trauma patient had returned to part time employment and felt she was adjusting to same. Although family income decreased due to patient's loss of salary, spouse maintained a high income level. The financial costs have been great and include lost wages, psychotherapy, legal costs, purchase of used car, new glasses, teeth and undetermined expenditures.

At 6 months post-trauma patient describes her life as going very well and 98% return to pre-injury status. Patient returned to full time work 4 1/2 months post trauma and feels she has no cognitive deficits. Her work as a secretary involves much detailed work, e.g. entering data from chemistry exams and working with equations. Performance and judgment appears to be same as pre-injury. Patient exhibits a positive outlook and has strong religious belief system. Patient states she has returned to running and won a 12.4 mile race at 6 months post-trauma.

Patient's husband expects to retire within 6 months and family plans to move west to be with children. Patient has job lined up at military base there.

1 Year

Patient and husband, who retired, have relocated to West Coast where patient is employed full-time and doing well. Although experiencing some behavioral changes, e.g. irritability and nervousness, most of this is under control and relieved by exercise.

PREVENTION AND INJURY REDUCTION - CASE 251

This crash appears to have been purely a case in which the inattentive driver of the striking vehicle did not see the other vehicle. Our case obviously made an attempt to avoid the striking vehicle by steering to the right and decelerating. The primary reason for the severity of our case's injuries was the angle of the collision. Since our case was using the available manual lap and shoulder belt, given the Delta V (24 m.p.h.) she probably would have escaped major injury had the impact been concentrated at the front of her vehicle.

This is another example of the low Delta V/severe injury (AIS-5) combination that is occurring as a result of 11 O'clock side impacts which are centered at the "A" pillar. In this type of crash, the striking vehicle normally begins penetration along the left front fender. This fender offers little lateral or longitudinal resistance to the bumper corner of the striking vehicle, especially when the bumper corner comes in above the struck vehicle's left front wheel as in this case where the striking vehicle is a pickup truck. When the striking vehicle's bumper corner reaches the dashpanel (firewall) area, the "A" pillar is then pushed directly toward the driver of the struck vehicle. Couple this with the fact that the driver of the struck vehicle is being forced toward the "A" pillar, and the potential for severe head injury is very high. The left "A" pillar of our case vehicle intruded longitudinally 12.5 inches and laterally 7.4 inches. The question here is how far did the "A" pillar have to intrude to cause AIS-5 head injuries to a restrained driver. The worst injuries occurred at the left Temporal Parietal area of the skull. This suggests that the seatbelt may have been at its maximum locked travel and that the driver's head was moving forward and downward as a result. This type of head movement is easily seen in videotapes of crash tests using dummies. If the driver was in fact at or near the end of travel, then quite possibly 2 or 3 inches less intrusion at the "A" pillar and left instrument panel might have reduced her head and facial injuries substantially from the AIS-5, AIS-4 level.

The deployment of a steering hub mounted driver's Air Bag might have helped our case, although an "A" pillar mounted Air Bag would surely have reduced if not eliminated the head injuries. None of the latest interior safety devices can stop the severe consequences of catastrophic intrusion such as that which occurred in this case.

---- Jerry Jackson

PREVENTION COMMENTS - CASE 251

This patient was a 54-year-old female occupant of a 1980 Toyota Celica who was struck by a 1985 Chevrolet 4x4 pick-up with a male occupant who was under the influence of alcohol and made an inappropriate left turn into the patient, although she had the

right of way. It struck the patient's car on the left front, intruding the left frontal portion of the car and the A-pillar into the car. The patient was fully belted and sustained a fracture of the left temporo-parietal skull with a subdural hematoma as well as some abrasions of the left eyelid and the left and right malar eminences, and also suffered a LeForte III fracture with orbital component, all due to impact with the A-pillar. This patient demonstrates very clearly the value of a seatbelt, because although there was significant intrusion and the patient did have other injuries, they were not of major import; none of these were AIS-5, the brain injury is AIS-1 or 2, the skull injury is severe but this did not result in a profoundly disabling injury. She also had a small non-displaced fracture of the odontoid with no neurological deficit as well as some abrasions of the right knee due to impact with the instrument panel. In this case an airbag on the steering column or possibly at the A-pillar would have markedly protected this patient since the seatbelt prevented her from moving forward further. In addition, the car construction which would strengthen the A-pillar and protect the car from lateral crashes to a greater extent would have helped considerably by preventing intrusion. It is likely with a seatbelt without intrusion, the patient would have sustained no significant injury. Again, from a highway safety component, this type of turn of a two lane road with the potential of turning left into a one way road probably should have some kind of light or sign preventing individuals from turning till the on-coming lane has passed.

This crash occurred, in part, because the patient was moving from the on-coming lane to the nearest lane in the one way road and therefore crossed over in front of the our patient's vehicle in such a way as to insure a left frontal crash.

COLLISION SCHEMATIC, CASE251

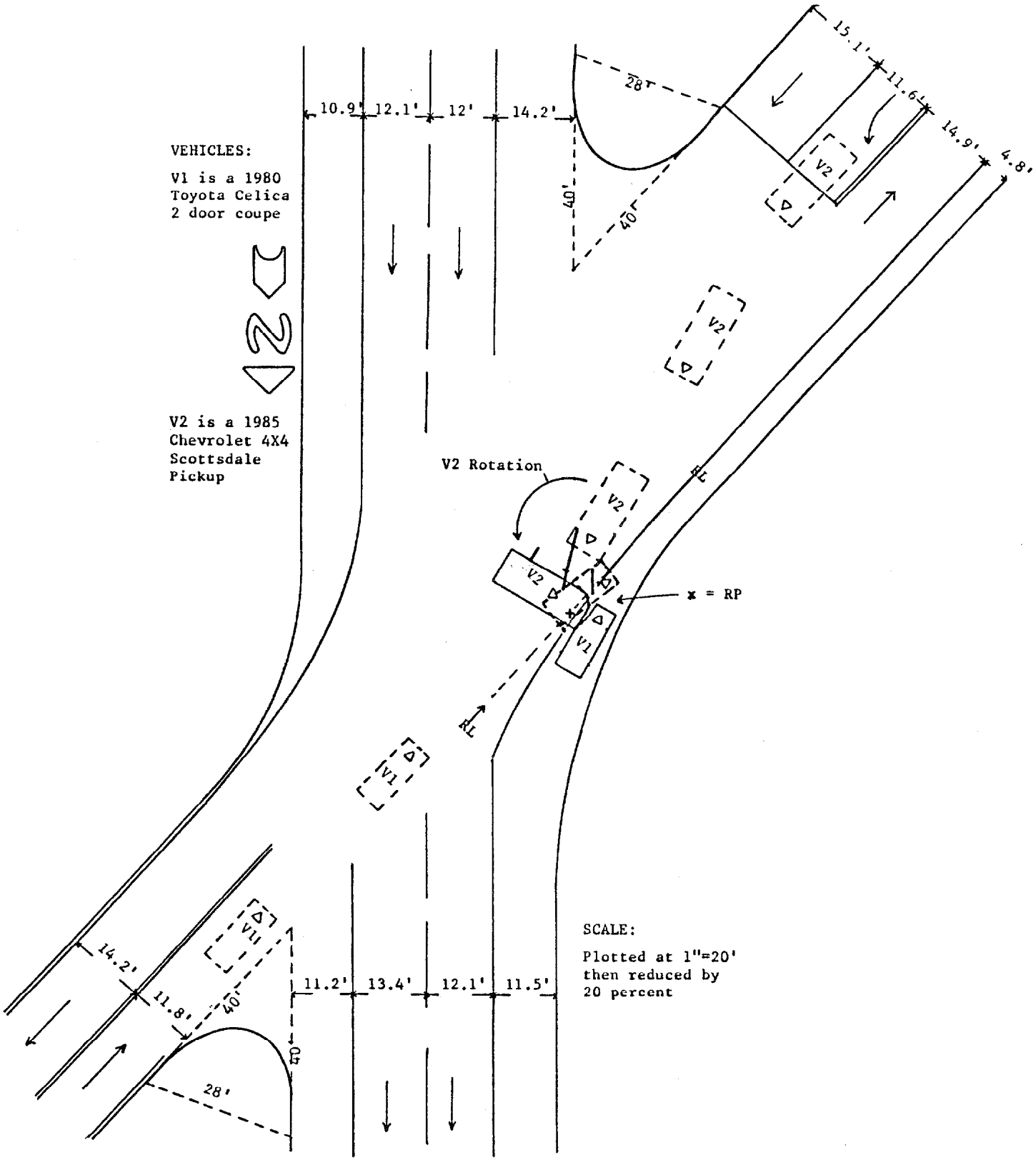

SELECTED PHOTOGRAPHS, CASE 251

1.

Scene. Intersection; 2-lane suburban arterial, 2 northbound lanes of a State Highway. V2 direction of travel, V1 approach direction

2.



V1 (1980 Toyota Celica ST 2 door). Left side impact from front. Max crush = 9.9 inches. Delta V = 24 mph. Latch failure LF door.

SELECTED PHOTOGRAPHS, CASE 251

251-25

3.



V1 left "A" pillar intrusion; 12.5" longitudinal, 7.4" lateral (AIS-4,3,2,&1 face, AIS-2 neck). Lap and shoulder belt in use.

251-35

4.



V2 (1985 Chevrolet Scottsdale 4x4 pickup). Front impact. Max crush = 19 inches. Delta V = 16 mph.

251A Multiple facial abrasions and left scalp lacerations (partially covered).

Contact Point- Left A Pillar
Type of Crash- Left lateral impact
Estimated Force of Impact- 640 lbs.



251B Cervical spine X-Ray revealing a C-1 odontoid fracture.

Contact Point- Left A Pillar
Type of Crash- Left Lateral Impact
Estimated Force of Impact- 640 lbs.

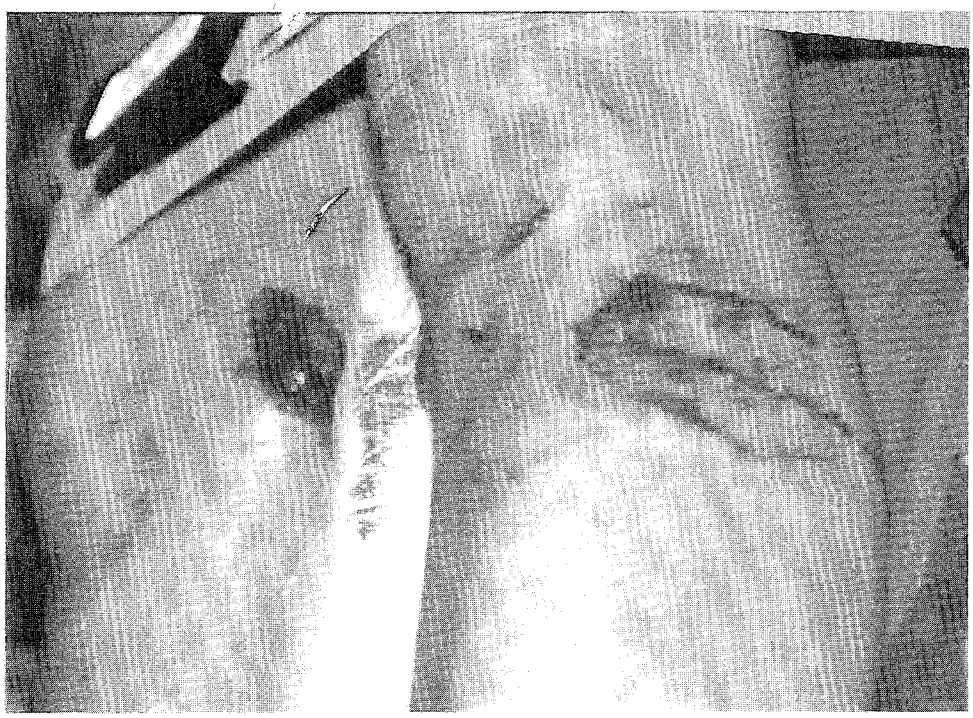

251C Bilateral knee and pretibial lacerations and abrasions.

Contact Point- Instrument Panel
Type of Crash- Left lateral impact

SUMMARY - CASE 226 (017)

This 2 vehicle accident occurred on a clear, spring, weekday afternoon. The accident involved a 1981 Chevrolet Malibu 5 door station wagon with a 66 year old male driver, a 14 year old female center front seat passenger, and a 26 year old male right side front seat passenger (our case). The other vehicle was a 1969 Ford Mustang 2 door coupe with one 35 year old male occupant. The accident occurred at the intersection of a 2 lane collector street and a 3 lane state highway. The collector street has 1 eastbound lane and 1 westbound lane, and it has stop signs which denote right of way to the state highway. The state highway has 2 southbound lanes and 1 northbound lane. Both roads are of asphalt construction and have double yellow paint lines in the center which deliniate 2-way traffic movement. The intersection, which is situated in a rural area, is bordered by grass, and sight distance is very good for all movements. The Chevrolet was eastbound in the eastbound lane of the collector street. The Ford was northbound in the northbound lane of the state highway. There was no evidence of pre-impact braking by either vehicle. The front of the Ford impacted the right side of the Chevrolet at a right angle. Maximum longitudinal crush to the front of the Ford was measured as 19.2 inches. Maximum lateral crush to the right side of the Chevrolet was measured as 26.7 inches. Both vehicles rotated clockwise at impact. The Ford was deflected to the northeast, impacted an 8 inch tall concrete curb, a 3.5 inch diameter wooden stop sign post, and came to rest approximately 53 feet northeast of the point of impact after approximately 62 degrees of clockwise rotation. The driver, who was using the lap portion of the available separate manual lap and shoulder belts, sustained moderate injuries. The Chevrolet was also deflected to the northeast at impact and came to rest approximately 100 feet northeast of the point of impact after approximately 205 degrees of clockwise rotation. The driver and center front seat passenger were not using the available manual restraints and both occupants sustained moderate injuries. The right front seat passenger was ejected through the right front door as the Chevrolet achieved final rest. This occupant was not using the available manual lap and shoulder belt, and he was seriously injured. A complete injury list for this case is listed below in OIC format:

BODY CONTACTS AND INJURIES TABLE-CASE 226

26 yr.old male; Right front passenger; 1981 Chev. wagon; side impact

OIC/AIS CODE	ICD-9	BODY CONTACTS AND INJURIES	CONTACT POINT
1. 2HWKB2 332101	854.06	Closed Head Injury with Loss of Consciousness and Amnesia of the Event	Right B Pillar?
2. 2SRFS2 301103	810.02	Fracture Right/Mid Clavicle	Right Front Door Panel

3.	2PAFS2	311103	808.2	Grade 1 Lateral Compression Pelvis Fracture Inferior Ramus - Bilateral	Right Front Armrest
4.	2WRLI1	111104	882.0	Laceration above Distal 3rd Metacarpal - Right Hand	Instrument Panel, Right
5.	2WRLJ2	111104	883.2	Laceration 5th Phalanx with Lacerated Extensor Tendon - Right Hand	Instrument Panel, Right
6.	2WRFS1	111104	816.11	Open Fracture 5th Phalanx - Right Hand	Instrument Panel, Right

PSYCHOSOCIAL SUMMARY - CASE 226

Psychosocial information could not be obtained for this study patient from either the patient or the patient's family. Although the patient arrived at MIEMSS/Shock Trauma and was conscious for most of his hospitalization, both the patient and family refused to be interviewed for purposes of the study.

CRASH TIME LINE - CASE 226

T - 2 seconds: This was a 2 vehicle accident which occurred on a clear weekday afternoon. The accident involved a 1981 Chevrolet Malibu 5 door station wagon (V1) with a 66 year old male driver, a 14 year old female center front seat passenger, and a 26-year-old male right side front seat passenger (our case). The other vehicle was a 1969 Ford Mustang 2 door coupe (V2) with one 35 year old male occupant. The accident occurred at the intersection of a 2 lane collector street and a 3 lane state highway. The collector street has 1 eastbound lane approximately 15 feet in width, 1 westbound lane approximately 13 feet in width, and it has stop signs which denote right of way to the state highway. The state highway has 2 southbound lanes and 1 northbound lane each approximately 12 feet in width. Both roads are of asphalt construction and have double yellow paint lines in the center which deliniate 2-way traffic movement. The intersection, which is situated in a rural area, is bordered by grass, and sight distance is very good for all movements.

V1 was eastbound in the eastbound lane of the collector street and was traveling an estimated speed of between 36 and 42 miles per hour. V2 was northbound in the northbound lane of the state highway and was traveling an estimated speed of between 65 and 67 miles per hour. None of the 3 occupants in V1 were using the available manual restraints. The driver of V2 was using the lap portion of the available separate manual lap and shoulder belts.

T - 0: The front bumper of V2 impacted the right side of V1 in the northbound highway lane. Since V1 had considerable

momentum, the direct damage to the right side was 142.5 inches wide. This damage pattern is evidence that V1 moved longitudinally across the front of V2 as the front of V2 intruded laterally into the side of V1. Maximum lateral crush to the right side of V1 was measured to be 26.7 inches in the "B" pillar area. Estimated speed change at impact for V1 was between 24 and 28 miles per hour. At impact, the right front door of V1 intruded laterally 11.4 inches. Occupant contact points were found on the armrest, upper door panel, and lower door panel. The right front seat passenger sustained pelvic and shoulder fractures due to door panel contact. There was blood and scratched and torn fabric found on the right edge of the right instrument panel and also on the portion of the right front door panel that rests against this edge when the door is closed. Evidence suggests that the right front passenger's right hand was caught in this space as he braced himself for the impact. The right front passenger did sustain lacerations and an open finger fracture to the right hand. The right rear door panel and "B" pillar were intruded laterally 14.6 and 15.3 inches respectively, however, the rear bench seat was folded forward in order to accommodate the estimated 500 pounds of cargo which was onboard. The right "A" pillar was intruded laterally 3.5 inches and was contacted by either the right front passenger or the center front passenger. Hair and skin from the center front passenger were found on the interior roof surface. Given the forces acting on V1, the "A" pillar would have been in the path of the center front passenger's head movement. The right instrument panel was intruded longitudinally 4.5 inches and the glove box door was contacted by both the right and center front passengers. There was abraded fabric on the center instrument panel which was caused by knee contact from the center front passenger. The driver of V1 loaded the steering rim and contacted the left instrument panel and rear view mirror. V1 began clockwise rotation at impact and was deflected to the northeast.

V2 sustained a maximum longitudinal crush of 19.2 inches to the front bumper. Both frame rails were shifted to the right and there was direct damage extending 38 inches down the left front fender. This damage pattern suggests a substantial lateral component to the forces acting on V2 at impact. The driver of V2 impacted the left front door panel and left roof siderail. The left front door was bowed outward and its latch was near failure. The driver of V2, who was observed 1 day after the accident, was favoring his left leg and was wearing a neck brace. Speed change at impact for V2 was estimated at between 30 and 35 miles per hour. V2 rotated clockwise at impact and was deflected to the northeast.

T + 2.01 seconds: After impact with V2, V1 was deflected at an angle approximately 40 degrees to the left (northeast) of its original eastbound direction of travel. V1 traveled approximately 78 feet, and had rotated clockwise approximately 200 degrees when it departed the northeast corner of the intersection and impacted a gradually sloping concrete drainage ditch. At this point,V1 was

in a broadside slide and facing northeast. This impact occurred at the right front and right rear wheels and the vehicle continued across the ditch in a broadside slide. The left front and left rear wheels then impacted the ditch and the left rear wheel was dislodged. The forces acting on the occupants of V1 would have again pulled them to the right side of the vehicle interior. A smudge of blood was found on the right "B" pillar which indicates a head impact from the right front passenger. This evidence suggests that the right front passenger was already bleeding from the head as a result of the impact with V2.

T + 2.18 seconds: After traveling approximately 45 feet and rotating clockwise approximately 62 degrees, V2 impacted an 8 inch tall concrete curb. V2 then traveled an additional 4 feet and came to rest on a small raised island after contacting a 3.5 inch wooden stop sign post at the driver's door. The driver was transported to a hospital for treatment.

T + 3.54 seconds: After the drainage ditch impact, V1 continued in a broadside slide across a grass surface for an additional 15 feet and came to rest facing northeast. The right front passenger was apparently ejected through the failed right front door at a point very near V1's final rest position. V1 had rotated a total of approximately 205 degrees while traveling a total distance of approximately 100 feet after impacting V2. All 3 of V1's occupants were transported to hospitals for treatment.

T + 30 seconds: Police were notified of the accident.

T + 1 minute: Police arrived at the scene.

PREHOSPITAL AND HOSPITAL TIMELINE - CASE 226

T+ 4min: Ambulance receives call to respond.

T+ 16min: Ambulance arrives at scene. Initial field assessment reveals a blood pressure of 110/palp, a heart rate of 80, a respiratory rate of 19, and a Glascow Coma Score of 15. Prehospital care includes fluid resuscitation with the administration of 100cc of crystalloid, spinal immobilization, and monitoring of vitals. The patient required extrication from the vehicle.

T+45min: Patient departs scene for MIEMSS/Shock Trauma by police medevac helicopter. Oxygen was administered to the patient onboard the helicopter as well.

T+ 55min: Patient arrives at MIEMSS. Initial physiologic assessment of the patient reveals a blood pressure of 167/88, a heart rate of 104, a respiratory rate of 22, and a Glascow Coma Score of 15. The patient's ISS (Injury Severity Score) = 17. Toxicology screen results were negative. Initial hospital care provided includes:

-Evaluation by a MIEMSS trauma team,

-Fluid resuscitation,

-Full diagnostic evaluation including x-rays of the cervical spine, chest and pelvis. In addition to the

toxicology screen, an arterial blood gas, a CBC (complete blood count), an SMA-6 (routine blood chemistry) and UA (urinalysis) were performed.

Initial clinical findings included the following:

-Closed head injury with loss of consciousness,
-Laceration of right eyelid,
-Laceration to dorsum of nose,
-Fracture of the Right clavicle,
-Type I/Left Lateral compression fracture of the pelvis (Transverse/Inferior, Bilateral rami),
-Open fracture of the right fifth proximal phalanx with laceration to the extensor tendon.

Operative care included:

-Open reduction of the right phalanx fracture.

T+24hours - 9days: Patient spends 2 days in intensive care and 7 days in intermediate care. No complications were reported during the patient's acute care hospitalization.

T+ 9days: Patient discharged from MIEMSS to home, unable to ambulate.

COGNITIVE-COMMUNICATIVE ASSESSMENT - CASE 226

The patient was initially evaluated for cognitive-communicative abilities across four sessions due to his fatigueability (T + 1 day, T + 3 day, T + 6 day, T + 9 day) The patient reported that he was diagnosed as learning disabled in school. He was unable to write due to his fractured right hand. The patient exhibited mildly reduced auditory comprehension and verbal expression skills. Speech and cognitive skills appeared to be within normal limits. Written expression could not be assessed. The patient aeared to be at an RLAS (Rancho Los Amigos Scale) VIII level. No treatment was indicated and the patient was discharged home with a recommendation that he return in 1 to 2 weeks for a re-evaluation. The patient's hearing and swallowing were within normal limits.

The patient did not return for his scheduled outpatient clinic appointment and was thus not re-evaluated. Re-evaluation will be attempted in three months.

CRASH ANALYSIS - CASE 226

Crash impulse data was not available at the time of this case write-up. The crash comparison can be found in the simulation portion of the case history.

Significance of the Case:

This individual stood a very good chance of being a fatality. About 60% of the acidents with conditions such as these are

fatal. 49% of the fatal accidents at the junction of collector and state highways occur at stop signs as in this case. This case involved no use of restraints and the case occupant was in the right hand seat. His being ejected is no surprise since the door failed when hit from the right side and he was ejected just before the car skidded to a halt. Almost all ejected passengers sustain injuries of at least AIS 1 and 45% sustain injuries of at least AIS 3. Angle crashes are responsible for an AIS of greater than or equal to 121 % of the time and greater than or equal to 3 1% of the time.

The conditions surrounding the crash are fairly common. 43% of rural passenger car crashes are at a speed of 55 MPH or more and the right hand seat occupant is severely injured 48% of the time. Also, 11% of all right seat occupants are injured by the side interior AIS >= 1 with another 11% injured AIS >= 3.

In summary, this is a common type of crash with a set of fairly predictable injury results. The combination of high speeds, stop signs, angular hits, rural highway and passenger ejection are all high probability events. The extent of injuries suffered are certainly consistent with what the statistics say will be injury severity under these conditions.

PSYCHOSOCIAL FOLLOW-UP - CASE 226

No follow-up as patient refused to participate in study.

PREVENTION AND INJURY REDUCTION - CASE 226

This collision occurred at the intersection of 2 roads. This opens many possibilities in the area of prevention. This particular intersection uses the largest standard stop sign size (48 inch diameter), and the signs are positioned for the best possible visibility. From a Traffic Engineering standpoint, the next step in control would be the placement of a warning sign to alert motorists of the stop sign ahead, however, this must be justified by a situation of limited sight distance. That situation does not exist at this intersection. The next step would be to install a red continuously flashing light above the intersection. The light would be directed toward motorists who were approaching on the minor street. Obviously, this installation costs a substantial amount of money and can usually only be warranted by an excessive accident history at the intersection. The other alternative is the installation of either a semi or fully actuated signal. A semi-actuated signal responds to the minor street traffic only when minor street traffic is present and only after the major street has completed a preset green cycle. A full-actuated signal also responds to minor street traffic only when present, but can vary the length of the major

street green cycle depending on traffic volume. Naturally, I would recommend a full-actuated signal for this location due to its close proximity to a large workplace which generates very high traffic volumes periodically. The unfortunate truth is that these signals are very expensive and in most cases only the intersections with the highest traffic volumes and/or worst accident histories can be fitted with them.

Even with the addition of signals, the intersection is still subject to accidents. This damage in this crash is very similar to that in case 199. In case 199, a Delta V of 30 miles per hour caused complete "B" pillar separation and 32 inches of lateral right door panel intrusion. In this case, a Delta V of about 26 miles per hour caused 15.3 inches of lateral intrusion at the "B" pillar, but not a complete "B" pillar separation. Once the "B" pillar separates, the energy required to cause additional lateral intrusion is relatively low. Had there been complete "B" pillar separation in this crash, our case may well have been fatally injured.

An armrest mounted Air Bag system which has its deployment keyed to lateral forces would have been very helpful in reducing this case's injuries, but the worst problem associated with this crash is the occurrence of latch failure. Crash Team photograph number 25 shows how the door latch was torn from the "B" pillar. It is a matter of pure luck that this latch failure did not result in the death of our case. As the case vehicle was spinning toward final rest, our case's door was open. He could have been ejected into the path of his own vehicle. Luckily he was ejected away from the vehicle and at a very low speed.

PREVENTION; Increase the lateral strength in passenger cars and supplement it with active and passive restraints.

--- Jerry Jackson

PREVENTION COMMENTS - CASE 226

This patient was a 26 year old male right front seat passenger in a 1981 Chevrolet Malibu 5-door station wagon which was struck on the right side at and slightly behind the passenger seat by a car coming down a three lane highway, so this was a front to lateral crash. The passenger was not wearing a seatbelt, there was no airbag in the car, and he was partially ejected form the car but there is some note about extrication. The cars were rotated and fortunately the patient was not ejected into the path of another vehicle. He sustained a closed head injury with loss of consciousness, but Glasgow Coma Scale was 15. There was a laceration of the eyelid and also the dorsum of the nose, and a fracture of the right clavicle which appears to have been related to the front door panel. The head injury seems to be related to impact with the right B-pillar. There was also a Grade I lateral compression pelvic fracture indicating a classic pattern of head injury with lateral compression fracture. There were also some lacerations of the distal third metacarpal and

phalanx, both on the right hand and an open fracture on the right hand from impact with the instrument panel.

This case might have been prevented if there was some kind of device which either forced the car to stop before entering the three lane highway such as a warning sign, a stop sign, or an actual signal which gave clear right of way to the vehicles coming. Also, use of a seatbelt would have prevented patient from exiting the car and perhaps would have reduced the impact with the B-pillar somewhat, although probably not. A lateral airbag of some sort or very extensive padding of the support pillars might have reduced the head injury. The pelvic fracture would have been reduced in severity and perhaps prevented entirely, since it was a Grade I pelvic fracture, if there had been protection against lateral intrusion injuries by strengthening the lateral side of the car with the roll-cage concept.

COLLISION SCHEMATIC
CASE 226

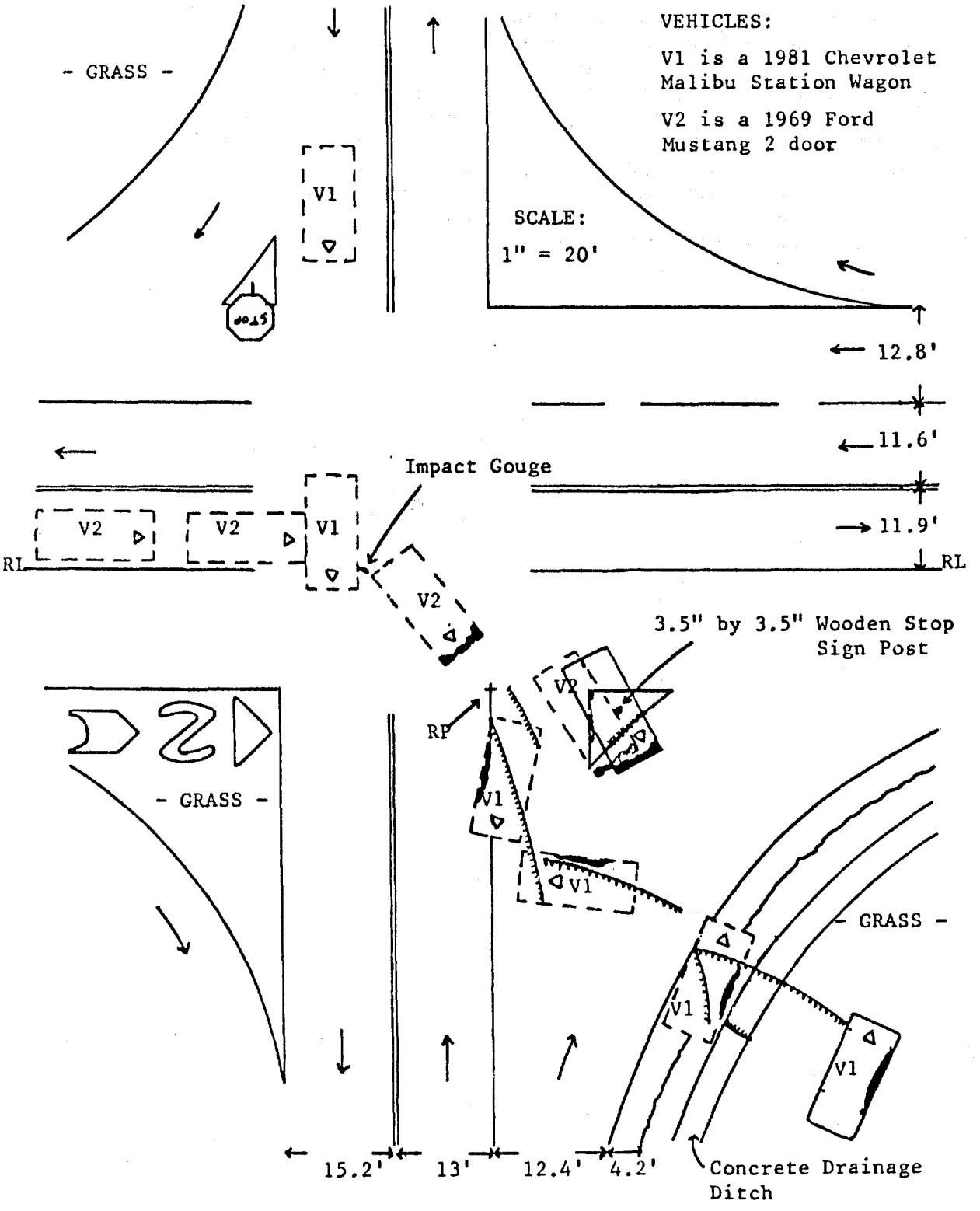

SELECTED PHOTOGRAPHS, CASE 226

226-09

1.

Scene. Intersection; 2-lane collector and 3-lane State Highway. V2 direction of travel. V1 came from stop sign on the left.

226-20

2.

V1 (1981 Chevrolet Malibu) Side impact. Max crush = 26.7". Delta V= 24-28 mph. Right front door (latch failure) intrusion= 11.4".

SELECTED PHOTOGRAPHS, CASE 226

3.

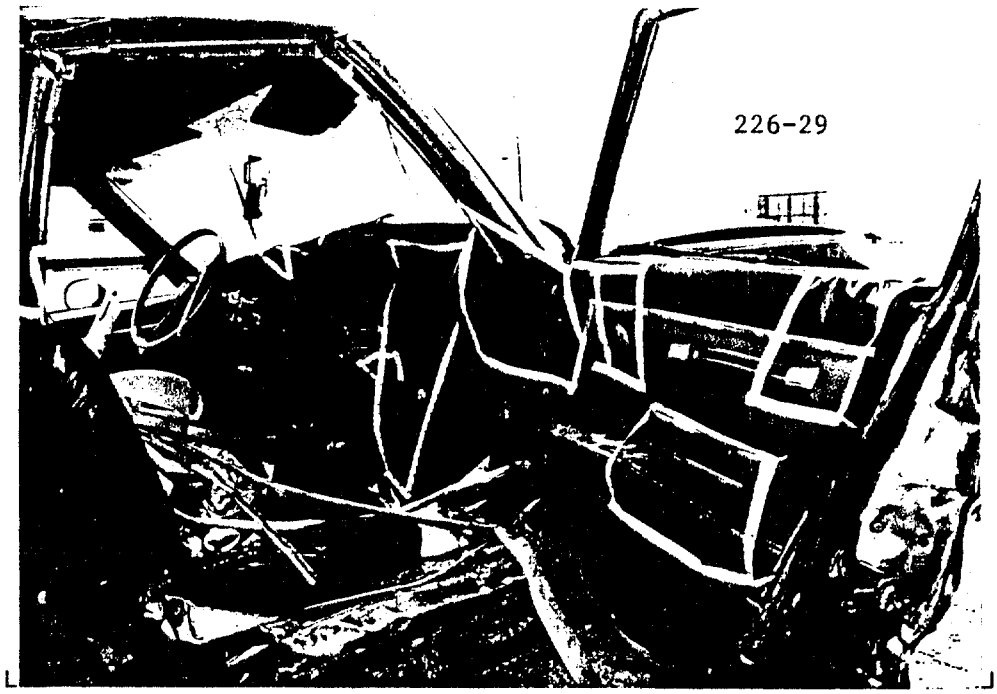

V1 RF passenger seat. Ejected, not restrained. Door(AIS-2 pelvis/ clavicle). Instrument panel (AIS-2&1 hand). B pillar (AIS-2 head)

4.



V2 (1969 Ford Mustang 2 door). Front impact. Max crush = 19.2 inches. Delta V = 30-35 m.p.h.

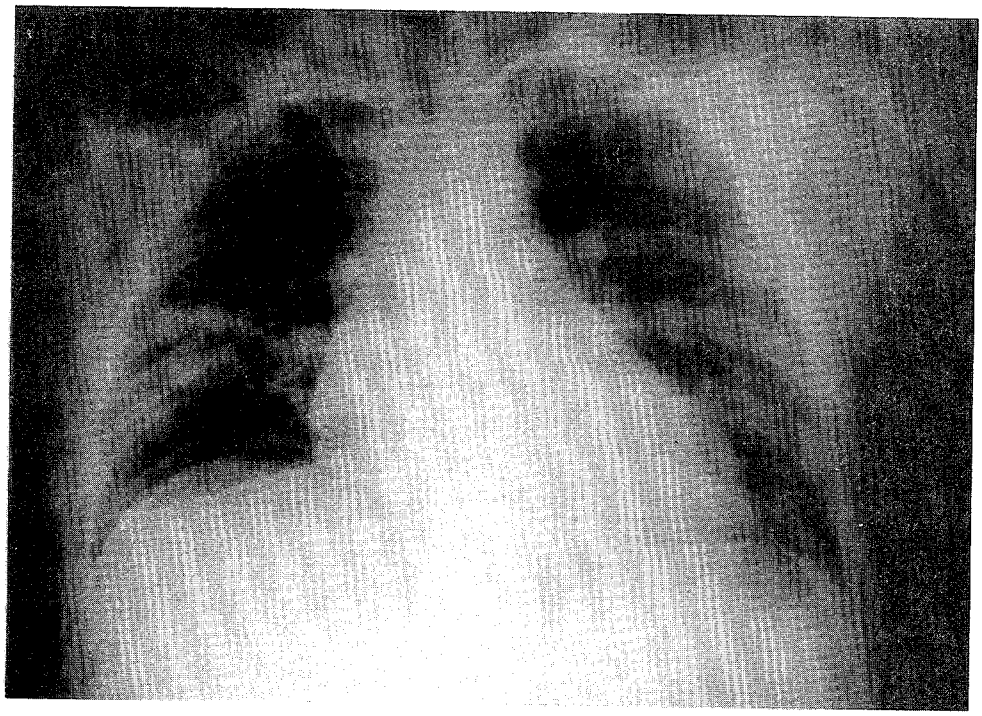

226A X-Ray revealing a transverse, midshaft fracture of the right clavicle and small amount of subcutaneous air in the left chest and a chest tube placed in the right pleural space for treatment of a pneumothorax.

Contact Point- Right front door panel
Type of Crash- Right lateral impact

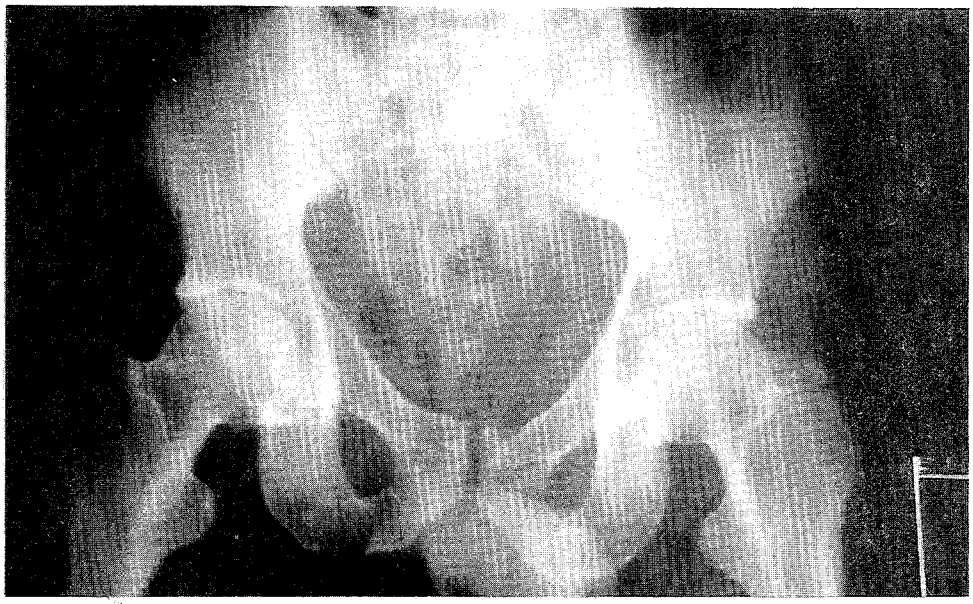

226B Prereduction pelvic X-Ray revealing a lateral compression/Grade I fracture of the pelvis. The transverse fracture of the left inferior pubic ramus is consistent with the application of a lateral force.

Contact Point- Right front armrest
Type of Crash- Right lateral impact

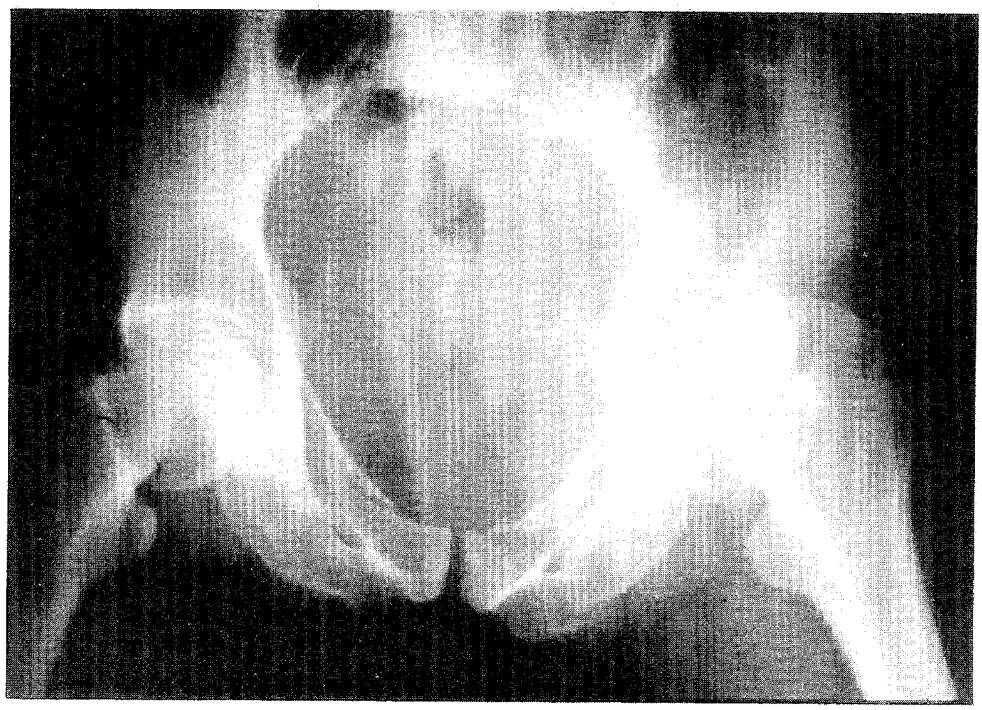

226C A Judet X-Ray of the same pelvis from a different angle revealing the transverse nature of the pubic ramus fractures that occurred as a result of a force applied laterally.

Contact Point- Right front armrest
Type of Crash- Right lateral impact

SUMMARY - CASE 427 (018)

This single vehicle accident occurred on a rainy, spring, weekday night. The collision involved a 1967 Chevrolet Malibu 2 door sedan with a 39 year old male driver, a 36 year old female right front seat passenger (our case), and a 14 year old male middle rear seat passenger. None of the occupants were using the available manual lap belts. The vehicle (V1) was southbound on a winding 2 lane rural asphalt road. The roadway was wet and had an estimated coefficient of friction of .5. V1 entered a right hand curve which had a radius of approximately 349 feet. V1 began to sideslip to the left, crossed the double yellow center stripe, and departed the roadway to the left. At this point, V1 was traveling an estimated speed of between 32 and 38 miles per hour. V1 continued south another 51.6 feet and impacted a 26 inch diameter tree with its front bumper. V1 rotated clockwise slightly and came to rest fully engaged with the tree and still facing south. The principal direction of force acting on V1 was approximately 20 degrees to the left of straight ahead, or 11 o'clock from the occupants' perspectives. Estimated speed change at impact was between 17 and 25 miles per hour. V1 had a maximum longitudinal crush of 30.7 inches to the front bumper. The "A" pillars were cut and the roof was folded back by rescue personnel. Upon inspection, V1 was pulled from a pile of junk cars and was found to have extensive after crash damage. The driver reportedly sustained non-incapacitating injuries. The middle rear seat passenger was reported as possibly injured, and the right front seat passenger (our case) sustained several serious (AIS-3) leg fractures. All injuries sustained by this case are listed below in OIC format.

BODY CONTACTS AND INJURIES TABLE-CASE 427
36 year old female; Right front passenger; 1967 Malibu; Front impact

	OIC/AIS CODE	ICD-9	CONTACTS OR INJURIES	CONTACT POINT
1.	2HWKB2 111199	854.00	Closed Head Trauma	Upper Right Instrument Panel
2.	2FSAI1 111199	910.0	Abrasions, Left Forehead	Upper Right Instrument Panel
3.	2FRAO1 111199	918.0	Abrasions, Right Eyelid	Upper Right Instrument Panel
4.	2FCAI1 111199	910.0	Abrasions, Nose	Upper Right Instrument Panel
5.	2FCLI1 111199	873.21	Laceration Nose, Septum	Upper Right Instrument Panel
6.	2FCFS1 111199	802.0	Nasal Fracture	Upper Right Instrument

				Panel
7.	2FILI1 111199	873.44	Laceration, Chin	Upper Right Instrument Panel
8.	2LWAI1 111199	911.0	Multiple Abrasions, Chest, Bilateral	Middle Right Instrument Panel
9.	2ELLI1 111199	881.01	Laceration, Left Elbow	Middle Right Instrument Panel
10.	2ILFS3 121199	821.01	Fracture, Left Femur, Midshaft/ Transverse	Glove Box Door
11.	2LLFS3 112199	823.32	Fracture, Left Tibia and....	Lower Right Instrument Panel?
12.	2LLFS3 112199		Left Fibula, Mid 1/3, Open/ Comminuted/ Grade III (both bones)	Lower Right Instrument Panel?
13.	2LLU A1112199	904.53	Hemmorhage & Ischemia, Left Posterior Tibial Artery	Lower Right Instrument Panel?
14.	2LLFS2 672199	824.2	Fracture, Left Fibula, Distal/ Oblique	Exposed Chassis Frame Rail?
15.	2QLZJ3 672199	825.31	Fracture, Left Talus, Proximal Articular Surface, Comminuted/ Open/ Grade III, and..	Exposed Chassis Frame Rail?
		838.11	Dislocation, Posterior Left Talus, Open with Vascular and Multiple Ligament Injury	

PSYCHOSOCIAL TIMELINE - CASE 427

A 36-year-old married female was admitted to MIEMSS Shock Trauma after the car in which she was a front-seat passenger missed a curve on a rural roadway a short distance from home. The patient stated that she anticipated the impact, bracing hands on dashboard and bracing foot firmly on the floor. Her husband, the driver of the car, had been drinking prior to the collision. The patient has total recall of the collision, indicating her foot went through the floorboard hitting the floorboard, and sustaining an open fracture of the foot. Her head and nose hit under the dash where the patient was trapped, sustaining a fractured nose. A home computer which had been in the back seat was forced against the seat back, preventing movement. Also in the car was a 14-year-old son who was in the back seat and was uninjured. The patient's husband suffered jaw and foot injuries but refused medical care until 1 week post-injury at which time he was evaluated and later admitted to a university hospital for

treatment. None of the occupants were said to have been wearing seatbelts.

The patient has been married for 20 years, having two sons, ages 17 and 14. She describes her early marriage as troublesome due to husband's abuse of alcohol and infidelity. She feels that this has since been resolved. Patient denies husband has a drinking poroblem, feeling his use of alcohol to be sporadic and indicates he only had a few drinks prior to the accident. The family had been visiting the husband's sister, picking up the home computer so the patient could begin to study and utilize for public relations work she was planning to do. The patient is very supportive of husband, stating that the marriage is a stable one and that they have a close-knit relationship. Patient denies any violence in the marriage, although readily admits to an abusive and difficult childhood, one of both physical and sexual abuse that has left its scars. The patient however, has sought out private and group therapy and is a very active leader of a group dealing with survivors of incest.

The patient's father hitchhiked here from Florida and the patient accepted his concern and visit as an effort to mend the hurt between them. The patient's mother was unable to make the trip due to chronic illness. Parents on fixed income (SSD) and arrangements made for father to return to Florida through Travelers Aid.

The patient is the oldest of four children, a younger brother was killed 15 years ago due to a hit-and-run MVA. She has another brother living in a Midwestern nursing home after being paralyzed four years ago following a mugging. A sister has recently separated from her husband and is now expecting a second baby. This sister is living with parents, necessitating the father's return home.

The patient quit high school due to family problems, although has since received a General Equivalency Diploma and has a variety of positive work experiences, developing skills in fundraising, public education, managing grocery store and working as a waitress. Her husband does seasonal carpentry work at present. Neither have medical insurance coverage and are in the process of applying for medical assistance.

The patient describes self as an avid reader and self-motivator, acting as a central force within the family system. The patient thrives on chaotic lifestyle and resolving each problem as it arises. She denies any use of drugs or alcohol and although concerned about the possible loss of her foot, views the future in a positive way, making the best of her situation as she has done in the past.

The patient was discharged at T + 17 days.

CRASH TIME LINE - CASE 427

T - 2 seconds: This was a single vehicle accident which

SUMMARY - CASE 420 (028)

This single vehicle collision occurred on a clear, summer, weekday morning. The vehicle was a 1989 Ford Escort, Pony, 2 door sedan with an 87 year old male driver, a 23 year old male right front seat passenger, and a 77 year old female right rear seat passenger (our case).

The roadway is a major urban/residential arterial street which has 2 southbound lanes and 2 northbound lanes. The movements are separated by a 25 foot wide curbed grass median, however, in the area of the collision, the southbound lanes curve to the west which increases the width of the grass median. The radius of the curve is approximately 720 feet as measured in the center of the outside southbound travel lane. The roadway is of asphalt construction and has a negative 4 percent southbound vertical slope. The surface was dry at the time of the collision and had an estimated coefficient of friction of .7. The posted speed limit was 30 miles per hour. The vehicle was southbound in the outside southbound lane. As the road began curving to the right, the vehicle continued traveling due south and crossed the inside southbound lane, impacted a continuous 6 inch high concrete curb, and rolled across the grass median. The front of the vehicle impacted a brick "gazebo" type building. The impact was centered at a brick corner pillar which was displaced 3 inches during the collision. Maximum longitudinal crush to the front of the Ford was measured to be 27.2 inches and the estimated speed change at impact was 33.9 miles per hour. The driver and right front seat passenger were forced forward at impact. Both of these occupants were using the available automatic 2 point shoulder belts as well as the available manual lap belts. The driver was reportedly killed, and the right front seat passenger reportedly sustained incapacitating injuries. The right rear seat passenger was also forced forward at impact and she was not using the available manual lap belt. She sustained head and facial injuries up to AIS-4 in severity, and extremity fractures, lacerations, and abrasions up to AIS-3 in severity. She was transported to a trauma center for treatment and the vehicle was towed from the scene with disabling damage. A complete list of injuries for this case is included below in OIC format:

BODY CONTACTS AND INJURIES TABLE-CASE 420

77 year old female; Right Rear Passenger; 1989 Ford Escort; Frontal

OIC/AIS CODE	ICD-9	BODY CONTACTS AND INJURIES	CONTACT POINT
1. 2HWKB2 401101	854.00	Closed Head Injury with;	Back of right front seatback upper left
2. 2HUUB4 401101	852.20	Small Subdural Hemmorhage of the Falx	Back of right front seatback

126G Operative photo revealing fractured left calcaneus and the partial traumatic amputation of 2/3 foot.

Contact Point- Floor pan and front interior (floor pan split open from intrusion and rust)
Type of Crash- Frontal impact

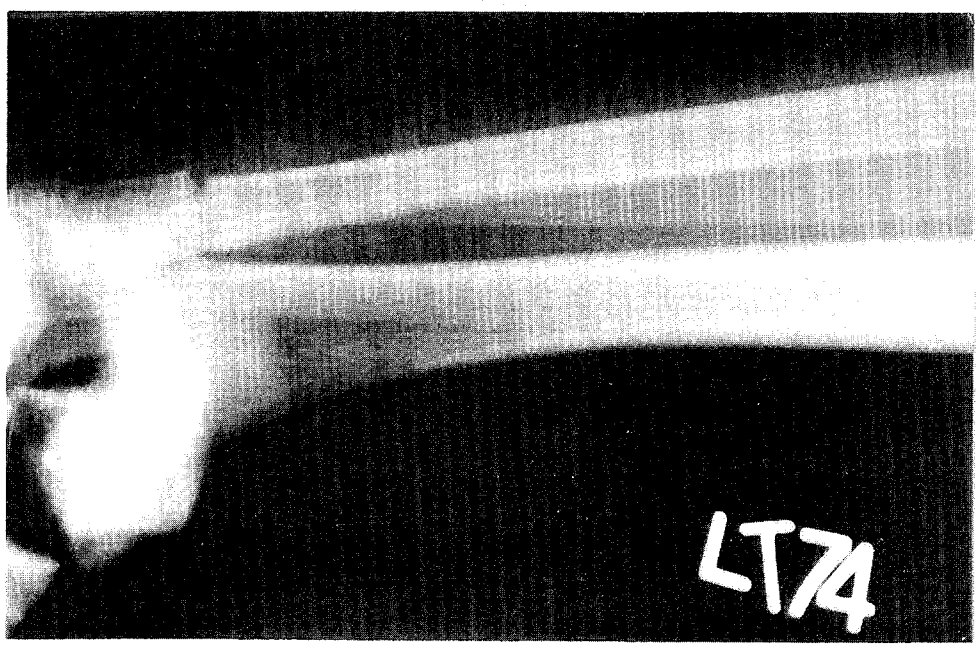

126E X-Ray revealing open fractures of the left lower 1/3 tibia and fibula.

Contact Point- Front interior including instrument panel and impact forces associated with intrusion and front of Vehicle 2.
Type of Crash- Frontal impact

126F Operative photo revealing open fracture of the right calcaneus and partial traumatic amputation of the right foot.

Contact Point- Floor pan and front interior (floor pan split open from intrusion and rust)
Type of Crash- Frontal impact

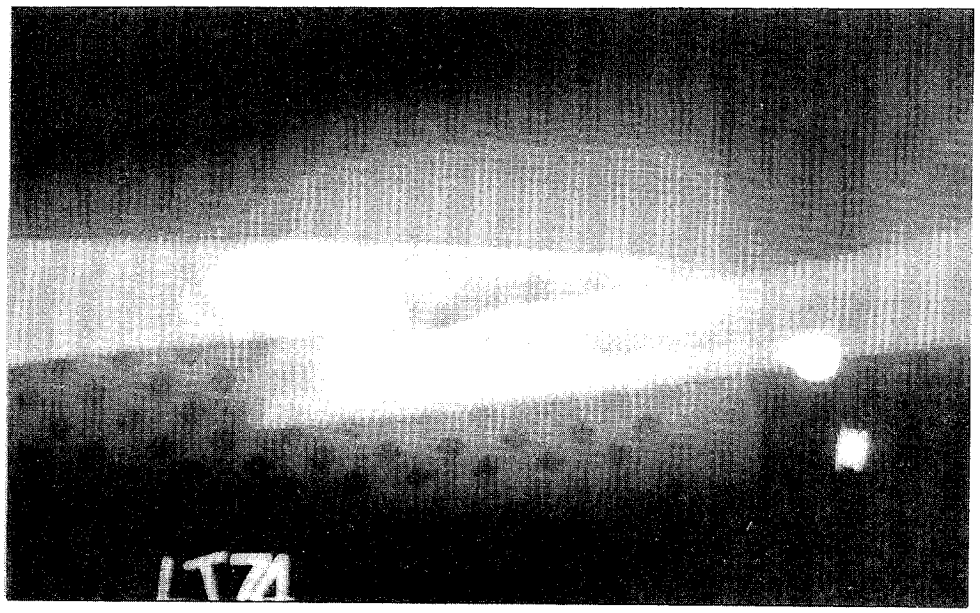

126C X-Ray revealing a transverse, midshaft fracture of the left femur.

Contact Point- Front interior including instrument panel and impact forces associated with the intrusion and front of Vehicle 2.
Type of Crash- Frontal impact

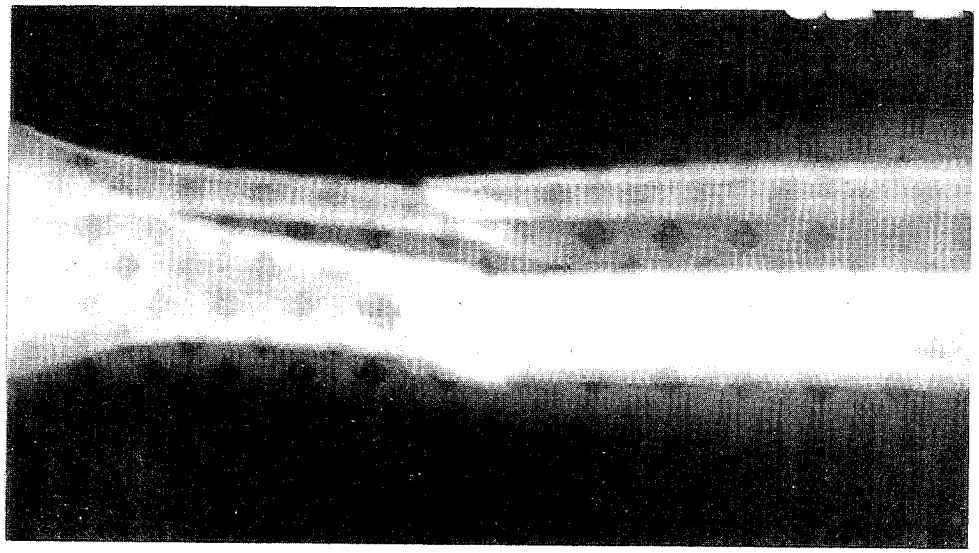

126D X-Ray revealing open fractures of the right distal tibia and fibula.

Contact Point- Front interior including instrument panel and impact forces associated with intrusion and front of Vehicle 2.
Type of Crash- Frontal impact.

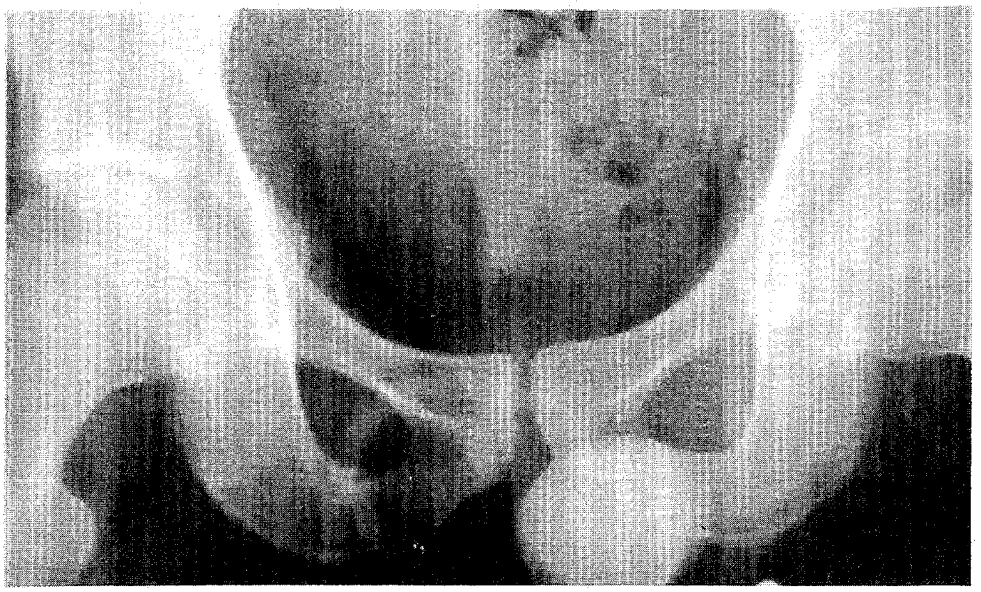

126A Pelvic X-Ray revealing a right pubic ramus fracture. Vertically aligned crack in pubic ramus is indicative of an anterior/posterior load applied to the pelvis.

Contact Point- Front interior including instrument panel and impact forces associated with intrusion and front of Vehicle 2.
Type of Crash- Frontal impact

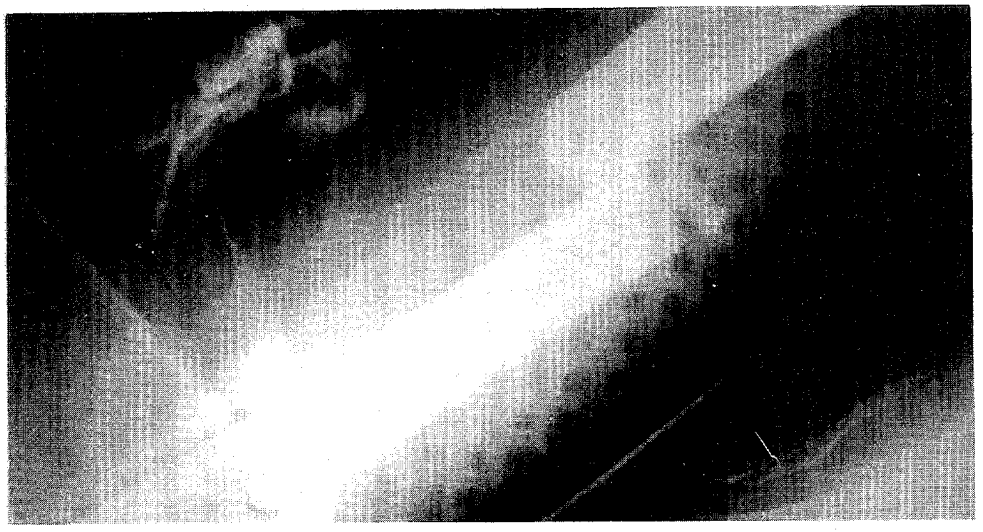

126B X-Ray revealing a transverse, midshaft fracture of the right femur. The fracture pattern is indicative of a direct, non-axial, non-torsional load applied to the femur. The overriding of bones occurs because of muscle contraction and not necessarily from initial load applied.

Contact Point- Front interior including instrument panel and impact forces associated with the intrusion and front of Vehicle 2.
Type of Crash- Frontal impact

SELECTED PHOTOGRAPHS, CASE 126

5.



Driver sustained right pelvic-hip fracture (AIS-3) when driver contacted center instrument panel; concussion and facial lacerations (AIS-2) when driver contacted windshield.

SELECTED PHOTOGRAPHS, CASE 126

3.



Right front seat occupant sustained closed head trauma (AIS-3) when he struck the windshield and interior; and other severe incapacitating injuries.

4.



V2 - 1979 Oldsmobile Cutlass 2 door coupe; Intrusion = 1.4" at right instrument panel. Max crush = 21.0" at front bumper. Delta-V = 20 - 24 m.p.h.

SELECTED PHOTOGRAPHS, CASE 126

1.

Scene photograph of impact area. Impact area is at the front of picture.

2.



V1; 1968 Volkswagen Bus. Frontal plane impact. Intrusion = 19.0" to entire front. Max Crush = 17.75" to left front bumper corner. Delta-V = 20 - 25 m.p.h.

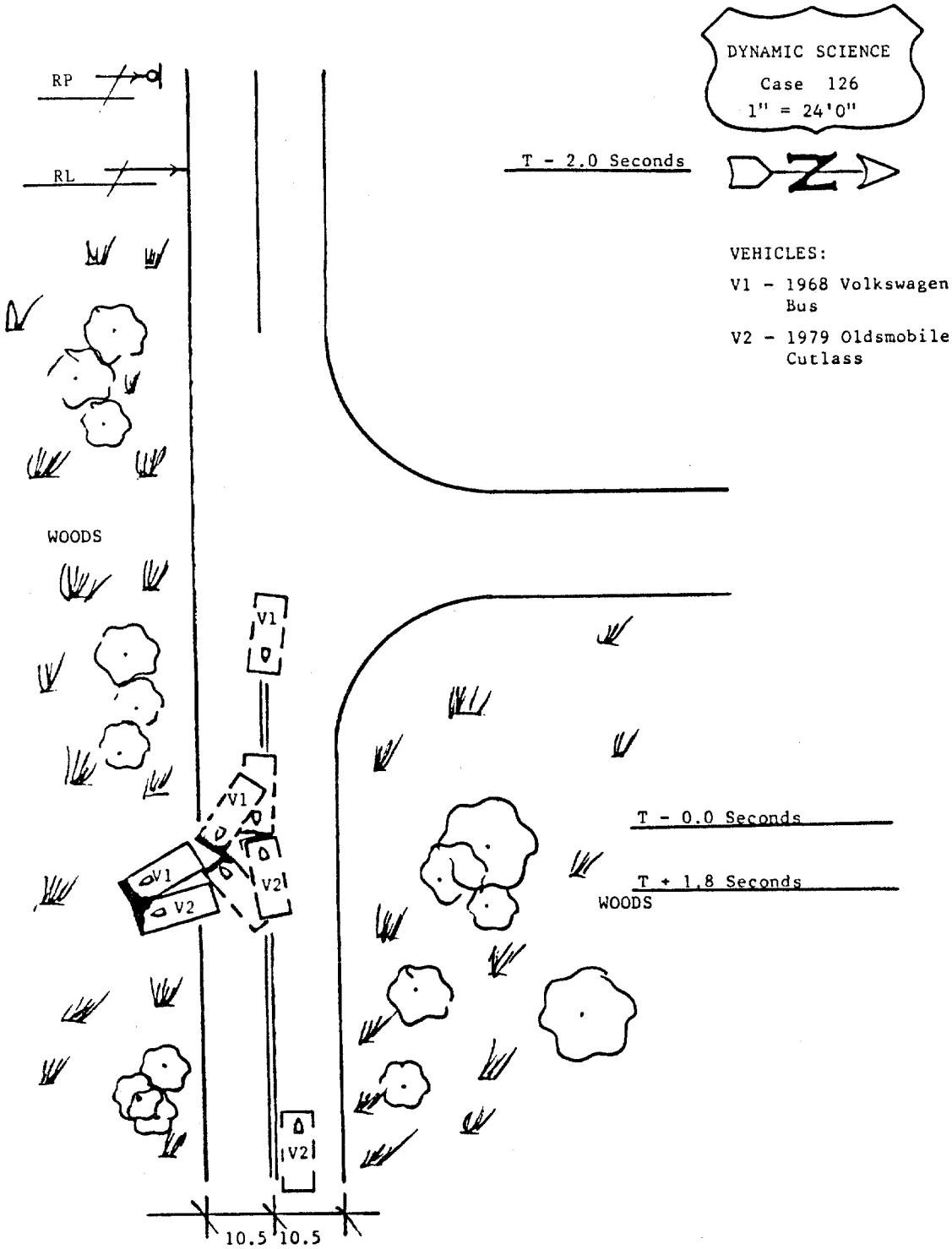
DYNAMIC SCIENCE
Case 126
1" = 24'0"
RP
RL
T - 2.0 Seconds
VEHICLES:
V1 - 1968 Volkswagen Bus
V2 - 1979 Oldsmobile Cutlass
WOODS
V1
V1
V1
V2
V2
V2
T - 0.0 Seconds
T + 1.8 Seconds
WOODS
10.5
10.5

to analyze impending dangerous situations and speed regulations, would greatly enhance the safety aspect of collision avoidance. The ability to overcome human error through the use of electronics will greatly reduce accidents such as this one. Neither driver nor occupants were wearing seat belts which were available but required the efforts of the users to use. Automatic belts and air cushion restraint systems would have reduced some of the injuries. The case occupant was severely injured as the rusted sheet metal split and allowed his legs to be partially severed. A nationwide "yearly" inspection could remove vehicles which are no longer safe to drive.

with the left hand/arm being the stronger. Due to non-vocal status, the formal evaluation was not given. The patient did appear oriented and was able to follow simple instructions. He was also NPO (unable to be administered anything orally) at that time. Recommendations included trial use of an electrolarynx to facilitate communication and the eventual change to a talking trach while on the respirator. A swallow evaluation and treatment was given when the patient was off of the respirator. Cognitive- communicative skills were to be fully assessed when the patient is able to speak.

The patient's tracheostomy was removed on T + 31 days. Cognitive-communicative skills were assessed on T + 32 days. As the patient continued to exhibit weakness of the right hand, the written expression battery could not be administered. All other assessment areas (auditory comprehension, written comprehension, oral expression, speech and cognition appeared within normal limits. Hearing and swallowing skills also appeared within normal limits. The patient was felt to be at the Ranch Los Amigos level VIII (Purposeful-Appropriate) response level. No further services or follow-up were indicated.

PSYCHOSOCIAL FOLLOW-UP - CASE 126

6 Months

This 20-year-old college student was discharged from Shock Trauma 48 days post-trauma to inpatient rehabilitation facility for ambulation and gait training following bi-lateral below-the-knee amputations. Patient remained in rehabilitation 7 weeks, returning home for further therapy and private tutoring.

At 6 months patient remained unemployed and not back at school due to end of semester but plans to return to school in 1 month.

1 Year

Patient returned to college studies 7 months post-trauma, ambulating independently, driving vehicle with hand controls and starting to run and train again for rugby. Patient has worked tremendously hard to regain his physical abilities. Emotionally, patient has pursued goals, plans to attend law school, and feels integrated back into community. Legal implications and lengthy process of same has been frustrating and discouraging.

CRASH AND INJURY PREVENTION IDEAS - CASE 126

This accident occurred because the driver of one vehicle crossed the center line and was struck by an oncoming vehicle whose driver elected to move into oncoming traffic as an evasive action. As in several of the cases, an electronic warning device would have warned the first driver of his position. The development of electronically "smart" highways, with the ability

administration of crystalloid. The patient required extrication from the vehicle.

T+ 58min: Patient departs scene for MIEMSS/Shock Trauma by ambulance.

T+ 85min: Patient arrives at MIEMSS. Initial physiologic assessment of the patient reveals a blood pressure of 130/80, a heart rate of 140, a respiratory rate of 30, and a Glascow Coma Score of 15. The patient's ISS (Injury Severity Score) = 34. Toxicology screen results were negative. Initial hospital care provided includes:

- -Evaluation by a MIEMSS trauma team,
- -Fluid resuscitation,
- -Diagnostic peritoneal lavage with positive results,
- -Full diagnostic evaluation including x-rays of the cervical spine, chest and pelvis. In addition to the toxicology screen, an arterial blood gas, a CBC (complete blood count), an SMA-6 (routine blood chemistry) and an UA (urinalysis) were performed.

Initial clinical findings included the following:

- -Closed head trauma,
- -Multiple facial and elbow lacerations,
- -Blunt abdominal trauma and splenic laceration,
- -Pelvic fracture,
- -Bilateral Closed femur fractures,
- -Right Grade III Open Tibia-Fibula fracture,
- -Right Grade III Open calcaneus fracture,
- -Left Grade III Open Talus fracture and disclocation with open calcaneus fracture,
- -Left closed tibia/fibula fracture.

Operative care includes:

- -Intermedullary rodding of the right femur during open reduction,
- -Splenectomy,
- -Insertion of Tibial Traction pins for right tibia/fibula fractures,
- -Right foot injury irrigation and dilation and placement of an external fixitor,
- -Completion of the left foot amputation,
- -Insertion of tibial traction pin- left tibia/fibula fracture reduction.

T+24hours - 47 days: Patient spends 31 days in critical care and 16 days in intermediate care. Complications include pulmonary failure, pneumonia and a late pneumothorax.

T+ 47 days: Patient discharged from MIEMSS to an out-of-state inpatient rehabilitation facility.

COGNITIVE-COMMUNICATIVE ASSESSMENT - CASE 126

The patient was initially evaluated on T + 20 days. At that time he had a tracheostomy and was respirator-dependent. The patient was exhibiting bilateral paresis of both arms and hands

cloudy with rain. Prior to impact, the driver of Vehicle 1 allowed his vehicle to drift across the center line. The driver of Vehicle 2 initiated evasive action by turning left into the oncoming path of Vehicle 1.

T = 0:00 Seconds: At impact, the front bumper of Vehicle 2 overrode the bumper of Vehicle 1 and began intrusion into the driver and occupant compartment of Vehicle 1. At impact, both Vehicles had crossed the center line and the contact was made approximately in the center of the roadway. The direct and induced damage width was measured at 52.5 inches at both bumper level and Vehicle 2's bumper signature just below Vehicle 1's headlights. The two sets of "C" measurements were averaged and produced a maximum crush of 17.75 inches at C1, the left front bumper corner of Vehicle 1. The configuration of a Volkswagen bus combined with rust contributed to the maximum intrusion of 19.1 inches at C1 and 12.0 inches at C6. The intrusion was across the entire frontal plane of Vehicle 1. The front vertical plane of the bus separated in a near straight line in the vicinity of the floor pan. The driver and right front seat occupant's lower extremities were exposed to sharp jagged edges of metal and the exterior of Vehicle 2 during intrusion and maximum engagement.

T + 0.025 - 0.05 Seconds (estimated): As the front bumper of Vehicle 2 intruded into the front of Vehicle 1 and the sheet metal split, the unbelted driver and occupant would have been forced against the instrument panel and interior front of Vehicle 1 contributing to the case occupant's closed head trauma with loss of consciousness, lacerated spleen, facial and elbow lacerations, and combined with impact forces, a right pubic ramus fracture and bilateral femur fractures. As the floorboard separated from the front of the vertical front of Vehicle 1, the case occupant's lower extremities were exposed to sharp metal edges, severe intrusion and the exterior of Vehicle 2. This combination probably resulted in Grade III (open) right tibia/fibula fractures, left tibia/fibula fractures, left and right fractures calcaneus with partial amputations of both feet.

T + 1.8 Seconds (estimated): Vehicle 1 rotated approximately 60 degrees clockwise while sliding 17.5 feet to final rest facing west-southwest. Vehicle 2 rotated approximately 100 degrees counterclockwise while sliding 13 feet to final rest.

T + 21:00 Minutes: The police agency was notified.

T + 35:00 Minutes: The police arrived at the accident scene and began investigative and medical relief efforts.

PREHOSPITAL AND HOSPITAL TIMELINE - CASE 126

T+ 4min: Ambulance receives call to respond.

T+ 14min: Ambulance arrives at scene. Initial field assessment reveals a blood pressure of 88/56, a heart rate of 100, a respiratory rate of 24, and a Glascow Coma Score of 13. Prehospital care includes fluid resuscitation with the

associated
with
intrusion &
front of V2

* - Coded as separate injuries
** - Coded as one injury

PSYCHOSOCIAL SUMMARY - CASE 126

The study patient, a 20-year-old male, was a right front seat passenger in a van which was had a frontal collision with another vehicle on a rural road. Both the patient and driver are students who were returning home from a part-time job at a tree farm. The study patient sustained multiple trauma of the chest and lower extremities and subsequent medical amputation of both feet.

The family describes the patient as a spiritual person, very sociable and outgoing, and with an easy disposition. He has been a full-time student, is in his second year of college, is on the dean's list, a scholarship winner and is pursuing a dual major in the areas of political science and business economics. The student is currently taking summer school courses and living at the home of his paternal grandmother in the city. The patient's family resides out-of-state in a rural area and is caring for the invalid paternal grandmother. The family is now also staying at the grandmother's home in order to be closer to the hospital. The maternal grandparents are also available to provide support.

The patient is the oldest of four children, having a 17-year-old brother and two sisters ages 13 and 19. The mother works sporadically as a receptionist. The patient's father is employed as a computer analyst with the government. The family's health insurance provider is a health maintenance organization.

At T + 20 days, the patient remains medically paralyzed and is on a respirator in the critical care area.

CRASH TIMELINE - CASE 126

T - 2.0 Seconds: Vehicle 1, a 1968 Volkswagen bus was westbound at a speed estimated at 33 - 41 miles per hour. The driver, a 20 year old male, was not wearing the available lap/shoulder belt. For the case occupant, a 20 year old male who was seated in the right front seating position, lap/shoulder belt usage is indeterminable. Vehicle 2, a 1979 Oldsmobile Cutlass was being driven eastbound at an estimated speed of 31 - 38 miles per hour by a 56 year old female. The driver of Vehicle 2 was not wearing the available lap/shoulder belt, and neither Vehicle 1 nor Vehicle 2 are equipped with air cushion restraint systems. The roadway at this location is a curved, 2-lane, asphalt paved road in a rural environment with a wet coefficient of friction estimated as .55. At the time of the accident, the weather was

				including windshield, instrument panel & hardware (Volkswagen bus)
2.2FULI2	151113	873.49	Facial lacerations (unspecified)	
3.2ELLI1	811313	881.01	Lacerations, elbow, left	Flying glass
4.2ERLI1	911313	881.01	Laceration, elbow, right	
5.2MLLQ3	161113	865.02	Blunt abdomen trauma, lacerated spleen	Front interior including instrument panel & hardware
6.2PADJ2	161213	808.2	Right pubic ramus fracture	Front interior including instrument panel & impact forces associated with intrusion & front of V2
7.2LRFS2	161213	821.01	*Bilateral femur fractures	
8.2LLFS2	161213	821.01	*Bilateral femur fractures	
9.2LRFS2	161213	823.32	*Grade III (open) right tibia fracture	
10.2LRFS2	161213	823.32	*Grade III (open) right fibula fracture	
11.2QRMS3	561113	896.2	Fracture, Calcaneus w/ partial amputation > 2/3 of foot	Floor pan & front interior (floor pan split open from intrusion & rust)
12.2QLZJ3	561113	825.31 838.11	**Fractured & **Dislocated talus	
13.2QLMW3	561113	896.2	Fracture, Calcaneus, partial amputation > 1/2 of foot	
14.2LLFS2	161213	823.22	*Fractured left tibia	Front interior including instrument panel & impact forces
2LRFS2	161213	823.22	*Fractured left fibula	

SUMMARY - CASE 126 (027)

This two vehicle accident occurred in mid-summer during the afternoon hours. The roadway was wet as a result of rain at the time of the accident and has an estimated wet coefficient of friction of .55. The roadway is 21.0 feet wide and has 1 eastbound and 1 westbound lane separated by double solid yellow lines. Vehicle 1 is a 1968 Volkswagen bus being driven eastbound at an estimated speed of 33 - 41 miles per hour by a 20 year old male. The driver was not wearing the available lap/shoulder belt. Restraint usage for the case, who was seated in the right front seating position, was indeterminable. The vehicle is not equipped with an air cushion restraint system. Vehicle 2 is a 1979 Oldsmobile Cutlass 2-door coupe, being driven westbound at an estimated speed of 31 - 38 miles per hour by a 56 year old female. The driver of Vehicle 2 was not wearing the available lap/shoulder belts and the vehicle is not equipped with an air cushion restraint system. At impact, the frontal plane of Vehicle 2 struck the frontal plane of Vehicle 1, overriding the bumper and severely intruding into the driver/passenger compartment. This intrusion was measured at 19.0 inches at C1 and 12.0 inches at C6. The delta-V's were computed as 23 miles per hour for Vehicle 1 and 22 miles per hour for Vehicle 2 using the damage only routine of Crash PC. The sheet metal just above the bumper of Vehicle 1 split as a result of impact forces and rusting. The configuration of a Volkswagen bus would have contributed to the severe injuries sustained by the driver and occupant in this frontal impact accident. The case, seated in the right front seat, sustained severe injuries consisting of a closed head injury with unspecified loss of consciousness, a right pubic ramus fracture, a suspected sacrum fracture, bilateral femur fractures, right and left tibial/fibial fractures which were attributed to occupant contact with the front inside of the bus, impact forces associated with the intrusion and possible contact with the exteior front surface of Vehicle 2. The combination of impact forces causing the front sheet metal to split, exposing sharp edges of metal at the forward edge of the floor pan combined with the intrusion and frontal surface of Vehicle 2, contributed to right and left calcaneus fractures, a left talus fracture and dislocation and partial amputation of the right and left feet. More specific contact points were unattainable due to the rain-washed interior of the Vehicle. Both the driver and case occupant were treated at the scene, transported by ambulance to a major trauma hospital for admittance and further treatment. The front of Vehicle 1 was removed for occupant extrication.

BODY CONTACTS AND INJURIES TABLE-CASE 126

20 year old male; passenger; 1968 Volkswagen Bus; frontal impact

OIC/AIS CODE		ICD-9	BODY CONTACTS AND INJURIES	CONTACT POINT
1.2HWKB3	161113	854.06	Closed head trauma with unspecified LOC	Front interior

160C Operative photo revealing a laceration to the left lateral lobe of the liver. Sutures note repair of laceration.

Contact Point- Shoulder belt
Type of Crash- Rear impact

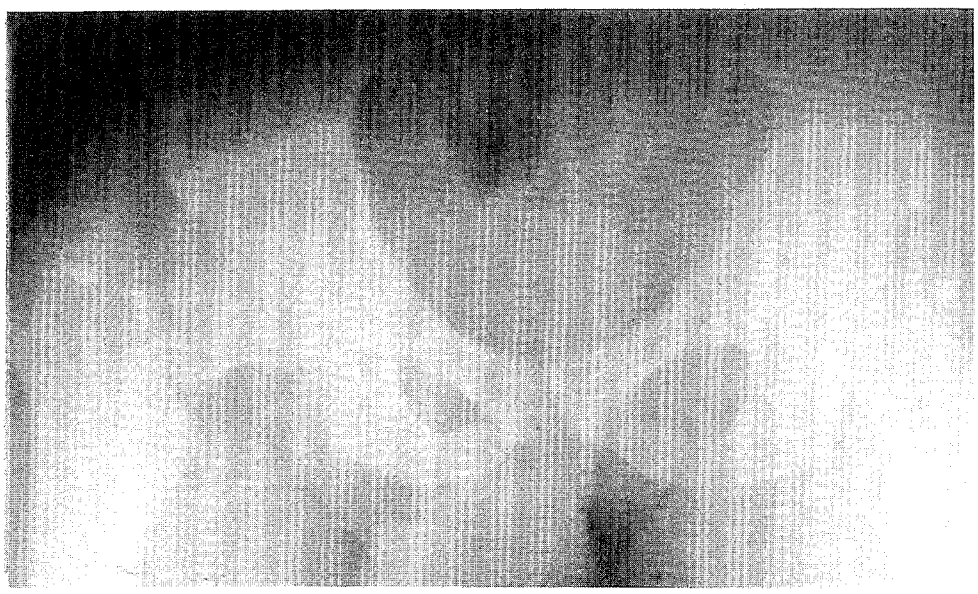

160D Pelvic X-Ray revealing a fracture of the right femoral neck. The fracture pattern is indicative of an axial load applied to the femur.

Contact Point- Instrument Panel, Center
Type of Crash- Rear impact

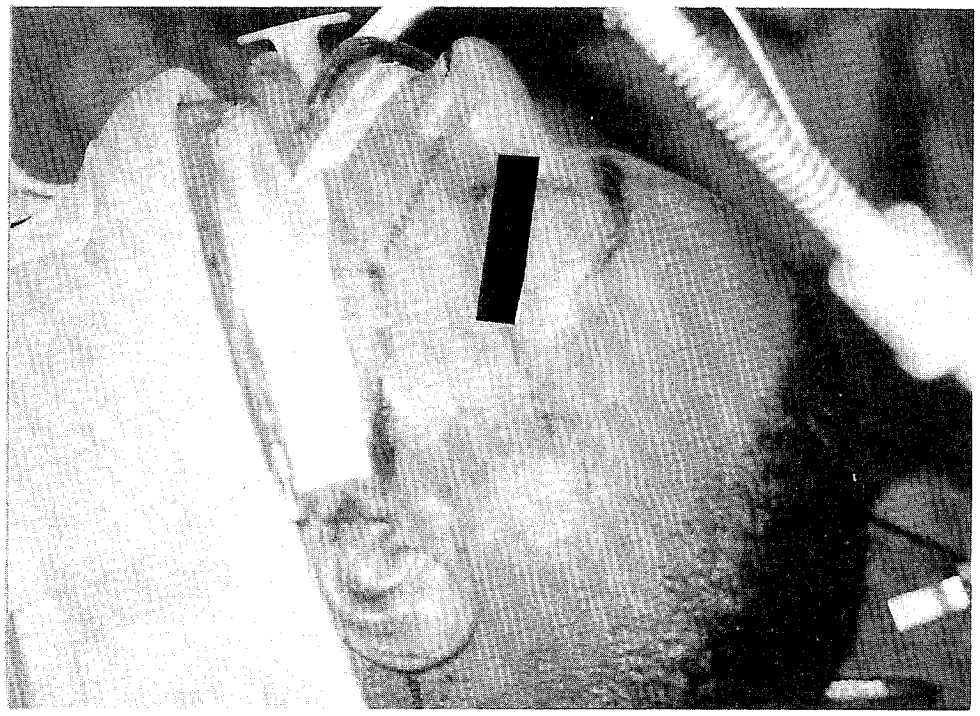

160A Multiple right sided facial lacerations. The patient has been endotracheally intubated and is being ventilated by a respirator. A rigid oropharyngeal airway is in place and the patient is cervically immobilized with a Philadelphia collar.

Contact Point- Steering Rim??
Type of Crash- Rear impact

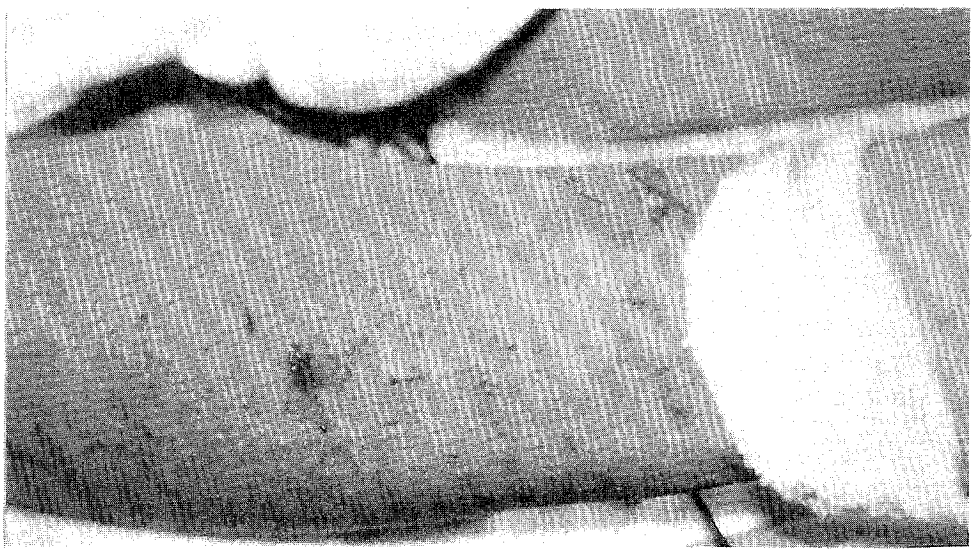

160B Abrasions to the right forearm.

Contact Point- Steering Rim/Hub
Type of Crash- Rear impact

SELECTED PHOTOGRAPHS, CASE 160

5.



V1 steering assembly and instrument panel. Yellow tape marks driver contacts. High AIS = 3. Windshield removed for rescue.

6.

V2 (1989 Dodge Grand Caravan SE). Frontal impact. Max Crush = 16.4 inches. Delta V = 27 to 31 m.p.h. Minor toepan intrusion

SELECTED PHOTOGRAPHS, CASE 160

3.



V1 side view. Latch/Hinge failure both left doors. Rear seatback intrusion = 27.7 inches. Front seatback intrusion = 13 inches.

4.

V1 Driver's Head Restraint; Head contact. An unoccupied child seat was wedged between left rear and driver's seat positions.

SELECTED PHOTOGRAPHS, CASE 160

1.

Scene photograph showing approach direction of V1, a pile of collision debris (right), and a faint spill (left); V1 at FRP

2.

V1; (1988 Ford Tempo 4 door sedan). Rear impact. Max Crush = 49.8 inches at left rear bumper corner. Delta V = 36 to 40 m.p.h.

COLLISION SCHEMATIC
CASE 160

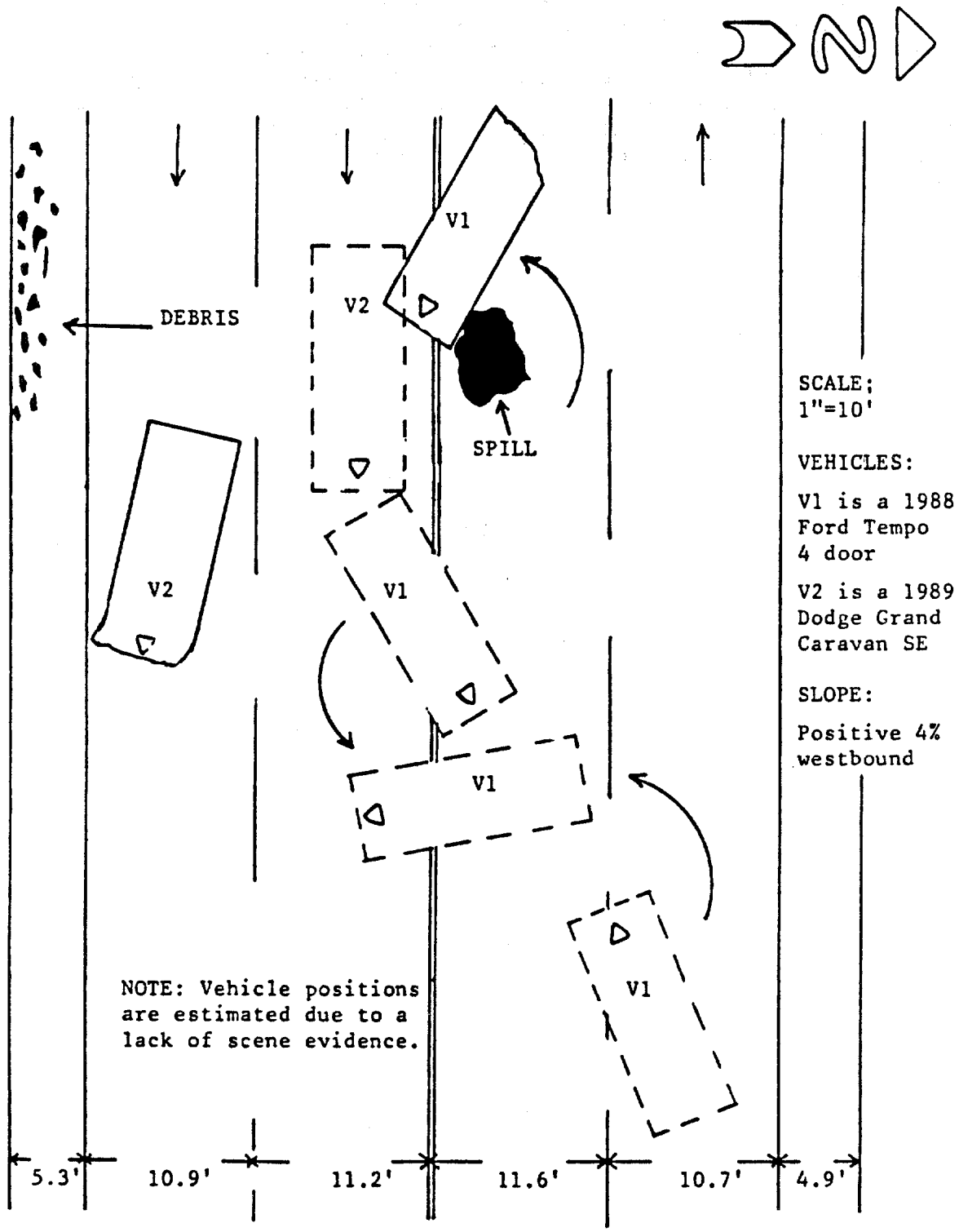

the manual lap belt system in his vehicle. The entire incident may have been prevented if there was in place some system whereby people involved in motor vehicle accidents undergo a program to diminish their risk of future incident. His injuries, specifically the femoral neck fracture would have been prevented if there was a system whereby the lap component of the safety harness was made automatic. Wearing this would have prevented him from going as forward as he did and impacting the dashboard with resultant axial load across his femur to the femoral neck.

The pre-hospital and hospital response to this accident would seem to have taken place in appropriate time period. There were no pre-hospital or hospital complications that could have been prevented.

PREVENTION AND INJURY REDUCTION - CASE 160

This crash was the result of several minor problems that occurred simultaneously; (1) it was raining while (2) our case was attempting to eat and drive while (3) our case vehicle encountered an imperfection in the roadway that caused the vehicle's suspension to "stretch out" while (4) our case was probably attempting to change lanes while (5) the vehicle was traveling too fast for the conditions. How many times in our day to day driving are we one minor simultaneous problem short of a crash? Probably more often than we realize.

Compare the extent of damage between the 2 vehicles. The case vehicle (Ford Tempo) had 49.8 inches of crush to the rear while the Dodge van had 16.4 inches of crush to the front. With front drive vehicles, most of the stiffness is in front and there is barely more than sheet metal in the rear. Given the angle of this impact, had the Tempo been stiffer in the rear, it might have been subjected to more rotational forces and less of the blunt accordian style damage that occurred. Had the Tempo sustained less crush/more rotation, our case would have been located near the vehicle's pivot point and he may have suffered less injury. As it happened, the Tempo's crush characteristics provided a "grip" for the front of the Dodge. The child seat that was located in the Tempo's left rear seat position was not inspected. It was unoccupied during the crash. It would have been interesting to see how well it held up having caused so much damage to the driver's seatback. It was nowhere to be found. The driver was wearing a 2 point automatic shoulder belt, but was not using the available manual lap belt. A 2 point automatic shoulder belt by itself is not enough protection. There are factory installed 3 point automatic systems in use today.

One observation about the Dodge Caravan. There was a hand grip on the rear of the right front seatback. The 5 year old center rear seat passenger used this hand grip to brace herself, and while it appears that she may have sustained an injury to that hand, she may have sustained serious lap belt related abdominal injuries had her forward motion not been buffered. Hand grips. Good idea.

---- Jerry Jackson

PREVENTION COMMENTS - CASE 160

The patient is a 24 year old black male who lost control of his vehicle while exceeding the speed limit on a rain soaked asphalt highway. He had been involved in an accident 61 days prior to this incident at which time he sustained minor neck trauma. During the current incident he was reportedly eating a watermelon at the time that the event occurred. He was also noted to be wearing the automatic shoulder belt but not wearing

Significance of the Crash:

This was a rather severe case. It involves a 24 year old male driver. The accident occurred on an arterial highway at a speed of 60-70 with an estimated Delta V of 36-40. There was an intrusion of 25.4 inches.

About 21% of collisions with a vehicle in transport are AIS >= 1 but 43% are AIS >= 1. This is also the most frequently occurring type of accident. Where the speed limit is 55 mph in rural areas there is a 30% chance of an AIS <= 1. While there are no statistics on rear to head collisions where the vehicles are going in the opposite direction, this accident can be roughly viewed as a head-on collision.

When the intrusion is greater than 12 inches, there will be an AIS >= 1 85% of the time with an AIS >= 3 25% of the time. Additionally, this driver's age group is the second most likely to be in an injury producing accident (19%).

This driver is lucky to be alive. 61% of all accidents on arterials are passenger cars and 70% of those on rural arterials with a posted speed limit are fatal. Considering the speed and conditions of the accident, this could very well have been a fatality producer. He is probably lucky that he was going backwards when hit and did not have the frontal impact into the steering wheel and windshield. The fact that the first thing he hit was the headrest and seat back probably was a saving factor. He hit the steering wheel (or was pushed into it by the baby seat in the back) as a secondary happening.

PSYCHOSOCIAL FOLLOW-UP - CASE 160

6 Months

Twenty-four (24)-year-old black male discharged from Shock Trauma following 14 days acute care to home, with outpatient physical therapy and occupational therapy for two months 3 times a week. At 6 months patient ambulating independently with a slight limp and experiencing some pain in hip area. Patient not working at present, but plans to return to former job as a security guard next month. Patient not driving. Memory problems and outbursts evidenced.

1 Year

Patient returned to full-time work as a security guard at 7 months post-trauma. He also began driving at this time. Patient married his girlfriend of 3 years and living with her and their 3-year-old daughter. Patient experiences some lapses in memory and exhibits increased episodes of irritability.

blood count), an SMA-6 (routine blood chemistry) and UA (urinalysis) were performed.

Initial clinical findings included the following:

-Closed head trauma,
-Multiple facial abrasions,
-Multiple right arm abrasions,
-Blunt abdominal trauma,
-Small left lobe liver laceration,
-Serosal muscular injury of the ascending colon,
-Right femoral neck fracture

Operative care included:

-Open reduction of the femoral neck fracture with internal fixation (compression plate and screw)
-Repair of the liver injury,
-Repair of the colon injury.

T+24hours - 15days: Patient spends 6 days in intensive care and 9 days in intermediate care. Patient did not suffer any complications during acute care period.

T+ 15days: Patient discharged from MIEMSS to home unable to ambulate.

COGNITIVE-COMMUNICATIVE ASSESSMENT - CASE 160

The patient's cognitive- communicative skills were initially evaluated on T + 5 days. The patient was alert and responsive, however was confused as to place and time of the evaluation. Results of the evaluation indicated that the patient had moderate deficits in the areas of auditory comprehension, written expression, written comprehension, and cognition. The patient was diagnosed as an RLAS (Ranch Los Amigos Score) VI- confused and appropriate response. Treatment for deficits was recommended. The patient failed the hearing screening and his swallowing skills were within normal limits. The patient was on a P.O. diet.

The patient received treatment for the diagnosed deficits. Rapid improvement was noted and a discharge evaluation was given on T + 12 days. Improvement was noted across all areas evaluated. Mild deficits continued for high-level auditory comprehension and cognitive processing activities. The patient was diagnosed as an RLAS VII-emerging VIII and was discharged to home with recommendation for continued outpatient therapy and a re-evaluation in 3 months. The patient was diagnosed with a mild hearing loss and continued to be on a P.O. diet.

CRASH COMPARISON - CASE 160

The cases used for comparison are covered in our simulation write up. The simulation engineer retrieved and analyzed the crash curves.

across the front of V2 and the maximum measurement was taken about 12 inches to the right of the left front bumper corner. V2's estimated speed change at impact was between 27 and 31 miles per hour. The driver and right front passenger were both using the available manual lap and shoulder belts, and they were both forced forward at impact. There was evidence of foot loading to the brake pedal and the driver's knees contacted the left instrument panel. The left side of the steering rim was deformed and the driver's left hand apparently slipped off of the steering rim and contacted the windshield. The right front passenger's legs contacted the right instrument panel as evidenced by broken plastic. The center rear seat passenger was also forced forward at impact. She was restrained by the available manual lap belt and was also clutching a hand grip that was mounted to the back of the right front seatback. The only intrusions noted to V2 were the right and left toepan areas which were intruded longitudinally 2.1 and 1.9 inches respectively.

T + .56 seconds: V2 rotated slightly clockwise after impact and came to rest still facing east an estimated 16 feet to the southeast of the impact point. All 3 occupants were eventually transported to hospitals for treatment and V2 was towed from the scene with disabling damage.

T + 1.53 seconds: V1 continued counterclockwise rotation throughout the collision sequence and came to rest facing southeast approximately 24 feet to the northwest of the impact point. The driver (our case) was eventually transported to a hospital for treatment and V1 was towed from the scene with disabling damage.

T + 1 minute: Police were notified of the collision.

T + 2 minutes: Police arrived at the scene.

PREHOSPITAL AND HOSPITAL TIMELINE - CASE 160

T+ min: Ambulance receives call to respond.

T+ min: Ambulance arrives at scene. No vital signs were recorded at the scene. The patient required extrication from the vehicle.

T+min: Patient departs scene for MIEMSS/Shock Trauma by police medevac helicopter.

T+ 64min: Patient arrives at MIEMSS. Initial physiologic assessment of the patient reveals a blood pressure of 142/83, a heart rate of 102, a respiratory rate of 22, and a Glascow Coma Score of 14. The patient's ISS (Injury Severity Score) = 22. Toxicology screen results were negative. Initial hospital care provided includes:

-Evaluation by a MIEMSS trauma team,
-Fluid resuscitation,
-Diagnostic peritoneal lavage with positive results,
-Full diagnostic evaluation including x-rays of the cervical spine, chest and pelvis. In addition to the toxicology screen, an arterial blood gas, a CBC (complete

and then came spinning across his path from right to left. The witness also stated that V1 appeared to have had an abnormally high profile (due to "stretched out" suspension). V1 rotated clockwise approximately 220 degrees as it crossed into the inside eastbound lane. Just prior to impact, V1 was headed approximately 40 degrees to the north of due east and was traveling southwest at an estimated speed of between 57 and 63 miles per hour. V2 was traveling due east in the inside eastbound lane at an estimated speed of between 43 and 47 miles per hour.

T - 0: The back of V1 impacted the front of V2 in the inside eastbound lane. Maximum longitudinal crush to the rear of V1 was measured to be 49.8 inches at the left rear bumper corner. V1's estimated speed change at impact was between 36 and 40 miles per hour. At impact, the left "C" pillar intruded longitudinally 25.4 inches, the left "B" pillar intruded forward 7.5 inches, and both left side doors sustained latch and hinge failure due to the "accordian" type damage. The driver of V1 (our case) was forced rearward into the driver's seatback. There was substantial damage to the driver's headrest and our case sustained associated closed head trauma. As the rear of V1 was crushed forward, the left, center, and right rear seatbacks intruded forward 27.7, 18.7, and 7.5 inches respectively. There was an unoccupied child seat in the left rear seat which was forced forward into the driver's seatback. This intrusion related seat impact along with rebound action caused the driver's seatback to intrude forward 13 inches and also caused our case to be forced violently forward. Our case was using the available automatic 2 point shoulder belt but was not using the available manual lap belt. Both of our case's knees impacted the instrument panel. His right knee impacted and dislodged the factory installed radio at the lower center instrument panel. Our case sustained an associated right femur fracture. He probably had both hands on the wheel at impact. The steering rim was deformed, abraded, and broken, and there were tissue deposits, broken plastic, and a bent signal handle noted at the left central instrument panel behind (forward of) the steering rim. Our case sustained associated right arm abrasions and it is possible since he was using a shoulder belt that his head snapped forward in reach of the steering rim which would explain the source of his facial abrasions. Upon inspection, the webbing of the driver's automatic 2 point shoulder belt was noted to have substantial stretching. Our case sustained a small left lobe liver laceration and a serosal muscular injury of the ascending colon which can be attributed to shoulder belt loading. The driver had a mouth full of watermelon at impact. Watermelon was noted on the roof, instrument panel, doors, and also on the windshield which had been altered by rescue personnel. The windshield showed no signs of occupant contact or integrity loss as a result of the collision. The steering column and upper left instrument panel were also altered by rescue personnel as they apparently pulled the column up with a chain.

At impact, V2 sustained maximum longitudinal crush of 16.4 inches to the front bumper. The damage was evenly distributed

is the entire extended family. Many members of the family have been employed as either police officers or security police. The patient is reported to be a conscientious seat belt wearer and health conscious, exercising regularly, watching diet and demonstrating good safety awareness. The patient loves all types of music and plays a variety of instruments. According to his family, his most significant risk-taking experiences are riding motorcycles and, to date, he has never been involved in a cycle accident.

Due to some inital confusion and questionable mental status, rehabilitation is considered, although the patient is improving and is oriented and becoming more appropriate. The patient may be discharged to home with occupational therapy and physical therapy prescibed.

CRASH TIMELINE - CASE 160

T - 2 seconds: This was a 2 vehicle collision which occurred on a rainy weekday afternoon. The collision involved a 1988 Ford Tempo 4 door sedan (V1) with one 24 year old male occupant (our case), and a 1989 Dodge Grand Caravan SE (V2) with a 54 year old female driver, a 59 year old female right front passenger, and a 5 year old female center rear seat passenger. The roadway is a major asphalt arterial street which has 2 eastbound lanes that are separated from 2 westbound lanes by a continuous double yellow paint stripe. Each of the 4 travel lanes are approximately 11 feet in width and the roadway is bordered on the north and south by paved asphalt shoulders which are each approximately 5 feet wide. The roadway is situated in a rural area near the intersection of an interstate highway. The estimated wet roadway coefficient of friction is .6, and the posted speed limit is 45 miles per hour. In the area of the collision, the westbound lanes have a positive 4 percent vertical alignment and the eastbound lanes have a negative 4 percent vertical alignment.

V1 was westbound in the outside westbound lane at an estimated speed of between 60 and 70 miles per hour. V2 was eastbound in the inside eastbound lane at an estimated speed of between 43 and 47 miles per hour. The driver of V1 was trying to eat while driving and was probably not devoting full attention to the roadway. V1 arrived at the bottom of a dip between 2 hills and then began traveling up the 4 percent positive westbound slope. Just to the west of the bottom of this dip there is a gradual irregular bump in the roadway as the westbound lanes begin the 4 percent incline. It appears that at V1's travel speed, this irregular bump caused V1's suspension to "stretch out" which reduced the coefficient of friction between V1's tires and the wet roadway. If this condition existed at the same instant that the driver of V1 was attempting to change lanes to the left, it is reasonable to assume that counterclockwise rotation could result. A witness whose vehicle was westbound in the inside westbound lane stated that V1 passed him on the right

			Consciousness	
2.	2FUAI1 043100	910.0	Facial Abrasions	Steering Rim??
3.	2ARAI1 061100	913.0	Right Arm Abrasions	Steering Rim/Hub
4.	2MRLL2 411100	864.02	Laceration, Left Lobe Liver, Small	Shoulder Belt
5.	2MIUD2 411100	863.41	Serosal Muscular Injury Right Ascending Colon	Shoulder Belt
6.	2TRFS3 101100	820.8	Fracture, Right Femoral Neck	Instrument Panel, Center
	UNKNOWN IF INJURED		Broken plastic, Tissue deposits, Bent signal control handle (hand)	Instrument Panel, Central Left side
	UNKNOWN IF INJURED		Abraded plastic, (left knee)	Instrument Panel, Lower Left side

PSYCHOSOCIAL SUMMARY - CASE 160

The study patient, a 24-year-old male, was admitted to MIEMSS Shock Trauma after being involved in a two-car collision. The study patient was the driver and sole occupant of a rental car which collided with a car which had three passengers, each of whom were hospitalized. The patient was en route to work when the collision occurred and is reported to have been eating watermelon while driving.

The patient is the youngest of two brothers and has one sister. The patient lives with his girlfriend of three years and their two-and-a-half year old daughter. The patient's parents are divorced, although both the father and stepfather play an active role in the patient's life. The stepfather, who is a city police detective, has essentially raised the patient. The patient was returning to work for the first day following a motor vehicle accident at T - 61 days. In the previous collision, the patient sustained minor neck trauma and had been under the care of a chiropractor. The patient had been on leave from the food store where he was employed as a security officer. The patient was unsure of his work status at present. Also a security officer, the patient's girlfriend had started accounting school the day of the accident and has since dropped out to be at the hospital and to care for the patient upon his return home.

The mother describes the patient as a responsible young man who completed vocational training in diesel mechanics at T - 1 month. She reports that he tends to cope with problems well, has a happy outlook on life and is generally a spiritual person. The family states that he is a non-smoker and never uses alcohol or drugs. The girlfiend is extremely supportive and caring, as

SUMMARY - CASE 160 (026)

This 2 vehicle collision occurred on a rainy, summer, weekday afternoon. The collision involved a 1988 Ford Tempo 4 door sedan with one 24 year old male occupant (our case), and a 1989 Dodge Grand Caravan SE with a 54 year old female driver, a 59 year old female right front seat passenger, and a 5 year old female center rear seat passenger. The roadway is a major arterial street which has 2 eastbound lanes that are separated from 2 westbound lanes by a continuous double yellow paint stripe. The estimated wet roadway coefficient of friction was .6, and the posted speed limit was 45 miles per hour. The Ford (our case vehicle) was westbound in the outside westbound lane and was traveling up a 4 percent incline at an estimated speed of between 60 and 70 miles per hour. The Dodge was eastbound in the inside eastbound lane and was traveling down a 4 percent decline at an estimated speed of between 43 and 47 miles per hour. The driver of the Ford was trying to eat while driving and he lost control of the vehicle. The Ford began counterclockwise rotation, crossed the roadway to the left, and entered the inside eastbound lane. The front of the Dodge impacted the back of the Ford in the inside eastbound lane. At impact, the Dodge was headed due east and was traveling due east. The Ford was headed approximately 40 degrees to the north of due east and was traveling southwest. Estimated speed change at impact was between 36 and 40 miles per hour for the Ford, and between 27 and 31 miles per hour for the Dodge. The Ford continued rotating counterclockwise after impact and slid approximately 24 feet to its final rest position while the Dodge rotated slightly clockwise and came to rest approximately 16 feet from the point of impact. The Ford sustained a maximum longitudinal crush of 49.8 inches to the left rear bumper corner. The Dodge sustained a maximum longitudinal crush of 16.4 inches to the left side of the front bumper. Both vehicles were towed from the scene with disabling damage. The driver and right front seat passenger in the Dodge were both using the available manual lap and shoulder belts and the rear seat passenger was using the available manual lap belt as well as the hand grip that was mounted to the back of the right front seat. All three of the Dodge's occupants were transported to hospitals for treatment. The driver of the Ford was using the available automatic 2 point shoulder belt, but he was not using the available manual lap belt. The Ford was not equipped with an optional air cushion restraint system. The Ford's driver sustained 2 AIS-1 abrasions, an AIS-3 femur fracture, and 2 AIS-2 seatbelt related abdominal injuries. A complete list of injuries for this case is included below in OIC format:

BODY CONTACTS AND INJURIES TABLE-CASE 160
24 year old male; Driver; 1988 Ford Tempo 4 door; Rear impact

OIC/AIS CODE	ICD-9	CONTACTS & INJURIES	CONTACT POINT
1. 2HWKB2 441104	854.06	Closed Head Injury with Positive Loss of	Head Restraint

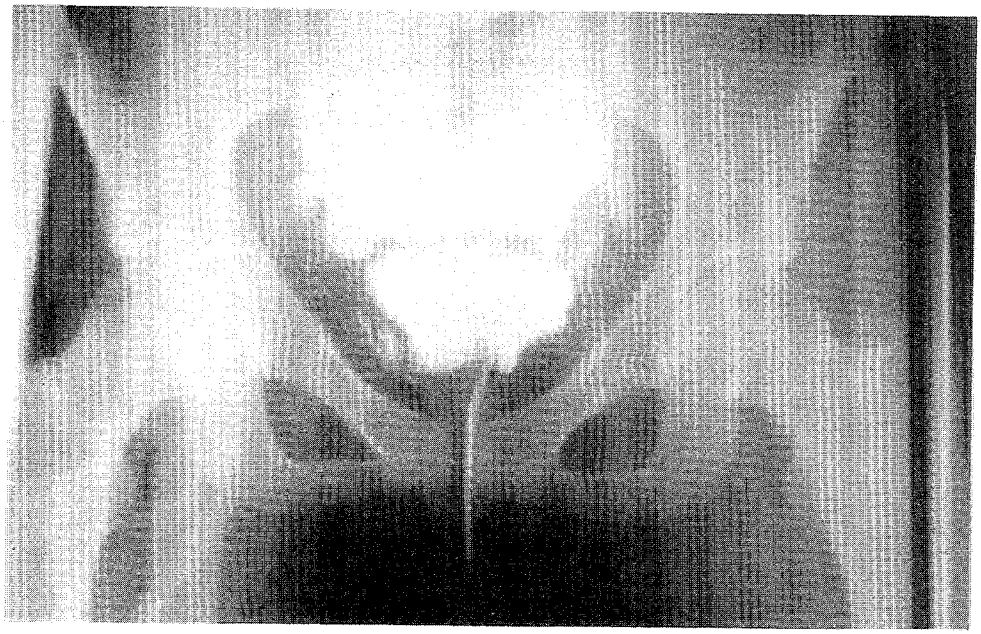

466C X-Ray revealing a right superior ramus fracture and a rupture of the urinary bladder with contrast media spillimg into the free peritoneal space. Such a rupture occurs when the blunt force is applied to a bladder that is distended with urine at the time of impact.

Contact Point- Interoccupant contacts, Right door panel/arm rest/window frame and glass/ B pillar/roof siderail and front bumper of V2.
Type of Crash- Right lateral impact.
Estimated Force of Lower Torso Impact with door- 440 lbs.

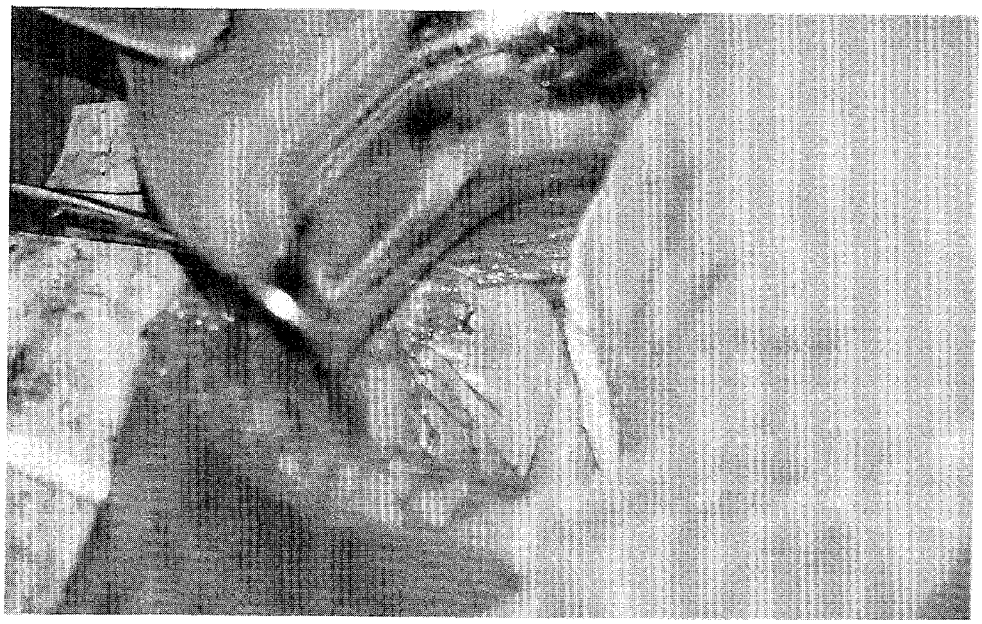

466D Photo showing repair of a ruptured urinary bladder.

Contact Point- Right door panel/arm rest/window frame and glass/B pillar/roof siderail and front bumper of V2.
Type of Crash- Right lateral impact
Estimated Force of Lower torso impact with door- 440 lbs.

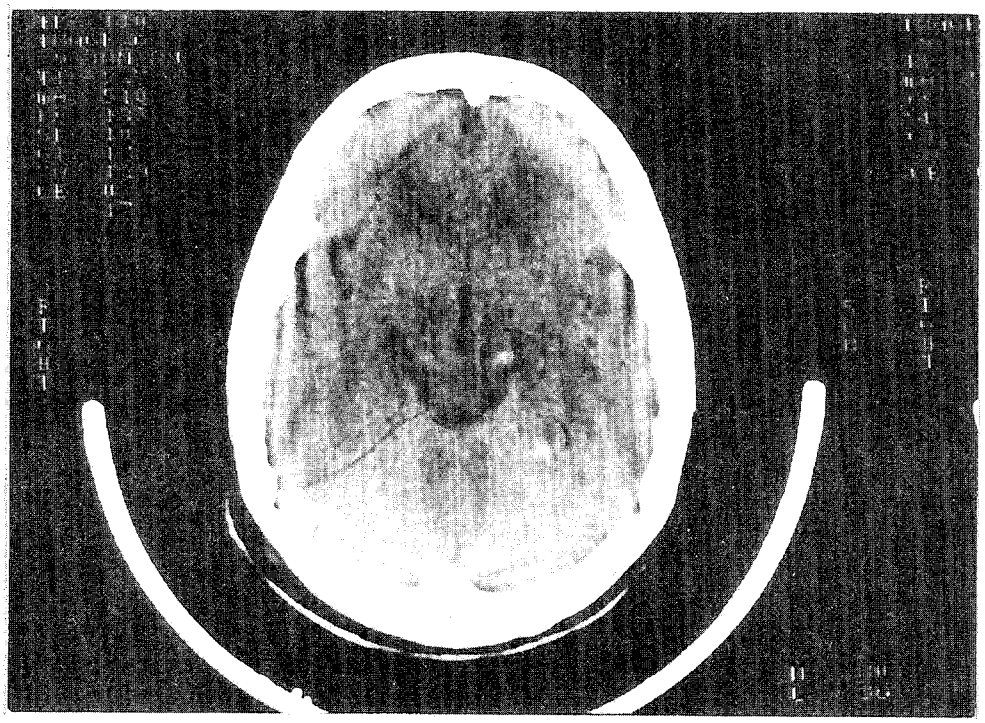

466A Head CT Scan revealing brain stem contusion.

Contact Point- Right door panel/arm rest/window frame and glass/B pillar/roof siderail and front bumper of V2.
Type of Crash- Right lateral impact
Estimated Force of Impact with Rear Window- 1300 lbs.

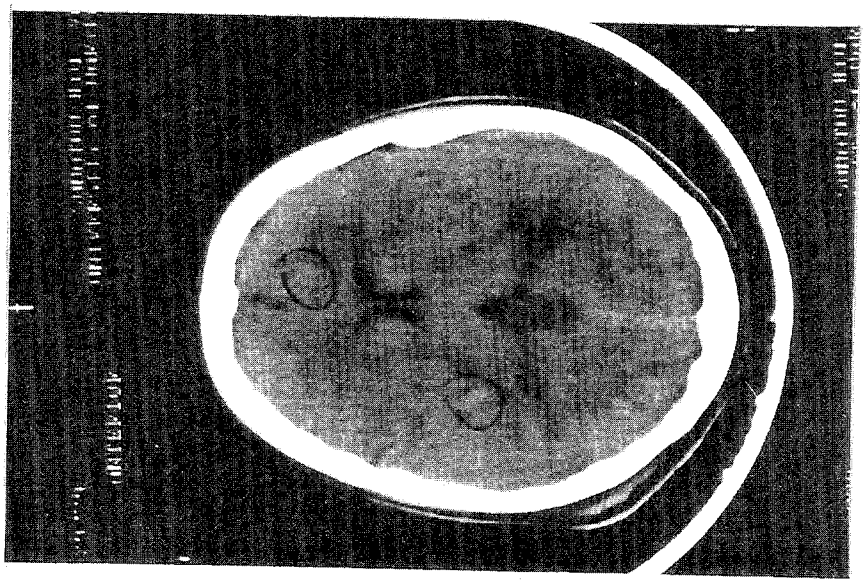

466B Head CT Scan revealing multiple cerebral contusions.

Contact Point- Right door panel/arm rest/window frame and glass/B pillar/roof siderail and front bumper of V2.
Type of Crash- Right lateral impact
Estimated Force of Impact with Rear Window- 1300 lbs.

SELECTED PHOTOGRAPHS, CASE 466

5.



V2 (1975 Fleetstar tanker truck) Maximum Crush = 2.0 inches.

6.



Scene. V1 direction of travel prior to making left turn into intersection to POI approximately 20′ west of vehicle on left.

SELECTED PHOTOGRAPHS, CASE 466

3.



a cerebral contusion & brain stem contusion (AIS-5), ruptured bladder (AIS-4) and other injuries in case occupant. Note: complete right side and rear and front seat deformations.

4.

V1 - Line strung between front and rear shows normal horizontal plane of Vehicle compared to damage sustained. Roof was removed to aid occupant extrication.

SELECTED PHOTOGRAPHS, CASE 466

1.



V1 (1986 Ford Escort). Side impact. Max Crush = 24.5 inches at "A" pillar. Intrusion into occupant area = 10 inches.

2.



Yellow tapes mark occupant contact points (r/s panel, arm rest, window frame & glass, front seat back and "B" pillar) causing

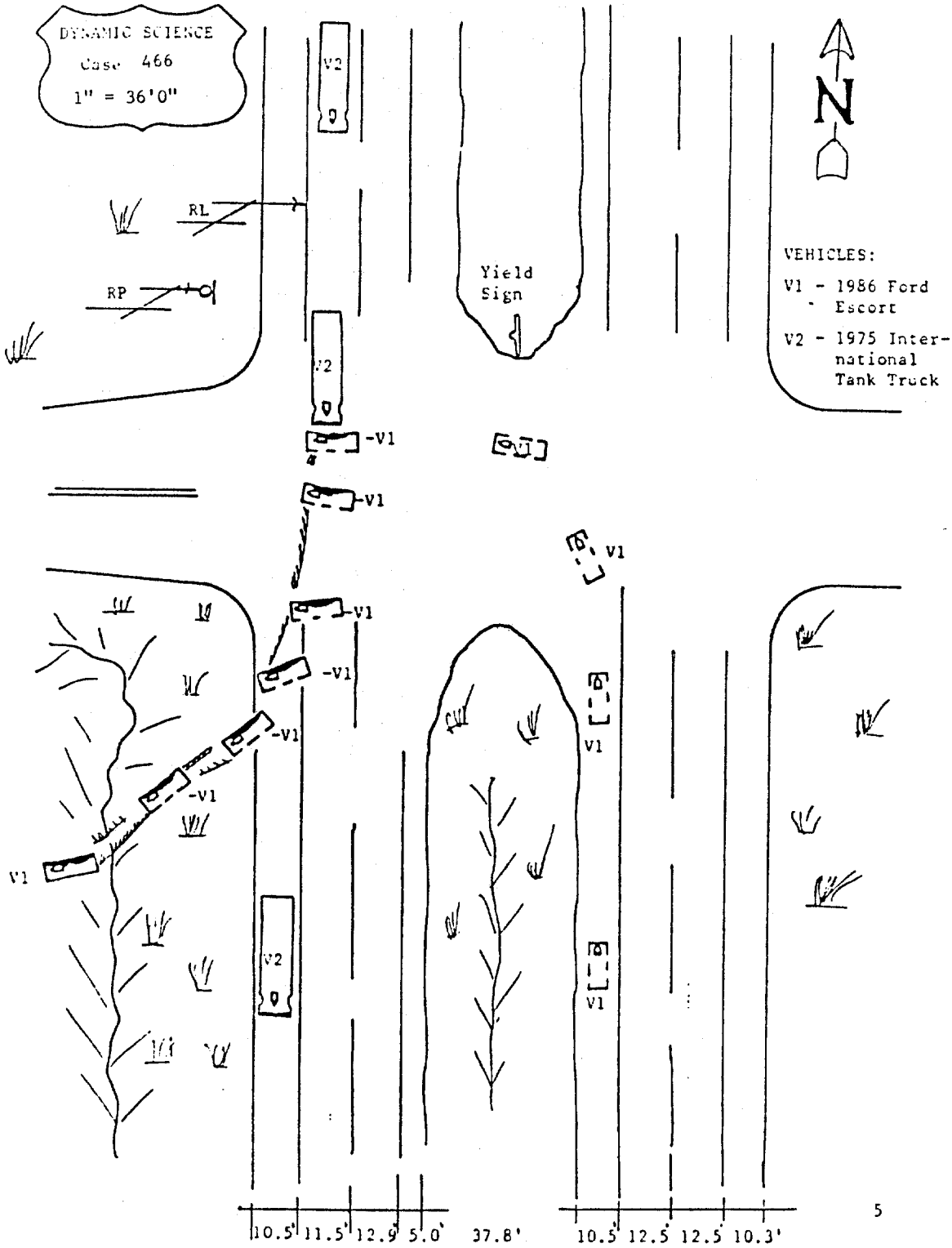
DYNAMIC SCIENCE
Case 466
1" = 36'0"
N
RL
RP
V2
V2
Yield Sign
VEHICLES:
V1 - 1986 Ford Escort
V2 - 1975 International Tank Truck
-V1
-V1
-V1
-V1
-V1
-V1
V1
V1
V1
V1
V1
V2
10.5'
11.5'
12.9'
5.0'
37.8'
10.5'
12.5'
12.5'
10.3'
5

PREVENTION AND INJURY REDUCTION - CASE 466

This accident occurred primarily because of driver inexperience or inattention. The recently licensed driver of V1 apparently didn't see the approaching truck, misjudged the truck's approach speed, or was distracted by the 3 other young occupants. Three possible solutions to this situation would be: stronger side protection which would have probably reduced the intrusion damage, installation of side air cushion restraint systems, and the development of electronic "Smart Highways".

The installation of stiffer protection devices in the sides of occupant compartments might not have been much use in this accident, where the vehicle was broadsided by a 51,000 pound truck, but if this protection had reduced the severity of the injuries by half, the fatality may not have occurred.

The installation of an air cushion restraint system which cushions against side as well as front impacts also probably would have reduced the injuries. If this system prevented or further reduced the injury severity by one half, the AIS 4 and 5 injuries also might not have occurred.

The advancement of "Smart Highways" would have warned the driver of the Ford Escort of the approaching truck, and depending upon how "smart" the device was, might even have stopped this vehicle from entering the highway. This technology is still experimental, but is envisioned to monitor the distances between vehicles and alert drivers or prevent drivers from entering into hazardous situations.

--- Crash Investigation Team

the car (2,161 cases of fatality). Most fatal accidents occur in rural areas and occur on roads with posted speed limits of 55 MPH (70%). About half of all fatal accidents of this type occur on straight and level roads and more than 60% involving a passenger car are on minor or principal arterial roads such as the one in this case.

Two door hard-tops are involved in about 30% of all accidents in which there are fatalities and account for more than half of all the passenger car occupant fatalities. About 29% of occupant fatalities ocurr as a result of side collisions.

As an interesting fact, while 12% of fatal accidents occur at rural junctions on the roadway, only 3% (lowest incidence) occur at road junctions controlled by yield signs as the one in this case was. Recommending the installation of a stop sign or a light would both increase the chances of a fatality.

The only other statistic of significance was that both the fatally injured occupant and the severely injured occupant were in the seats with the highest incidence of severe injury (right hand front and right side rear).

PSYCHOSOCIAL FOLLOW-UP - CASE 466

6 Months

This 15-year-old was discharged from Shock Trauma, following 45 days acute hospitalization, to an inpatient rehabilitation facility, non-ambulatory and following commands inconsistently. She was non-verbal but nodding appropriately to most questions, exhibiting moderate to severe memory and cognitive deficits.

At 3 months post-trauma, patient remained at inpatient rehabilitation facility, totally independent in activities of daily living and talking "a blue streak". At 4 months post-trauma, patient discharged from inpatient rehabilitation, returning to school part-time with outpatient therapy.

At 6 months post-trauma, patient continues cognitive therapy, attending school part-time. She presents minimal memory deficits and slight speech hesitancy but has made remarkable progress and is at grade level in Math and English. Irritability and outbursts are evidenced as well as typical "teen" behavior and efforts to increase her independence. Parents have not allowed her to obtain Driver's License and teen is angry about their "over-protection".

1 Year

Patient presents as a well-groomed attractive teen who has returned to school full-time and has returned to pre-injury athletic and social activities. Emotionally she is in more control although outbursts and irritability persist. She has traveled with family and has returned to functional status.

	1218	85	2765	160.70	66.60	27	94.0	19.90	1	18.00
	1219	85	2765	160.70	66.60	27	94.0	18.20	1	22.40
	1220	85	2765	160.70	66.60	27	94.0	19.30	1	29.10
	1221	85	2765	160.70	66.60	27	94.0	30.00	1	53.60
	960	83	1985	164.30	66.80	36	94.3	0.00	2	5.60
	961	83	1985	164.30	66.80	36	94.3	0.00	2	20.80
	509	82	2034	163.50	63.50	36	94.0	29.20	1	15.00
	206	81	2590	165.70	65.90	41	94.5	35.10	1	1.80
	353	81	2368	163.70	65.90	39	94.2	35.20	1	30.80
	373	81	2424	163.80	65.90	99	99.9	30.20	1	24.00
5H	1118	87	2822	168.80	64.20	43	93.8	29.50	1	19.10
	407	82	2576	164.00	65.90	99	94.2	35.10	1	24.50
	452	82	2584	163.80	54.00	40	94.5	34.50	1	24.00

This search had a considerable yield but had no cases that really approximated this accident. As a subsequent search, tests involving barriers were checked for using both side impacts (left and right) as selection criteria. As luck would have it, there was a test case on file where the barrier impactor was a truck bumper and the vehicle type was a Ford Escort. This case (Case #0961) involved a 90 degree right side collision. The decision to use the case was based upon the similarity of the test to the actual crash conditions (Use of a truck bumper at 90 degrees as an impactor) and the closeness of the crush profile of the test to that of the actual accident. The maximum crush in the test case was 21" while that of the actual accident was 24".
The characteristics of the test case (0961) were:

- Flat Impactor at 90 degrees
- Ford Escort 3 Door Hatchback (Length 164.3, width 66.8, wheelbase 94.3)
- Speed 32.2 MPH

Test Crash Pulse:

The test crash time curves for the vehicle COG and rear deck ae at Figures 466-2 and 466-3 respectively. These are y-axis pulses and they show an average 14 G pulse over a duration of 100 milliseconds when filtered at 100Hz. These curves were provided to the simulation team for use as input parameters to the model.

Test Injury Comparison:

There was unfortunately no data available for occupants in the crash test data base.

Significance of the Crash:

Approximately 1,900 accidents per year involve a car and a heavy truck. Of these 97% of all fatalities that occur are in

COGNITIVE AND COMMUNICATIVE ASSESSMENT - CASE 466

The patient was initially evaluated on T + 18 days and was inconsistently tracking objects with limited eye gaze. The patient was unable to follow commands. Oral movements restricted by chewing and bite reflex. The patient's cognitive-communicative skills were characteristic of RLAS (Rancho Los Amigos Score) Level II. Monitoring and treatment were recommend as the patient's medical status improved. The patient's speach could not be assessed and she was NPO; thus, her swallowing abilities could not be assessed.

By discharge (T + 45 days), the patient's cognitive-communicative skills were characteristic of RLAS (Rancho Los Amigos Score) VI. She was able to comprehend object names and answer some simple yes or no questions. She was able to read words and some short sentences with good comprehension. The patient was removed from the trach tube just prior to discharge, but was unable to achieve phonation. She was able to communicate by pointing to letters on an alphabet board, but was unable to grasp a pen to write words. Deficits were noted in short-term memory, concentration and reasoning. The patient passed the hearing screening and was on a P.O. diet.

BIODYNAMICS STUDY
CRASH COMPARISON, CASE 466

Crash Test Data:

On the initial search of the NHTSA vehicle database, using the vehicle make and model and the weight (51,000 lbs) of the truck as search keys, there were no tests found. The nearest match found involved a truck of 17,500 lbs. This test was not deemed useable.

The next try was a search on all Ford Escorts. Table 466-1 is the result of that search.

Table 466-1
Second Search

MAK	MOD	BOD	T#	YR	LBS.	LENGTH	WIDTH	COG	WBASE	SPEED	V	CRUSH
02	27	3H	1323	89	2630	169.60	65.90	41	93.8	29.70	1	15.40
			997	87	2740	167.20	65.90	39	94.0	34.70	1	21.70
			1216	85	2765	160.70	66.60	27	94.0	10.10	1	3.40
			1217	85	2765	160.70	66.60	27	94.0	19.80	1	12.10

T + 3.8 Seconds (estimate): Vehicle 1 came to final rest in a drainage area facing west-southwest on the west side of the highway. The driver of Vehicle 2 made a controlled stop on the west shoulder of the southbound lanes.

T + 1:00 Minutes: The police were notified. An off-duty officer in the vicinity responded immediately. Notification and arrival time are the same.

PREHOSPITAL AND HOSPITAL TIMELINE - CASE 466

T+ 1min: Ambulance receives call to respond.

T+ 9min: Ambulance arrives at scene. Initial field assessment reveals a blood pressure of 122/80, a heart rate of 88, a respiratory rate of 18, and a Glasgow Coma Score of 3. Prehospital care includes fluid resuscitation with the administration of 100 cc of crystalloid. The patient required extrication from the vehicle.

T+ 24min: Patient departs scene for MIEMSS/Shock Trauma by police medevac helicopter.

T+ 56min: Patient arrives at MIEMSS. Initial physiologic assessment of the patient reveals a blood pressure of 136/74, a heart rate of 104, a respiratory rate of 10, and a Glasgow Coma Score of 3. The patient's ISS (Injury Severity Score) = 50. Toxicology screen results were negative. Initial hospital care provided includes:

- -Evaluation by a MIEMSS trauma team,
- -Fluid resuscitation,
- -Full diagnostic evaluation including x-rays of the cervical spine, chest and pelvis. In addition to the toxicology screen, an arterial blood gas, a CBC (complete blood gas), an SMA-6 (routine blood chemistry) and UA (urinalysis) performed.

Initial clinical findings included the following:

- -Cerebral Contusion
- -Brain Stem Contusion
- -Scalp Laceration
- -Right Fracture Ribs
- -Right Pneumothorax
- -Fracture Right Pelvis (superior ramus)
- -Fracture Right Sacrum
- -Ruptured Bladder
- -Laceration Right Lower Extremity

Operative care included:

- -Exploratory Laparotomy
- -Repair Bladder Tear

T+24hours - 46days: Patient spends 36 days in intensive care and 10 days in intermediate care.

T+ 46days: Patient discharged from MIEMSS to an out-of-state rehabilitation hospital.

CRASH TIME LINE ANALYSIS - CASE 466

T - 5 Seconds: Vehicle 1, a 1986 Ford Escort driven by a 16 year old female was northbound on a 4 lane, divided, asphalt paved road in a rural environment. The only occupant in this vehicle wearing the available lap/shoulder belts was a 15 year old female in the right front seat. Neither the driver nor the two 15 year old female occupants in the left and right rear seats were wearing the available seat belts and the vehicle was not equipped with an air cushion restraint system. The northbound lanes change from a 2 lane undivided to a 4 lane divided roadway prior to an intersection with an east/west road and a major interstate approximately one mile north of the accident location. As the driver of Vehicle 1 approached the intersection, she decelerated and entered the left turn lane. Witnesses indicated she turned west and stopped at the yield sign prior to crossing the dual southbound lanes. Vehicle 2, a 1975 International Fleetstar tanker truck had turned south off the interstate and was approaching the intersection at an estimated speed of 50-60 miles per hour.

T - 0.79 to 1.1 Seconds (estimate): The driver of Vehicle 1 had completed her stop in the vicinity of the yield sign westbound and started accelerating westbound across the southbound lanes.

T - 0.0 Seconds: The front bumper of Vehicle 2 struck the right side of Vehicle 1 and intrusion into the right front and right rear of Vehicle 1 began.

T + 0.12 Seconds (estimate): As Vehicles 1 and 2 achieved maximum engagement, Vehicle 1 began rebounding 90 degrees from its original path. Severe pocketing occurred at the right front and right rear. The right side door hardware was pushed inward laterally causing multiple right side rib fractures, pulmonary contusions and a right kidney contusion to the front seat passenger. The right rear contour panel and arm rest started intruding into the passenger area. The right rear window shattered and the roof began both vertical and lateral intrusion. The intrusion combined with impact forces caused the right rear seated occupant to move rapidly to the right. The bumper of Vehicle 2 was approximately level with the bottom of the right window and occupant contact was very probable to the exterior front of Vehicle 2. Sheet metal flow and occupant contact points indicate that the right rear passenger sustained injuries including cerebral contusion, brain stem contusion, multiple fractured ribs with right pneumothoraces, fractured right pubic ramus and sacrum and ruptured bladder which were caused by this intrusion and impact forces. Lower right extremity and scalp lacerations were attributed to flying glass and vehicle induced forces while occurred while the vehicle traveled to final rest across rough terrain. The left lateral compression fracture (open) of the pelvis was probably caused by inter-occupant contact during intrusion between the unbelted left rear seat passenger and the case occupant.

PSYCHOSOCIAL TIMELINE - CASE 466

A 15-year-old tenth grade female student was admitted to MIEMSS Shock Trauma following a collision in which she was the right-side rear passenger in a car that was hit by a tractor trailer truck. The vehicle was driven by a recently-licensed 16-year-old driver who escaped uninjured. The 15-year-old right front-seat passenger, Study Patient #091, died at MIEMSS Shock Trauma at T + 3 days and was an organ donor. The left rear-seat passenger, another teenager, was also hospitalized, but with less serious injuries, and not selected for the study. Case study patient 466 sustained multiple trauma and brain injury. At T + 30 days, the patient was becoming more alert and focusing her eyes. Seemingly recognizing family members, the patient follows commands inconsistently.

At the time of the accident, the four girls had just left school, where they were immunized against measles, and were en route to the home of one of the passengers for lunch after dropping off 3 girls at the mall. Although the patient is usually a seatbelt wearer, this day she failed to do so. The driver of the vehicle has been having great difficulty coping with this crisis, staring at her friend from bedside, mute and sad. A referral was made for her individual counselling.

The patient's family, consisting of a mother who is a school nurse and active in the National Guard, and father who works for the government in top security matters, describe daughter, whom they adopted in Ethiopia at 3 months of age, as a very active, highly sociable teen. Religion plays an important role in the patient's life, being active in the church youth group, as it does in the family's life. The patient is also quite athletic and a member of track and volleyball teams as well as manager of the basketball team. Her parents portray her as a girl who is generally happy with life, enjoys babysitting, and looking forward to summer vacation. Although having experimented with drinking and smoking, neither is described as a problem. The patient is an average student, verbal and articulate and usually one who bounces back from disappointment. She is quite health conscious for a teenager, watches her diet and is generally not an impulsive girl. The patient had planned to take driver's education this summer and to obtain her license in the fall.

The patient has one brother who graduated from high school at T - 4 days and another brother who is 10 months younger than herself, who was also adopted in Ethiopia and is a 10th grader in the same class as the study patient. The family has lived a varied and adventurous life living in Ethiopia and Australia for several years due to the father's work. The family appears close-knit, spending time backpacking, canoeing and taking exotic vacations to various African nations. The family is expressive and warm, ministering to one another and a great source of active support for the patient, having every intention of getting her back into a canoe. At this time, it is anticipated that the patient will require long-term rehabilitation.

2.	2HICB5	371123	851.4	Brain Stem Contusion	arm rest, window including frame & glass. "B" pillar, roof siderail & front bumper of V2.
3.	2HULI1	921223	873.0	Scalp Lacerations < 2.5 cm	Impact forces & flying glass (right side window)
4.	2CRFS3	371123	807.04	Fractured Ribs (Multiple)	Combination R/S panel, arm rest, window including frame & glass. "B" pillar, roof siderail & front bumper of V2.
5.	*	371123	860.0	Right Pneumothoraces	
6.	2PPFS3	371123	808.8	Fractured Left Lateral Compression Pelvis-Grade I	Inter-occupant & Intrusion
7.	2PAFS2	461123	808.2	Fracture, Right Superior Ramus	Combination R/S panel, arm rest, window including frame & glass. "B" pillar, roof siderail & front bumper of V2.
8.	2PPFS3	371123	806.6	Fractured Sacrum, Right Side	
9.	2MIRG4	371123	867.0	Ruptured Bladder,	
10.	2YRLI2	921123	916.0	Lacerations, right lower extremity	

* - coded as one injury (#4 and #5)

SUMMARY - CASE 466 (025)

This two vehicle accident occurred on a cloudy, rainy weekday in mid June, 1989. Vehicle 1, a 1986 Ford Escort, was being driven by a recently licensed 16 year old female and had three other 15 year old female occupants. The occupant in the right front seat was the only occupant wearing the available lap/shoulder belts. Vehicle 2 is a 1975 International Fleetstar tanker truck and was being driven by a 50 year old male. Vehicle 2 had a scale verified weight of 51,000 pounds. The driver of Vehicle 1 was northbound on a 4 lane, divided, asphalt paved road located in a rural environment. She had slowed and moved left into the left turn lane in preparation for crossing the median, the southbound lanes and proceeding westbound on an intersecting 2 lane east-west road. This intersection is controlled by flashing red signals for east-west traffic and flashing yellow signals for north-south traffic. It has fixed yield signs at the departure points for east-west crossover traffic. The driver of Vehicle 1 made a left hand turn westbound and crossed lane 2 and was within the prolongation of lane 1 of southbound traffic when struck by Vehicle 2. At impact, the frontal plane of Vehicle 2 struck the right side of Vehicle 1 producing a direct damage width of approximately 125.5 inches and a maximum crush of 24.5 inches. Severe intrusion by the bumper of Vehicle 2 occurred and was measured as 11 inches laterally into the right rear passenger area and 9 inches laterally/vertically at the "B" pillar/roof area. Occupant contact points and torso pocketing indicated that this severe intrusion into the right rear side panel arm rest and lower portion of the "B" pillar combined with impact forces and the exterior of surface of Vehicle 2's bumper produced the case occupant's cerebral contusion, brain stem contusion, scalp lacerations, fractured ribs with right pneumothoraces, right pubic ramus fracture, sacrum fracture and ruptured bladder. Inter-occupant contact between the unbelted left rear passenger and the case occupant combined with the intruding right side contributed to the left lateral compression fracture of the pelvis. The lacerations of the right lower extremities were attributed to the broken glass and deformed plastics as the impact forces projected Vehicle 1 to final rest. All four occupants in this accident sustained incapacitating injuries and were transported to hospitals, admitted and were treated for the injuries. Our case occupant with maximum AIS-5 injuries was transported by ambulance to a major shock trauma hospital for treatment. The roof of the vehicle was removed by rescue personnel during occupant extrication.

BODY CONTACTS AND INJURIES TABLE-CASE 466

15 year old female; passenger; 1986 Ford Escort; side impact

OIC/AIS CODE	ICD-9	BODY CONTACTS AND INJURIES	CONTACT POINT
1. 2HUCB3 371123	851.0	Cerebral Contusion	Combination R/S panel,

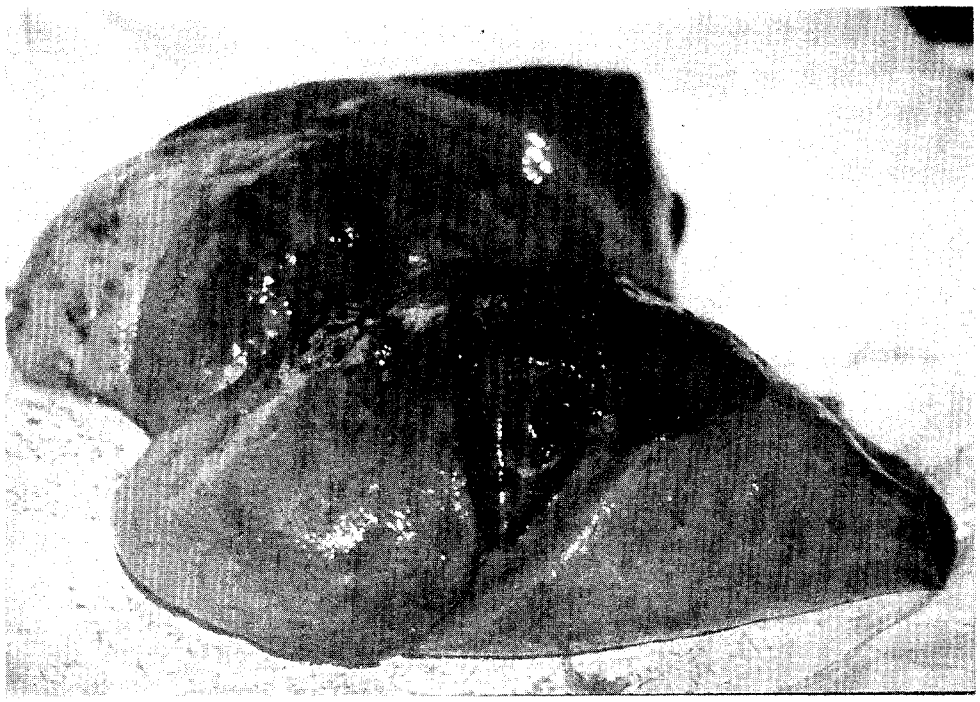

091C Post-mortem examination of the lung revealing multilobar consolidation and right middle lobe contusion.

Contact Point- A or B pillar and roof side rail and exterior frontal plane of the striking vehicle (primarily bumper)
Type of Crash- Right lateral impact
Estimated Force of Impact- Chest- 900 lbs.

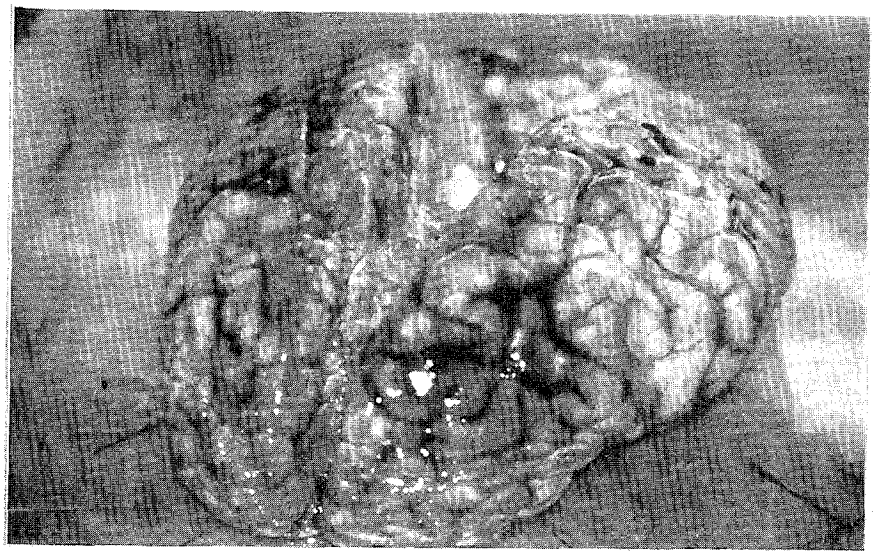

091A Post-mortem examination of brain revealing diffuse cerebral edema and old clot and hemmorhage over frontal lobe.

Contact Point- Combination right side interior surface hardware and arm rest, window glass including surface
Type of Crash- Right lateral impact
Estimated Force of Impact- 1600 lbs.

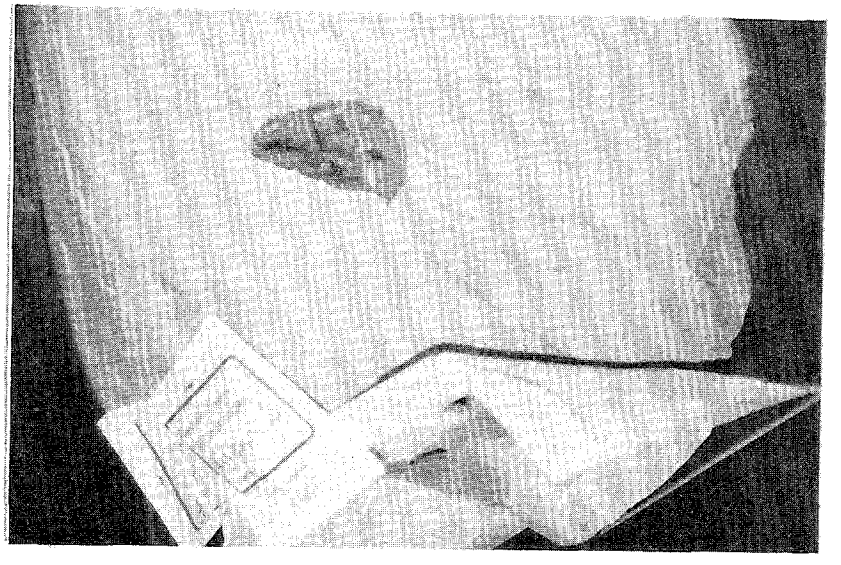

091B Operative photo of resected spleen with lacerations.

Contact Point- Interoccupant contact
Type of Crash- Right side impact
Estimated Force of Impact- Lower Torso- 730 lbs.

SELECTED PHOTOGRAPHS, CASE 091

5.



V2 (1975 Fleetstar tanker truck). Crush = 2.0 inches.

6.



Scene from V1's direction of travel. Impact area is approximately 20 feet west of the vehicle to the left.

SELECTED PHOTOGRAPHS, CASE 091

3.



V1 exterior shows intrusion by right door area into passenger compartment

4.



resulting in right dash buckling. Contact points shown are r/s interior surface hardware, window glass, frame sill, A or B pillar, and roof side rail producing fatal injuries to case occupant

SELECTED PHOTOGRAPHS, CASE 091

1.

V1 (1986 Ford Escort 3 door hatchback) Front to right side impact. Crush = 24.5 inches. Intrusion right front passenger door area - 10 inches into occupant area.

2.



V2's bumper produced severe intrusion causing a closed head trauma w/LOC >24 hrs. (AIS-5), bilateral pulmonary contusion w/hemopneumothoraces (AIS-4) & other injuries in case occupant.

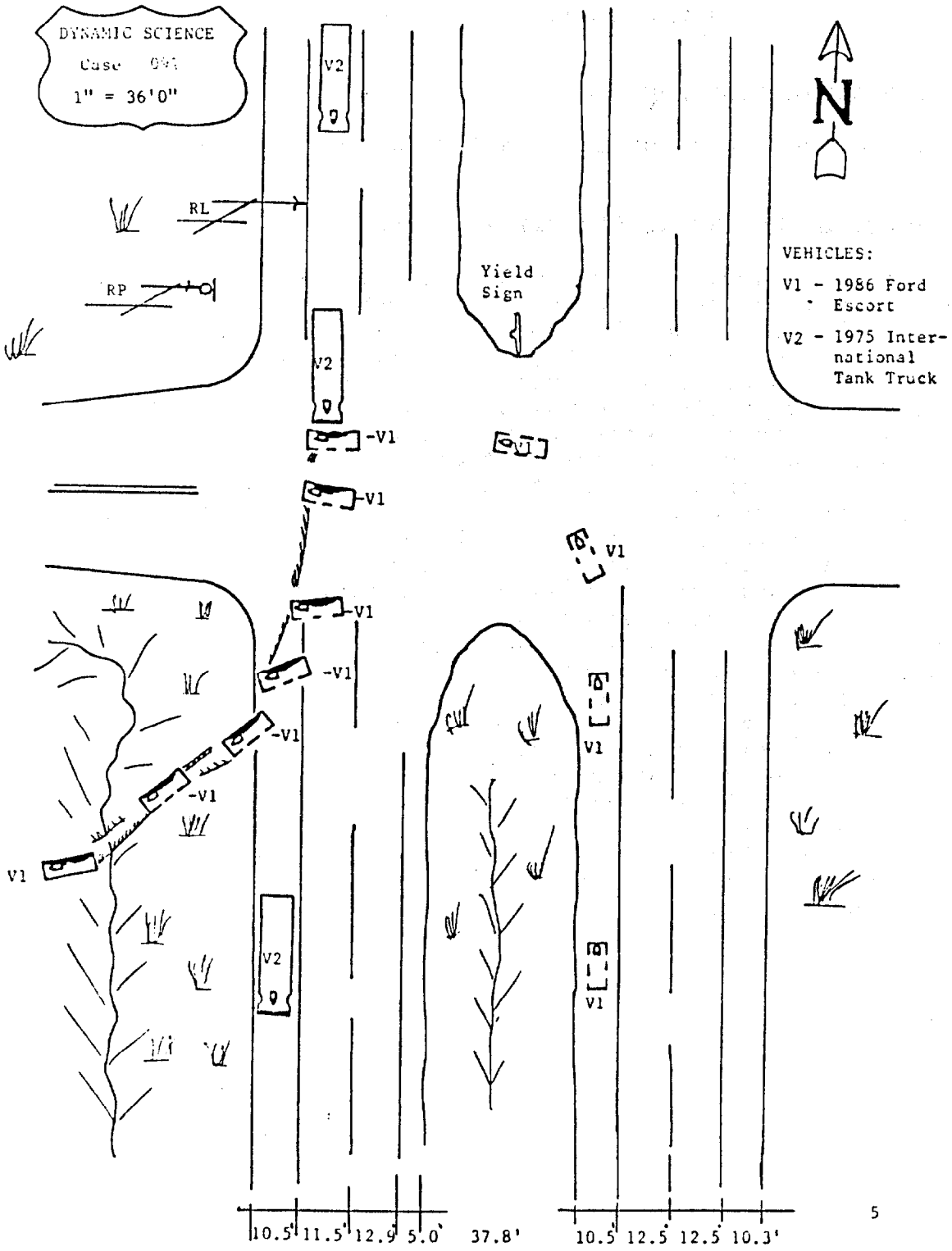
DYNAMIC SCIENCE
Case
1" = 36'0"
N
RL
RP
V2
V2
Yield Sign
VEHICLES:
V1 - 1986 Ford Escort
V2 - 1975 International Tank Truck
-V1
-V1
-V1
-V1
-V1
-V1
V1
V1
V1
V1
V1
V2
10.5'
11.5'
12.9'
5.0'
37.8'
10.5'
12.5'
12.5'
10.3'
5

The only other statistic of significance was that botht the fatally injured occupant and the severely injured occupant were in the seats with the highest incidence of severe injury.

PSYCHOSOCIAL FOLLOW-UP

No follow-up. Patient expired 3 days post injury.

PREVENTION AND INJURY REDUCTION - CASE 091

This accident occurred primarily because of driver inexperience or inattention. The recently licensed driver of V1 apparently didn't see the approaching truck, misjudged the truck's approach speed, or was distracted by the 3 other young occupants. Three possible solutions to this situation would be: stronger side protection which would have probably reduced the intrusion damage, installation of side air cushion restraint systems, and the development of electronic "Smart Highways".

The installation of stiffer protection devices in the sides of occupant compartments might not have been much use in this accident, where the vehicle was broadsided by a 51,000 pound truck, but if this protection had reduced the severity of the injuries by half, the fatality may not have occurred.

The installation of an air cushion restraint system which cushions against side as well as front impacts also probably would have reduced the injuries. If this system prevented or further reduced the injury severity by one half, the AIS 4 and 5 injuries also might not have occurred.

The advancement of "Smart Highways" would have warned the driver of the Ford Escort of the approaching truck, and depending upon how "smart" the device was, might even have stopped this vehicle from entering the highway. This technology is still experimental, but is envisioned to monitor the distances between vehicles and alert drivers or prevent drivers from entering into hazardous situations.

As a subsequent search, tests involving barriers were checked for using both side impacts (left and right) as selection criteria. As luck would have it, there was a test case on file where the barrier impactor was a truck bumper and the vehicle type was a Ford Escort. This case involved a 90 degree right side collision. The decision to use the case was based upon the closeness of the crush profile. The maximum crush in the test case was 21" while that of the actual accident was 24". The characteristics of the test case (0961) were:

- Flat Impactor at 90 degrees
- Ford Escort 3 Door Hatchback (Length 164.3, width 66.8, wheelbase 94.3)
- Speed 32.2 MPH

Test Crash Pulse:

The test crash time curves for the vehicle COG and rear deck ae at Figures 466-2 and 466-3 respectively. These are y-axis pulses and they show an average 14 G pulse over a duration of 100 milliseconds when filtered at 100Hz.

Test Injury Comparison:

There was unfortunately no data available for occupants in the crash test data base.

Significance of the Crash:

Approximately 1,900 accidents per year involve a car and a heavy truck. Of these 97% of all fatalities that occur are in the car (2,161 caess of fatality). Most fatal accidents occur in rural areas and occur on roads with posted speed limits of 55 MPH (70%). About half of all fatal accidents of this type occur on straight and level roads and more than 60% involving a passenger car are on minor or principal arterial roads such as the one in this case.

Two door hard-tops are involved in about 30% of all accidents in which there are fatalities and account for more than half of all the passenger car occupant fatalities. About 29% of occupant fatalities occur as a result of side collisions.

As an interesting fact, while 12% of fatal accidents occur at rural junctions on the roadway, only 3% (lowest incidence) occur at road junctions controlled by yield signs as the one in this case was. Recommending the installation of a stop sign or a light would both increase the chances of a fatality.

recovery unit.
T+ 3 days: Patient expires.

Other victims in the same crash include a 15 year old female who was also admitted to MIEMSS/Shock Trauma as Study Patient 466. More information pending.

BIODYNAMICS STUDY
CRASH COMPARISON, Case 091

Initial Searches:

This case is the same as case 466 except that this case studies the rear seat occupant while 466 is for the right front seat occupant.

On the initial search of the NHTSA vehicle database, using the vehicle make and model and the weight (51,000 lbs) of the truck as search keys, there were no tests found. The nearest match found involved a truck of 17,500 lbs. This test was not deemed useable.

The next try was a search on all Ford Escorts. Table 466-1 is the result of that search.

Table 466-1
Second Search

MAK	MOD	BOD	T#	YR	LBS.	LENGTH	WIDTH	COG	WBASE	SPEED	V	CRUSH -
02	27	3H	1323	89	2630	169.60	65.90	41	93.8	29.70	1	15.40
			997	87	2740	167.20	65.90	39	94.0	34.70	1	21.70
			1216	85	2765	160.70	66.60	27	94.0	10.10	1	3.40
			1217	85	2765	160.70	66.60	27	94.0	19.80	1	12.10
			1218	85	2765	160.70	66.60	27	94.0	19.90	1	18.00
			1219	85	2765	160.70	66.60	27	94.0	18.20	1	22.40
			1220	85	2765	160.70	66.60	27	94.0	19.30	1	29.10
			1221	85	2765	160.70	66.60	27	94.0	30.00	1	53.60
			960	83	1985	164.30	66.80	36	94.3	0.00	2	5.60
			961	83	1985	164.30	66.80	36	94.3	0.00	2	20.80
			509	82	2034	163.50	63.50	36	94.0	29.20	1	15.00
			206	81	2590	165.70	65.90	41	94.5	35.10	1	1.80
			353	81	2368	163.70	65.90	39	94.2	35.20	1	30.80
			373	81	2424	163.80	65.90	99	99.9	30.20	1	24.00
		5H	1118	87	2822	168.80	64.20	43	93.8	29.50	1	19.10
			407	82	2576	164.00	65.90	99	94.2	35.10	1	24.50
			452	82	2584	163.80	54.00	40	94.5	34.50	1	24.00

a drainage area facing west-southwest on the west side of the highway. The driver of Vehicle 2 made a controlled stop on the west shoulder of the southbound lanes.

T + 1:00 Minutes: The police were notified. An off-duty officer in the vicinity responded immediately. Notification and arrival time are the same.

PREHOSPITAL AND HOSPITAL TIMELINE - CASE 091

T+ 7min: Ambulance receives call to respond.

T+ 9min: Ambulance arrives at scene. Initial field assessment reveals a blood pressure of 90/palp, a heart rate of 76, a respiratory rate of 16, and a Glasgow Coma Score of 3. Prehospital care includes fluid resuscitation with the administration of 2000cc of crystalloid. An esophogeal obturator airway was inserted in the field. The patient required extrication from the vehicle.

T+49min: Patient departs scene for MIEMSS/Shock Trauma by ground ambulance.

T+76min: Patient arrives at MIEMSS/Shock Trauma. Initial physiologic assessment of the patient reveals a blood pressure of 80/palp, a heart rate of 110, a respiratory rate of 26, and a Glasgow Coma Score of 3. The patient's ISS (Injury Severity Score) = 50. Toxicology screen results were negative. Initial hospital care provided includes:

- -Evaluation by a MIEMSS trauma team,
- -Fluid resuscitation,
- -Emergent endotracheal intubation,
- -Diagnostic peritoneal lavage with grossly positive results,
- -Full diagnostic evaluation including x-rays of the cervical spine, chest and pelvis. In addition to the toxicology screen, an arterial blood gas, a CBC (complete blood count), an SMA-6 (routine blood chemistry) and UA (urinalysis) performed.
- -Placement of bilateral chest tubes for evacuation of the hemopneumothoraces.

Injuries noted include:

- -Closed Head Injury with Diffuse Cerebral Edema, Intraventricular Hemorrhage and Loss of Consciousness,
- -Bilateral Hemopneumothoraces with a Left Tension Pneumothorax,
- -Multiple Rib Fractures,
- -Left Clavicular Fracture,
- -Right Kidney Contusion,
- -Splenic Laceration (Parenchymal Injury/Hilar Included)

Operative care included:

- -Splenectomy,
- -Surgical placement of intracranial monitoring device as well as an intraventricular catheter.

A complication developed by the patient was respiratory failure.

T+12hours - 3 days: Patient spends 3 days in critical care

CRASH TIMELINE - CASE 091

T - 5 Seconds: Vehicle 1, a 1986 Ford Escort driven by a 16 year old female was northbound on a 4 lane divided, asphalt paved road in a rural environment. The only occupant in this vehicle wearing the available lap/shoulder belts was a 15 year old female in the right front seat. Neither the driver nor the two 15 year old female occupants in the left and right rear seats were wearing the available seat belts and the vehicle was not equipped with an air cushion restraint system. The northbound lanes change from a 2 lane undivided to a 4 lane divided roadway prior to an intersection with an east/west road and a major interstate approximately one mile north of the accident location. As the driver of Vehicle 1 approached the intersection, she decelerated and entered the left turn lane. Witnesses indicated she turned west and stopped at the yield sign prior to crossing the dual southbound lanes. Vehicle 2, a 1975 International Fleetstar tanker truck had turned south off the interstate and was approaching the intersection at an estimated speed of 50-60 miles per hour.

T - 0.79 to 1.1 Seconds (estimate): The driver of Vehicle 1 had completed her stop in the vicinity of the yield sign westbound and started accelerating westbound across the southbound lanes.

T - 0.0 Seconds: The front bumper of Vehicle 2 struck the right side of Vehicle 1 and intrusion into the right front and right rear of Vehicle 1 began.

T + 0.12 Seconds (estimate): Vehicle 1 and Vehicle 2 achieved maximum engagement and Vehicle 1 began rebounding 90 degrees from its original path. Severe pocketing occurred at the right front and right rear seating positions. The right side door hardware was pushed inward laterally causing multiple right side rib fractures, pulmonary contusions and a right kidney contusion to the front seat passenger. As the door was pushed inward, the right front occupant's head contacted the right door glass and frame and probably the exterior surface of the striking vehicle at bumper level. The forces involved also caused the roof to intrude both vertically and laterally. The combination of roof, window, window frame and exterior of V2 contributed to the closed head trauma with diffused edema and intraventricular hemorrhage. Sheet metal flow and occupant contact points indicate the unbelted 16 year old female driver was displaced toward the right and inter-occupant contact occurred. Severe injuries consisting of left pulmonary contusions, fractured left ribs and a fractured left clavicle have been attributed to this occupant contact. The severe injuries sustained by the right rear seated occupant include a closed head trauma with loss of consciousness for more than 24 hours, a diffused cerebral edema, an intraventricular hemorrhage, and a bilateral pulmonary contusion with a hemopneumothoraces and are documented in case 466.

T + 3.8 Seconds (estimate): Vehicle 1 came to final rest in

2.2HUUB3	371113	348.5	Diffused cerebral edema	rest, window glass including surface,
3.*		853.0	Intraventricular hemorrhage	hardware and arm rest, window glass including
4.2CRCP4	371113	861.21	Bilateral pulmonary contusion with --	frame sill, A or B pillar and roof
5.2CLCP4	371113	861.21	Hemopneumothoraces	side rail and exterior frontal
6.		860.4	**	plane of the striking vehicle
7.2CRFS2	371113	807.08	Bilateral multiple rib fractures***	primarily the front bumper
---				
8.2CLFS2	161200	807.08	Bilateral multiple rib fractures***	Inter-occupant contact
9.2SLFS2	161200	810.0	Fractured left clavicle	Inter-occupant contact
10.2MLLQ3	161200	865.03	Laceration, spleen	Inter-occupant contact /impact forces
11.2MRCK3	371113	866.01	Contusion, right kidney	Same as contact points 1 - 7

* - Coded as one injury (#2 and #3)
** - Coded separately
*** - Coded by aspect

PSYCHOSOCIAL SUMMARY - CASE 091

Psychosocial information could not be obtained for this study patient from either the patient or the patient's family. The patient arrived at MIEMSS/Shock Trauma unresponsive and expired at T + 3 days, never having regained consciousness.

SUMMARY - CASE 091 (024)

This two vehicle accident occurred on a cloudy, rainy weekday in the summer. Vehicle 1, a 1986 Ford Escort, was being driven by a recently licensed 16 year old female and had three other 15 year old female occupants. The occupant in the right front seat was the only occupant wearing the available lap/shoulder belts. Vehicle 2 is a 1975 International Fleetstar tanker truck and was being driven by a 50 year old male. Vehicle 2 had a scale verified weight of 51,000 pounds. The driver of Vehicle 1 was northbound on a 4 lane, divided asphalt paved road located in a rural environment. She had slowed and moved left into the left turn lane in preparation for crossing the median, the southbound lanes and proceeding westbound on an intersecting 2 lane east-west road. This intersection is controlled by flashing red signals for east-west traffic and flashing yellow signals for north-south traffic. It has fixed yield signs at the departure points for east-west crossover traffic. The driver of Vehicle 1 made a left hand turn westbound and crossed lane 2 and was within the prolongation of lane 1 of southbound traffic when struck by Vehicle 2. No pre-crash braking evidence by Vehicle 2 was noted.

At impact, the frontal plane of Vehicle 2 struck the right side of Vehicle 1 producing a direct damage width of approximately 125.5 inches and a maximum crush of 24.5 inches. Severe intrusion by the bumper of Vehicle 2 occurred and was measured as 10 inches at the right front passenger area laterally and 9 inches laterally/vertically at roof level. Occupant contact points and torso pocketing indicate that this intrusion by the right door and associated hardware combined with impact forces and the exterior surface of Vehicle 2's bumper produced the case occupant's closed head trauma with diffused cerebral edema and intraventricular hemorrhage, multiple right rib fractures, right kidney contusion and bilateral hemopneumothoraces. The inner occupant contact between this occupant and the unbelted driver probably caused the reported left clavicle fracture and spleen laceration. All four occupants in this accident sustained incapacitating injuries and were transported to hospitals, admitted and were treated for the injuries. Our case with maximum AIS-5 injuries was transported by ambulance to a major shock trauma hospital and expired 3 days later. The roof of the vehicle was removed by rescue personnel during occupant extrication.

BODY CONTACTS AND INJURIES TABLE-CASE 091
15 year old female; passenger; 1986 Ford Escort; side impact

OIC/AIS CODE	ICD-9	BODY CONTACTS AND INJURIES	CONTACT POINT
1.2HWKB5	371113	854.06 Closed head trauma w/LOC > 24 hrs.	Combination R/S interior surface hardware and arm

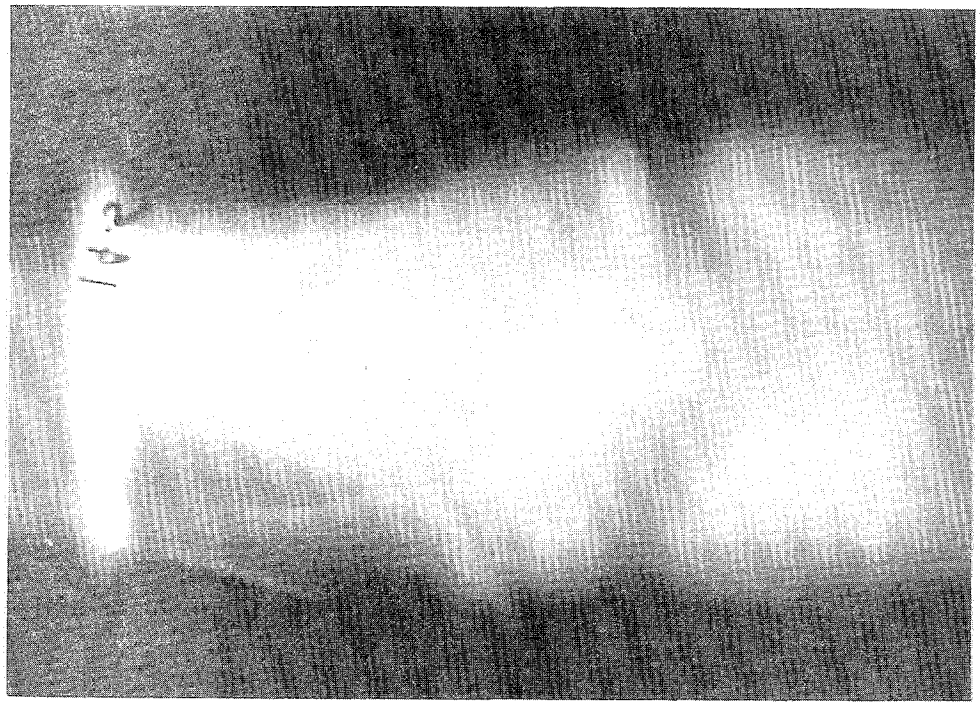

342C X-Ray revealing a comminuted fracture of the right proximal tibia extending into the joint.

Contact Point- Lower left instrument panel
Type of Crash- Frontal impact

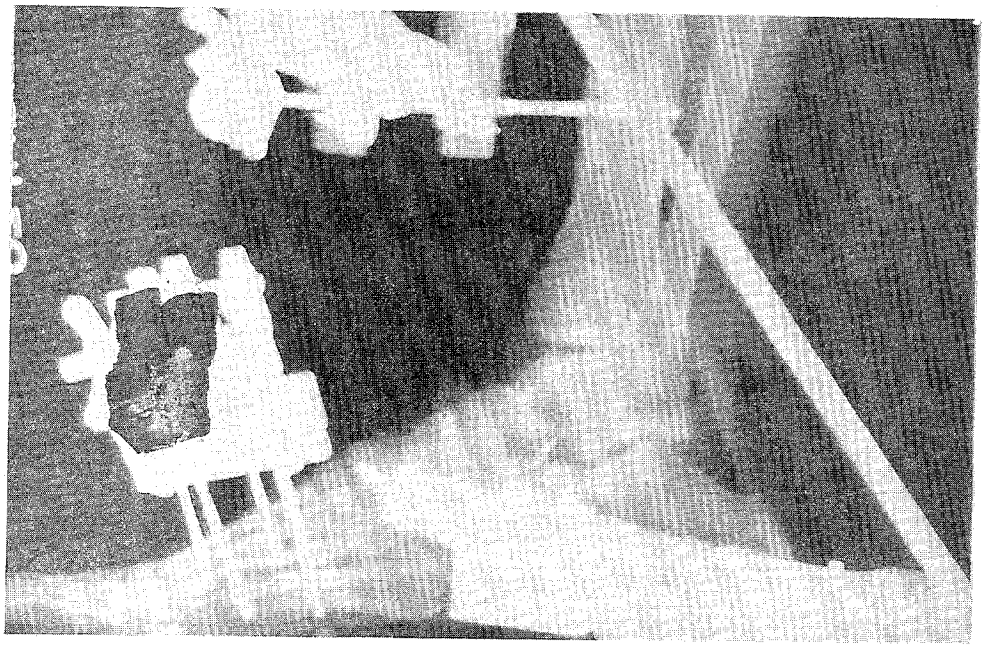

342D Postreduction X-Ray revealing right distal tibia and talus fractures and external fixator in place.

Contact Point- Brake Pedal
Type of Crash- Frontal impact
Estimated Force of Impact- Right Upper Leg- 1600 lbs.

342A Multiple facial and scalp abrasions. The patient has been endotracheally intubated and is cervically immobilzed with a Philadelphia Collar.

Contact Point- Windshield
Type of Crash- Frontal impact

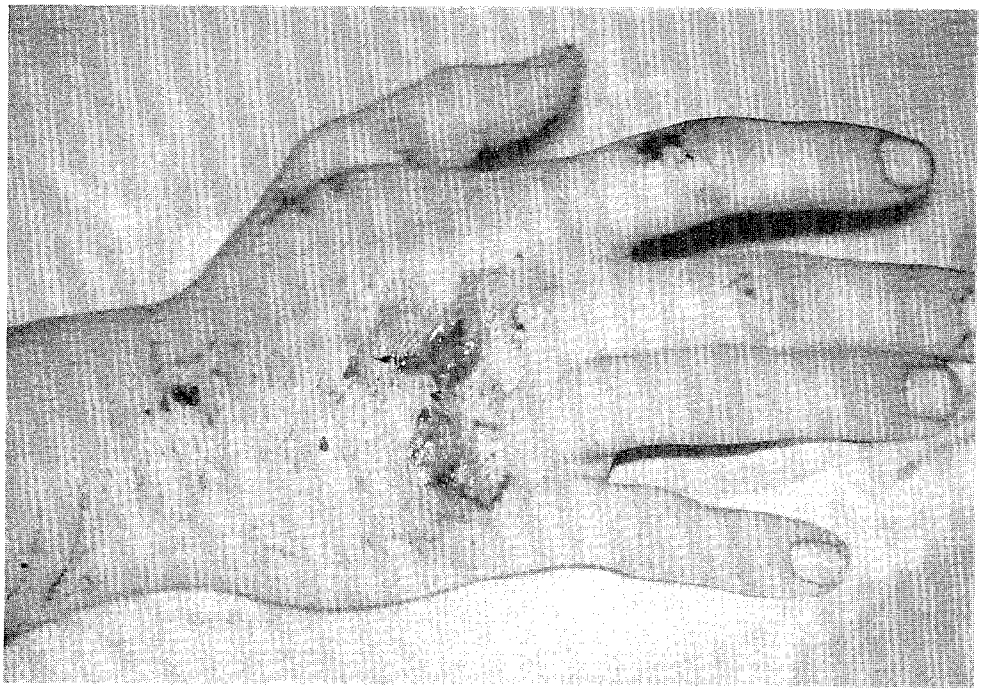

342B Multiple abrasions and lacerations of the dorsum of right hand.

Contact Point- Unknown
Type of Crash- Frontal impact

SELECTED PHOTOGRAPHS, CASE 342

5.



V2 (1983 Ford F-250 pickup). Side underride. Delta V = 13 - 17 m.p.h. Max sheet metal crush = 14.1 inches. Frame crush= 4.4"

6.



V2 left side. Frame shifted 4.4 inches from direct impact; V1's left front.Left rear wheel dislodged; V1's right front.

SELECTED PHOTOGRAPHS, CASE 342

3.

V1 driver's position. Windshield (AIS-2 head, AIS-1 face). Steering rim (AIS-5 chest, AIS-1 face). Driver unrestrained.

4.



V1 driver's position. Lower Left Instrument Panel (AIS-2 lower leg). Brake pedal (AIS-3 ankle). Left windshield intrusion= 10.5"

SELECTED PHOTOGRAPHS, CASE 342

1.



Scene. V2 direction of travel. 2-lane state highway. Center of photo shows V1 skid and impact point. V2 FRP in field to right.

2.



V1 (1987 Nissan Pulsar NX). Front override impact. Delta V= 19-23 m.p.h. Max crush = 20.5 inches at right front bumper corner.

COLLISION SCHEMATIC
CASE 342

SCALE: 1" = 20'

VEHICLES:

V1 is a 1987 Nissan Pulsar NX 2 door coupe

V2 is a 1983 Ford F-250 pickup truck

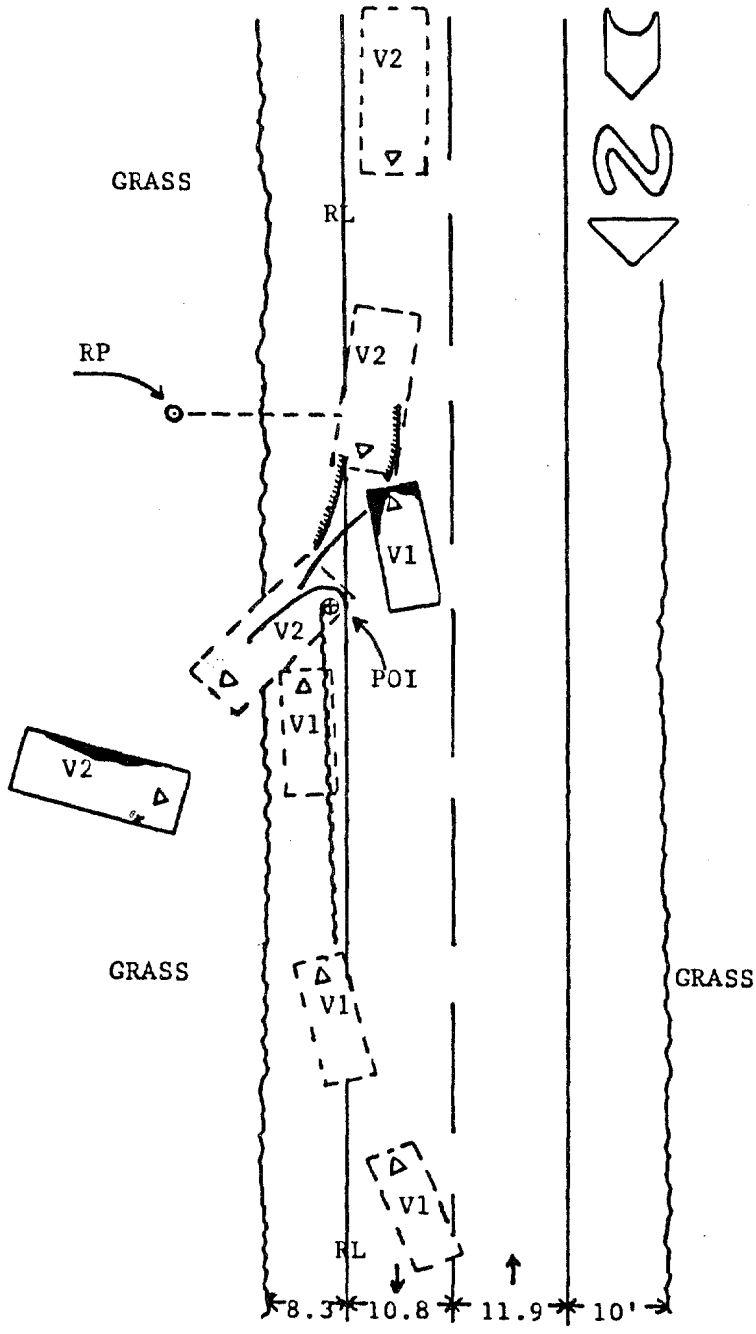

reaction time.

Had these vehicles been equipped with anti-lock brakes, this collision may have been avoided since the driver of the case vehicle was trying to steer during the skid. If the driver of the case vehicle had not been under the influence of alcohol, his reaction time might have been reduced by a full second, or better yet, he may have never crossed the roadway to begin with.

Another obvious problem with this crash that contributed to its severity is the incompatibility of vehicle heights which leads to an override/underride situation. If the vehicles had had similar ground clearance, this crash would have been a very low Delta V sideswipe. The pickup was substantially higher than the Nissan Pulsar. This not only created a blunt frontal type impact between the Nissan and the undercarraige of the pickup, it also enabled a level of intrusion to occur in the Nissan that is indicative of a much higher Delta V. None of the 3 occupants in the Nissan (our case vehicle) were using restraints. The center rear seat passenger had no restraint available to him. This is unfortunate since his forward motion magnified the forces that were applied to the front seat occupants. All 3 occupants' heads hit the windshield. There was considerable tissue noted in the glass. An anti-lacerative windshield would certainly have reduced injury. Had our Case (the driver) and the right front passenger been wearing the available manual lap and shoulder belts, they may have avoided contact with the windshield. In addition, had the rear seat passenger been belted, our case's most severe injury (AIS-5) may not have occurred, and if an Air Bag had deployed from the steering hub, I think it is safe to assume that the injury (flail chest) definitely would not have occurred.

---- Jerry Jackson

PREVENTION COMMENTS - CASE 342

The patient is a 32 year old male under the influence of alcohol who crossed the line and impacted a truck. This incident may have been prevented by the installation of some sort of breath test ignition device for alcohol control. Injuries sustained by this victim would have been reduced by the use of restraints as well as by the presence of an airbag.

PSYCHOSOCIAL FOLLOW-UP - CASE 342

6 Months

Patient discharged home with outpatient physical therapy from Shock Trauma following 22 days acute care. At 3 months post-trauma, patient independent in activities of daily living and ambulating without assistance, although retains small limp. Patient is not working and having difficulty locating a job. Patient has stopped drinking and joined AA. Patient now lives with male friend and has continued sporadic contact with his children. Girlfriend remains involved and supportive and out of necessity took out loan to purchase new car, however relationship has changed.

Patient exhibits irritability and is depressed due to lack of job prospects. Legal suits have been filed against patient and he remains haunted by crash. In addition, patient's father, with whom he had ambivalent relationship, died suddenly and patient faced with feeling of abandonment and loss.

1 Year

Contacted patient's girlfriend who reports she no longer sees patient. She reports that he remains unemployed, however whereabouts unknown. No other family available.

PREVENTION AND INJURY REDUCTION - CASE 342

There are several prevention ideas to discuss in this case. The obvious factor here is again alcohol. Our Case had a BAC. higher than .7. The case vehicle was traveling on the wrong side of the road, and the other vehicle really did the right thing by moving to the right. Many crashes happen as a result of conflicting avoidance maneuvers, and as a rule it is generally safer to stay on the proper side of the road when attempting to avoid a crash. One can only hope that the opposing vehicle will also attempt similar maneuvers. Unfortunately, our normal reaction is to lock the brakes which prohibits further steering. Both drivers in this case locked the brakes about 35 feet from impact, so the vehicles were still 70 feet apart when they were commited to trajectories that led to collision. When you consider the reaction times of the drivers with relation to the travel speeds of the vehicles, the vehicles were easily 300 feet apart when their drivers realized that a potentially harmful situation existed. Dr. J. Stannard Baker performed many studies in reference to driver reaction times and there is real scientific and legal validity to their use. He said that typically, a healthy person's brain will take about .75 seconds to analyse a traffic situation under normal conditions, and another .75 seconds will pass before the person's decision to brake results in skid marks on the pavement. Again, this is under normal conditions that do not account for alcohol influence, fatigue, inattention, or other factors that substantially raise the

CRASH COMPARISON - CASE 342

The cases used for comparison are covered in our simulation write up. The simulation engineer retrieved and analyzed the crash curves.

Significance of the Crash:

This accident involved an unrestrained occupant. Aproximately 29% of all crashes resulting in injuries of any severity involved lack of use of available restriants. In fact the statistics show that unrestrained occupants are four times more likely to sustain AIS 3 or higher injuries that restrained and are 2.5 times more likey to be hospitalized or transported for treatment.

This case was a driver and we know from crash histories that 36% of the time the driver will be unrestrained. The conditions of the crash are fairly common. 43% of crashes with a vehicle in transport result in an AIS greater than 1 and head on crashes are two times as likely to result in an AIS greater than three than are crashes at any other angle. As an additional interesting statistic, of the passenger car class, the two door coupe is the most likely configuration of all to be involved in a fatal accident. This accident was not fatal but could very easily have been.

The accident occurred on an asphalt state 2-lane highway at aspeed 52-66 MPH (36-40 at impact). the Delta V was estimated at 19-23 by the accident investigation team. About 31% of all such crashes result in an AIS greater than or equal to 1. The driver is among the most common age group for incidences of this type. The objects in the car which apparently caused the worst injuries are among the most common severe injury producers, the steering wheel and the Windshield (22% combined). It is not surprising that the injuries were severe. With intrusions of the magnitude seen here (3.5" at the low end) 66% of the cases will experience AIS >= 1 and 4% AIS >= 3. When one looks at the maximum intrusion of 10.5", the likelihood of injury becomes 79% AIS >= 1 and 9% >= 3.

This crash is fairly common and the injury severity is consistent with the conditions of the accident as compared to national statistics. The only surprising thing is that it was not a fatal accident. After all, 65% of al passenger car crashes ar fatal and there was very severe intrusion involved and the occupant did impact the steering wheel and the windshield which are the two biggest severe injury producers. Further, head on accidents are twice as likely to produce AIS >= 3 than other angles of impact.

cervical spine, chest and pelvis. In addition to the toxicology screen, an arterial blood gas, a CBC (complete blood count), an SMA-6 (routine blood chemistry) and UA (urinalysis) were performed.

Injuries noted include:

-Closed head injury with loss of consciousness,
-Multiple facial abrasions,
-Closed Nasal fracture,
-Right flail chest and hemothorax (multiple rib fractures,
-Right tibia fracture,
-Right ankle fracture with talar dislocation

Operative care includes:

-Open reduction of nasal fracture,
-Open reduction (with internal fixation and bone graft) of right tibia,

Nonoperative care includes:

-Closed reduction of talar fracture.

T+24hours - 22 days: Patient spends 9 days in intensive care and 13 days in intermediate care. No complications were reported during this patient's acute care hospitalization.

T+ 22 days: Patient discharged from MIEMSS to home unable to ambulate.

COGNITIVE-COMMUNICATIVE ASSESSMENT - CASE 342

The patient's cognititive- communicative skills were initially evaluated on T + 3 days and T + 5 days. The patient was orally intubated on T + 3 days but was able to write legibly. On T + 5 days, he was able to complete the assessment and was found to be exhibiting mild-to-moderate auditory comprehension and cognitive deficits. He appeared to be functioning at an RLAS (Rancho Los Amigos Score) VII level- automatic and appropriate. The patient was recommended to receive therapy for diagnosed deficits. The patient failed a hearing screening test and was nothing by mouth, thus a swallowing test could not be administered.

The patient received treatment for diagnosed deficits. He did not respond well initially and was becoming increasingly confused and disoriented. Treatment goals were revised subsequently. On T + 23 days, the patient received a discharge evaluation. Improvement was noted across all levels assessed. He continued to exhibit difficulties with short-term memory. The patient was subsequently discharged to home and given suggestions to aid his short-term memory skills. The patient was discharged at an RLAS VII/Emerging VIII level (Rancho Los Amigos Score.) The patient was also diagnosed with a moderate high frequency hearing loss and was on a P.O. diet. A follow-up evaluation shoudl be attempted at the 3 month post-discharge time.

18.5 inches to the right of and parallel to the vehicle's left plane. V2's estimated speed change at impact was between 13 and 17 miles per hour. The driver was forced forward and to the left at impact. His head contacted and tore the left sunvisor and then continued into the windshield, cracking the glass, before finally contacting the upper left instrument panel. At the same time, his torso deformed the lower steering rim and broke the armrest on the left door. The turn signal lever was also bent. The driver's head rebounded rearward after impact and contacted the rear window which was not damaged. He reportedly sustained incapacitating injuries.

T + 1.36 seconds: V1 rotated counterclockwise at impact and slid 22.3 feet to final rest. At final rest, V1 was positioned in the northbound travel lane and was headed 11 degrees to the east of due south. All 3 occupants were eventually transported to hospitals for treatment and V1 was towed from the scene with disabling damage.

T + 1.61 seconds: V2 also rotated counterclockwise at impact and slid 22.9 feet to final rest. At final rest, V2 was positioned in the grassy field to the east of the roadway and was headed 74 degrees to the west of due north. The driver (the only occupant) was eventually transported to a hospital for treatment and V2 was towed from the scene with disabling damage.

T + 1 minute: Police were notified of the collision.

T + 4 minutes: Police arrived at the scene.

PREHOSPITAL AND HOSPITAL TIMELINE - CASE 342

T+ 3min: Ambulance receives call to respond.

T+ 6min: Ambulance arrives at scene. Initial field assessment reveals a blood pressure of 90/palp, a heart rate of 90, a respiratory rate of 22, and a Glascow Coma Score of 12. Prehospital care includes fluid resuscitation with the administration of 15000cc of crystalloid, administration of oxygen, application and inflation of the MAST suit, spinal immobilization and monitoring of vitals. The patient required extrication from the vehicle.

T+ 45min: Patient departs scene for MIEMSS/Shock Trauma by police medevac helicopter.

T+ 58min: Patient arrives at MIEMSS. Initial physiologic assessment of the patient reveals a blood pressure of 138/82, a heart rate of 103, a respiratory rate of 29, and a Glascow Coma Score of 14. The patient's ISS (Injury Severity Score) = 22. Toxicology screen results were positive for alcohol.

Initial hospital care provided includes:

-Evaluation by a MIEMSS trauma team,
-Fluid resuscitation,
-Emergent endotracheal intubation,
-Diagnostic peritoneal lavage with slightly positive results
-Full diagnostic evaluation including x-rays of the

windshield which had intruded longitudinally 10.5 inches and was holed from impact forces. His head moved down the windshield leaving deposits of hair and skin embedded in the glass. His face then contacted the lower left steering rim. The rim was turned to the right about 90 degrees due to the driver's steering efforts thereby positioning the bottom of the rim at the left side. The rim was abraded and deposits of blood and other tissue were noted there. The driver sustained closed head trauma, and multiple facial abrasions from the windshield, and a fractured nose from steering rim contact. The left "A" pillar was intruded longitudinally 3.5 inches and the driver's seatback was intruded longitudinally 3.7 inches into the driver's position. The seatback intrusion was caused by impact from the center rear seat passenger. The rear seat passenger's motion increased the severity of forces that were acting on the front seat occupants. This is evidenced by the driver's chest impact to the bottom half of the steering rim/hub which again was turned to the right about 90 degrees. Given the impact forces, the driver's chest should have loaded the entire steering rim/hub. Instead, the driver was forced forward and to the left by the rear seat passenger. The driver sustained multiple right side rib fractures with flail chest and hemothorax. There was also deformation to the top of the steering rim which indicates that the driver's right hand was holding the rim at the 90 degree angle upon impact. Both of the driver's knees impacted the lower left instrument panel as evidenced by broken plastic, and he sustained an associated right tibia fracture. The driver also sustained a fracture and dislocation of the right ankle and there were abrasions noted to the brake pedal. The right front seatback intruded longitudinally 10.3 inches into the right front passenger's position as a result of impact by the center rear seat passenger. The right front passenger's head contacted the right sunvisor and the impact damaged right side of the windshield which had intruded longitudinally 3.5 inches. Long strands of hair were found embedded in the glass. There was deformed plastic and blood, and a broken glove box door at the right instrument panel which indicates contact by the right front passenger's torso and legs. She reportedly sustained incapacitating injuries. As mentioned above, impact by the center rear seat passenger deformed both front seatbacks. The seatbacks were also abraded. This passenger also contacted and broke the center console between the front seats as he was forced forward by impact forces. The rear seat passenger's head contacted, broke, and dislodged the rear view mirror. His head then contacted the impact damaged center windshield which had intruded longitudinally 6.5 inches and was holed from impact by the hood. Hair and blood were embedded in the glass which indicates that his head was already bleeding from contact to the rear view mirror. He reportedly had incapacitating injuries.

Maximum lateral "sheet metal" crush to the left side of V2 was measured to be 14.1 inches, however, this does not account for the deformation to V2's left frame rail which was originally

lap and shoulder belts and there were no restraints available to the center rear seat passenger. The other vehicle in the collision was a 1983 Ford F-250 pickup truck (V2) with one 29 year old male occupant who was not using the available manual lap and shoulder belt. The roadway is a heavily traveled asphalt State Highway which has one 10.8 foot wide northbound lane that is separated from one 11.9 foot wide southbound lane by an intermittent yellow paint line. The roadway is bordered on the west by a 10 foot wide paved asphalt shoulder and on the east by an 8.3 foot wide shoulder of the same construction. The roadway is situated in a grassy rural area and has an estimated coefficient of friction of .75. Its surface is straight and flat in the area of the collision, however, this area is located at the bottom of a gradual dip between 2 hills. The hills crest approximately 500 feet to the north and to the south of the impact point.

V1 (our case vehicle) was southbound at an estimated speed of between 59 and 63 miles per hour. At some point, V1 crossed the centerline of the roadway and continued south on the northbound shoulder. V2 was northbound in the northbound lane at an estimated speed of between 45 and 49 miles per hour. As V1 crossed the roadway to the northbound shoulder, V2 was steered to the right as its driver tried to avoid impact.

T - .56 seconds: The driver of V2 locked the brakes and skidded 35 feet while rotating slightly clockwise. At the end of the skid, V2 was traveling an estimated speed of between 36 and 40 miles per hour and was headed 45 degrees to the east of due north while its center of gravity was traveling 23 degrees to the east of due north (a -22 degree slip angle).

T - .43 seconds: The driver of V1 locked the brakes and skidded 36 feet. He was attempting to steer to the right, but with locked brakes, the vehicle did not respond. At the end of the skid, V1 was traveling an estimated speed of between 52 and 56 miles per hour and was headed due south.

T - 0: The left front bumper corner of V1 contacted V2 at the driver's door, and the front of V1 rode under V2's left side. At maximum engagement, the left front of V1 caused 4.4 inches of lateral crush to V2's left frame rail (from direct contact), and the right front bumper of V1 impacted and dislodged the left rear wheel of V2. This caused a direct contact damage pattern to V1 which began at the right front bumper corner and extended diagonally across the hood to the left "A" pillar. Evidence suggests that V1's hood was pushed rearward and caused 2 holes in the lower central windshield. Since the right side of the bumper was deformed by V2's left rear wheel, and the left side of the front grille was deformed by V2's left frame rail, 2 sets of damage measurements were retrieved in order to describe V1's damage. Maximum longitudinal crush to the right front bumper corner of V1 was measured to be 20.5 inches and the estimated speed change at impact was between 19 and 23 miles per hour.

All 3 of V1's occupants were forced forward at impact. The driver's head contacted the impact damaged left side of the

difficult time processing thoughts although he easily verbalized his feelings.

Prior to injury, the patient had been living with his girlfriend of three years following the separation and divorce from his wife. The couple currently lives in the basement apartment of the home of his girlfriend's mother, which has created some conflict between the two. The patient had been hospitalized at MIEMSS Shock Trauma at T - 15 months for injuries received in a motorcycle injury, from which he had completely recovered. Since that time the patient had worked as a construction and landscape laborer. At T - 6 months, the patient had started his own carpentry business but felt it was unsuccessful, with debts mounting due to increased building permit fees and an inability to sustain costs. The patient had no health insurance coverage; however the vehicle had $10,000 personal injury protection. The patient was advised to apply for medical assistance.

Although the patient has three children (ages 6, 8, 9) by a previous relationship, contact is sporadic and the relationship strained. The patient admits to a chaotic childhood following the mother's death due to alcoholism when he was age 12, his father's remarriage and subsequent divorce and his "adoption" by foster family. He states that he is the oldest of three brothers and two sisters and that he has six foster siblings. The patient's foster mother currently lives out of town and visited the patient once during his acute care hospitalization. The patient's father also resides out of state and he has not been in contact with him for several years. The patient's girlfriend is the primary support figure and although her car was demolished and she has provided financial support, she continues to be willing to help out, being especially relieved that he plans to seek treatment for substance abuse and to join Alcoholics Anonymous. Although he admits to heavy drinking and acknowledges it has been a problem (prior DWI and inpatient hospital/residential treatment) since T- 4 years, he denies any drug abuse or treatment for poly-substance abuse. the patient does state that his siblings have experienced both alcohol and cocaine abuse.

The patient was discharged from MIEMSS Shock Trauma to home on T + 22 days with limited weight bearing and functioning quite independently, although emotionally experiencing some difficulty and would seem to require supervision.

CRASH TIME LINE - CASE 342

T - 2 seconds: This was a 2 vehicle accident which occurred on a clear weekday afternoon. The collision involved a 1987 Nissan Pulsar NX 2 door coupe (V1) with a 32 year old male driver (our case), a 30 year old female right front seat passenger, and a 40 year old male center rear seat passenger. The driver and right front seat passenger were not using the available manual

due south. The right front seat passenger and center rear seat passenger reportedly sustained incapacitating injuries, and the driver (our case), sustained head, lower extremity, and chest injuries up to AIS-5 in severity. All three occupants were transported to hospitals for treatment. A complete list of injuries for this case is included below in OIC format:

BODY CONTACTS AND INJURIES TABLE-CASE 342
32 year old male; Driver; 1987 Nissan Pulsar NX; Frontal impact

OIC/AIS CODE	ICD-9	BODY CONTACTS AND INJURIES	CONTACT POINT
1. 2HWKB2 011101	854.06	Closed Head Injury with loss of consciousness	Windshield
2. 2FUAI1 011101	910.0	Multiple Facial Abrasions	Windshield
3. 2FCFS1 041100	802.0	Nasal Fracture	Steering Rim
4. 2CRFS5 061100	807.4 807.09 860.2	Flail Chest, right side w/ Multiple Rib Fractures and Hemothorax, right side	Steering Rim/Hub
5. 2LRFS2 091100	823.80	Fracture, Right Tibia	Lower Left Instrument Panel
6. 2QRZJ3 591100	824.8 837.0	Fracture, Right Ankle and Dislocation, Right Talus	Brake Pedal
UNKNOWN IF INJURED		Broken Plastic (left knee contact)	Lower Left Instrument Panel

PSYCHOSOCIAL SUMMARY - CASE 342

A 31-year-old divorced male was admitted to MIEMSS Shock Trauma after the car in which he was travelling collided with a pickup truck. The study patient was the driver of the car in which there were two other occupants: a 30-year-old female front-seat passenger and a 32-year-old rear seat passenger, both of whom were evacuated to MIEMSS Shock Trauma as well as the driver of the pickup truck. The former two were discharged at T + 4 days. The study patient had been admitted for multiple head and facial abrasions and lacerations as well as a right foot fracture. The patient had been drinking and open containers of beer and other alcoholic beverages were found in the car.

Throughout his hospitalization, the patient appeared disheveled and was unable to recall any facts related to the collision or where he had been prior to the crash. At T + 20 days, the patient continued to exhibit confusion, agitation and paranoid ideation consistent with head trauma. Although unable to recall past history, patient displayed inappropriate affect thought to be enhanced by sleep deprivation and/or delirium tremens (D.T.'s). The patient was also very emotional, tearful at times, openly frightened and remorseful when police advised him that he had been drinking prior to the crash. He had a

SUMMARY - CASE 342 (023)

This 2 vehicle collision occurred on a clear, summer, weekday afternoon. The collision involved a 1987 Nissan Pulsar NX 2 door coupe with a 32 year old male driver, a 30 year old female right front seat passenger, and a 40 year old male center rear seat passenger. The driver and right front seat passenger were not using the available manual lap and shoulder belts, and there were no restraints available for the center rear seat passenger. The other vehicle in this collision was a 1983 Ford F-250 pickup truck with one 29 year old male occupant who was not using the available manual lap and shoulder belt. The roadway is a heavily traveled asphalt State Highway which has 1 northbound lane that is separated from 1 southbound lane by an intermittent yellow paint line. The roadway is bordered by paved asphalt shoulders and it is situated in a grassy rural area. The estimated coefficient of friction is .75. The Nissan (our case vehicle) was southbound at an estimated speed of between 59 and 63 miles per hour. At some point, the Nissan crossed the centerline of the roadway and continued traveling south on the northbound shoulder. The Ford was northbound in the northbound lane at an estimated speed of between 45 and 49 miles per hour. As the Nissan crossed the roadway to the northbound shoulder, the Ford was steered to the right onto the Northbound shoulder. Both drivers locked the brakes about 35 feet from the point of impact thereby eliminating any further avoidance maneuvers. At impact, the Nissan was facing due south and traveling an estimated speed of between 52 and 56 miles per hour. The Ford was traveling an estimated speed of between 36 and 40 miles per hour and was facing 45 degrees to the east of due north while its center of gravity was traveling 23 degrees to the east of due north (a -22 degree slip angle). The left front bumper corner of the Nissan contacted the Ford at the driver's door, and the front of the Nissan rode under the Ford. At maximum engagement, the left front of the Nissan caused 4.4 inches of lateral crush to the Ford's left frame rail (from direct contact), and the right front bumper of the Nissan impacted and dislodged the left rear wheel of the Ford. This caused a direct contact damage pattern to the Nissan which began at the right front bumper corner and extended diagonally across the hood to the left "A" pillar. Maximum longitudinal crush to the right front bumper corner of the Nissan was measured to be 20.5 inches and the estimated speed change at impact was between 19 and 23 miles per hour. Maximum lateral "sheet metal" crush to the left side of the Ford was measured to be 14.1 inches and estimated speed change at impact was between 13 and 17 miles per hour. Both vehicles rotated counterclockwise at impact and slid approximately 23 feet to final rest. At final rest, the Ford was situated in the grassy field to the east of the roadway and was headed 74 degrees to the west of due north. The driver reportedly sustained incapacitating injuries and was transported to a hospital for treatment. The Nissan was situated in the northbound travel lane and was headed 11 degrees to the east of

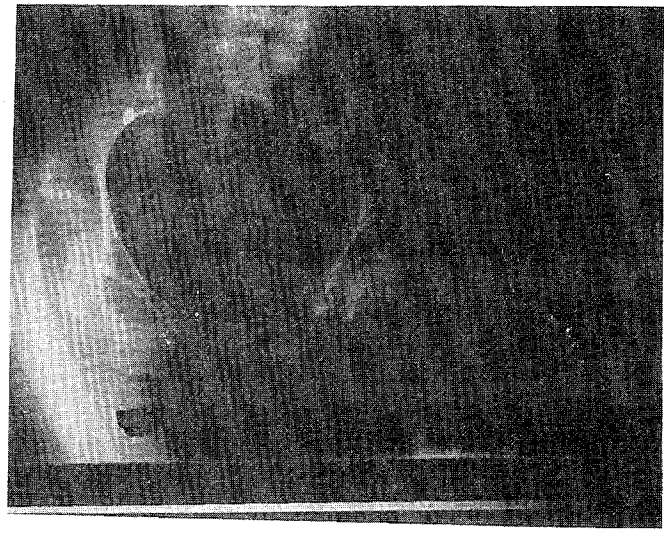

102A Pelvic X-Ray revealing a right posterior hip dislocation.

Contact Point- Impact forces associated with toepan intrusion
Type of Crash- Frontal impact
Estimated Force of Impact- Lower Leg- 1200 lbs.

102B X-Ray revealing a fracture of the right patella.

Contact Point- Lower instrument panel
Type of Crash- Frontal impact

SELECTED PHOTOGRAPHS, CASE 102

3.



V1 - Max Crush to left third of frontal plane with direct and induced damage to entire front plane. Roof removed to aid extrication of the driver.

4.



V1 Interior contact points - Steering wheel rim, "A" pillar, and windshield caused closed head trauma and dislocated right posterior hip (AIS-3) and other less severe injuries to driver.

SELECTED PHOTOGRAPHS, CASE 102

1.

Scene photograph showing approach direction of V1. The bridge abutment (to right of pictured vehicle) on the 2 lane curved roadway was contacted by the frontal plane of Vehicle 1.

2.

V1; (1987 Subaru DL station wagon). Frontal impact. Max Crush = 34.25 inches at left third of frontal plane. Delta V = 30 to 35 m.p.h. Floor/toe pan intrusion = 4.0 inches.

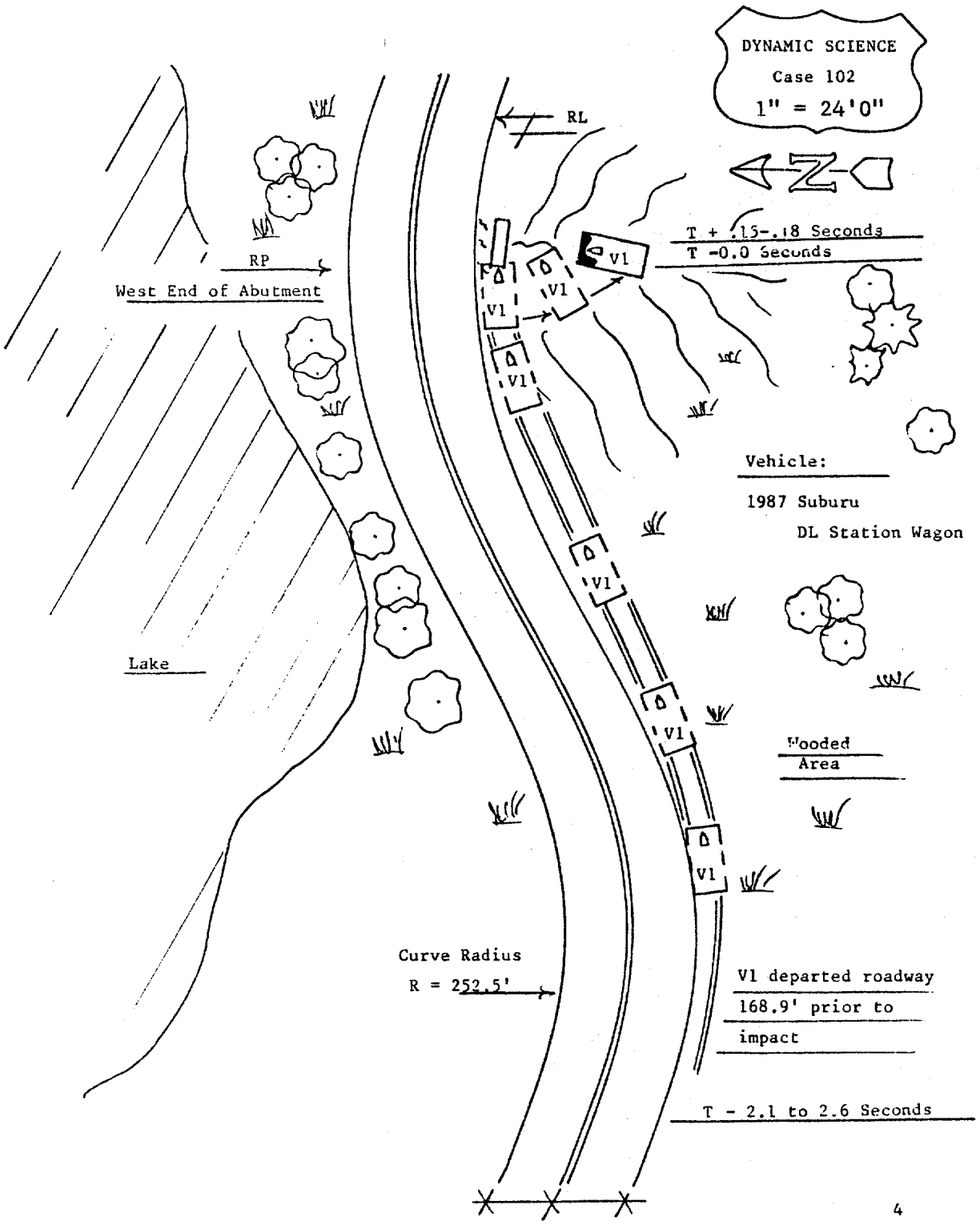
DYNAMIC SCIENCE
Case 102
1" = 24'0"
RL
RP
West End of Abutment
T + .15-.18 Seconds
T -0.0 Seconds
V1
Vehicle:
1987 Suburu
DL Station Wagon
Lake
Wooded
Area
Curve Radius
R = 252.5'
V1 departed roadway
168.9' prior to
impact
T - 2.1 to 2.6 Seconds

4

finances.

1 Year

Patient has not returned to work and is now a housewife full-time with improved family relationships. Husband enrolled in Alanon Group and wife continues AA. Son is doing better now that Mother doing better. Patient continues to experience hip pain and knee pain.

CRASH AND INJURY PREVENTION IDEAS - CASE 102

This accident occurred primarily because of driver inattention. The development of electronic "smart" highways, with the ability to analyze impending dangerous situations, and speed regulators, would greatly enhance the safety aspect of collision avoidance. The ability to overcome human error through the use of electronics will greatly reduce accidents such as this one. The installation of air cushion restraint systems and automatic seat belts also properly worn by the driver would effectively reduce injuries.

The lack of evasive action on the part of the driver suggests that other human factors may have been present.

the injuries in the crash test was the steering wheel. Here again was a similarity with the actual crash as the cause of injury in the case was the steering wheel and/or windshield.

Significance of Crash:

The NASS tells us that 29% of all unrestrained occupants receive AIS >= 1 injuries, while 1% receive injuries >= AIS 3 with 3% of all injuries requiring hospitalization. The percentage of left hand seat occupants who do not use restraints is 36%.
In rural accidents at speeds of 45-50 mph approximately 43 % will involve an injury. 35% of injury crashes involve a collision with a fixed object (rather than another vehicle). Most of these show that no avoidance maneuvers were taken. About 41% of all frontal accidents with a fixed object will cause injuries of AIS >= 1, with 3% AIS >= 3. However, when the intrusion is 2-6 inches into the passenger compartment, 66% of injuries will be greater than AIS 1 with 4% > AIS 3. The steering wheel and the windshield are the primary causal factors in AIS >= 3 injuries (16%).

Accidents on the shoulders of rural roads will result in a 53% chance of fatality with 10% fatalities in crashes with a fixed object. In all, 35% of all front-end collisions with anything are fatal. Fortunately, there were no fatalities in this particular case.

PSYCHOSOCIAL FOLLOW-UP - CASE 102

6 Months

Following 13 days acute care patient discharged to rehabilitation, leaving after 5 days due to lack of insurance coverage; continuing outpatient therapy at home. At 3 months post-trauma, patient weight-bearing and independent in activities of daily living experiencing some difficulty with ambulation. Patient enrolled in substance abuse program at 3 months. Patient compliant with abstinence. Patient had no cognitive deficits.

At 6 months post-injury, patient has decided not to return to full time work in Library Sciences and seek a career change which injury prompted her to do. In spite of several degrees, patient has started to work-part time as a veterinary assistant and plans to return to school for same.

Patient discharged from inpatient substance abuse program at 5 months post-injury and pursuing outpatient therapy. Patient and family report improved relationships and generally better mood although bouts of depression and irritability continue to exist.

Patient has returned to her avocation as an organist for local church. Although income level reduced due to patient's lost wages, family income remains stable with moderate impact on

SELECTED PHOTOGRAPHS, CASE 117

1.

Scene. 6-lane concrete divided State Highway. V1 direction of travel near impact. V2 crossed into V1's path from the left.

2.

V1 (1987 Mazda B2000 Pickup). Front impact. Max crush = 32.9". Delta V = 38-42 m.p.h. Toepan intrusion 17", Inst. panel 15.8".

inflation of the MAST suit, administration of oxygen, spinal immoblization, and monitoring of vitals. The patient required extrication from the vehicle.

T+ 56min: Patient departs scene for MIEMSS/Shock Trauma by police medevac helicopter.

T+ 64min: Patient arrives at MIEMSS. Initial physiologic assessment of the patient reveals a blood pressure of 140/80, a heart rate of 80, a respiratory rate of 20, and a Glascow Coma Score of 15. The patient's ISS (Injury Severity Score) = 17. Toxicology screen results were positive for alcohol. Initial hospital care provided includes:

- -Evaluation by a MIEMSS trauma team,
- -Fluid resuscitation,
- -Diagnostic peritoneal lavage with negative results,
- -Full diagnostic evaluation including x-rays of the cervical spine, chest and pelvis. In addition to the toxicology screen, an arterial blood gas, a CBC (complete blood count), an SMA-6 (routine blood chemistry) and UA (urinalysis) were performed.

Injuries noted include:

- -Closed head trauma with loss of consciousness,
- -Right posterior hip dislocation,
- -Right open patellar fracture,
- -Left Zygomatic arch fracture,
- -Multiple Right sided facial abrasions,
- -Laceration of the right knee.

Operative care included:

- -Drainage of fluid from and reduction of patellar fracture,
- -Open reduction of the left zygomatic fracture.

T+24hours - 12 days: Patient spends 5 days in intensive care and 7 days in intermediate care. No complications were reported during the acute care hospitalization of this patient.

T+ 12 days: Patient discharged from MIEMSS to an inpatient rehabilitation facility

COGNITIVE-COMMUNICATIVE ASSESSMENT - CASE 102

The patient presented at the time of initial assessment with intact auditory comprehension skills, reading and speech production skills. Mild deficits were noted in reading comprehension skills and writing complex directions. The patient's cognitive-communicative skills were characteristic of RLAS (Rancho Los Amigos Score) level VIII-Purposeful/Appropriate. Hearing and swallowing skills were within normal limits.

Based on her performance during the evaluation, the patient's subtle deficits did not require treatment and the patient was discharged from MIEMSS Speech Language Pathology Services.

CRASH TIME LINE - CASE 102

T - 5 Seconds: The vehicle involved in this collision - a 1988 Suburu DL station wagon, was westbound at a speed estimated at 44 - 54 miles per hour. The roadway is a 2 lane asphalt paved rural road in a state park. It is a winding road with multiple "S" turns and grade changes and has an estimated coefficient of friction of .65. The driver of Vehicle 1, a 40 year old female, allowed the vehicle to drift to the right (south) and off the road onto the grass stabilized right of way.

T - 2.1 to 2.6 Seconds (estimated): Vehicle 1 departed the roadway at a point 168.9' from the impact. The path of the vehicle continued away from the road edge and no corrective or evasive action was noted prior to impact.

T - 0.0: Vehicle 1 struck a concrete bridge abutment producing a maximum crush of 34.25" located within the left third of the frontal plane. The direct and induced damage included the entire frontal plane. At impact, the driver, who was not wearing the available lap/shoulder belt, was thrown forward and to the left, striking the windshield and "A" pillar as the vehicle began a counterclockwise rotation. This contact caused a closed head trauma and loss of consciousness for an unspecified period of time, AIS-3. Extensive lower left and right instrument panel deformation and occupant contact points probably produced the dislocated right hip and open fractured patella. Intrusion to the floor, toe pan and instrument panel contributed to the hip and knee injuries. The driver also sustained a fractured right zygomatic arch which probably occurred during the subsequent impact. At this point in the accident sequence, Vehicle 1 was at least 2.0 feet off the road edge. The shoulder has deteriorated to the point that it is 16" lower than the surface of the road.

T + 0.15 to 0.18 Seconds (estimated): Vehicle 1 started a counterclockwise rotating slide at 90 degrees and came to rest facing north at the bottom of a 5.2 foot deep drainage ditch. The sudden stop at the bottom of the ditch combined with the counterclockwise rotation would in all probability have caused the out-of-position driver to strike the steering wheel rim causing the zygomatic fracture.

T + 8:00 Minutes: The police were notified of the accident.

T + 14:00 Minutes: The police arrived and started investigative and medical efforts.

PREHOSPITAL AND HOSPITAL TIMELINE - CASE 102

T+ 9min: Ambulance receives call to respond.

T+ 12min: Ambulance arrives at scene. Initial field assessment reveals a blood pressure of 90/palp, a heart rate of 114, a respiratory rate of 22, and a Glascow Coma Score of 15. Prehospital care includes fluid resuscitation with the administration of 2000cc of crystalloid, application and

ment panel

PSYCHOSOCIAL SUMMARY - CASE 102

The study patient is a 40-year-old married female who was admitted to MIEMSS Shock Trauma afer being involved in a single car collision. The study patient was the driver and sole occupant of the car in which she was travelling.

It is reported that the patient had left home in a rush to attend choir rehearsal where she was an organist. The patient sustained mulitple lower extremity injuries and it is reported that the patient had been drinking prior to the injury.

The patient is an only child of upper middle class parents and has been married for the past ten years. The patient has one child, a son age 6. The patient is an articulate, educated woman, having three Masters degrees and is working sporadically on her Ph.D. in Library Science. She is employed as the assistant director of a large library system. The patient's husband is a professor of law with a history of chronic diseases who has undergone surgery many times. The husband describes self as a "rescuer with a compulsive personality." He describes their marriage as a problematic one, with each partner going their own way, and difficulty coping with the patient's long history of substance abuse (alcohol and prescription drugs) and long history of psychiatric therapy (12 + years). The husband has removed himself from his wife's problems and has not taken an active role in pursuing treatment for her addiction problems. The patient is reported to see a psychiatrist weekly due to depressive episodes but husband states that she continues to exhibit irrational fears and grief over prior losses and depression over non-promotion at work.

A talented woman, the patient denies alcohol and/or drug abuse in the past and feels that her use of anti-depressants and muscle relaxants has been legitimate to help her with her problems. Although some concerns regarding a possible suicidal gesture, a psychiatric consultation has ruled out the same; however, substance abuse treatment has been recommended.

The husband has taken on role of primary caretaker for the son although he states that the son is also under psychiatric care due to his inability to cope with his mother's unpredictability.

At T+ 13 days, the patient was discharged to an in-state rehabilitation facility and was removed by the husband at T+ 18 days due to a lack of coverage for rehabilitation expenses. At T + 30 days, the patient is at home, utilizing a wheelchair and is limited weight bearing, progressing well and quite independent. The patient and husband concurred that substance abuse treatment is indicated and are pursuing the same with a private facility once the patient is ambulatory.

SUMMARY - CASE 102 (022)

This single vehicle accident occurred during the evening hours in the spring. Vehicle 1, a 1988 Suburu DL Station Wagon was being driven eastbound in a rural park area by a 40 year old unbelted female at a speed estimated at 44 - 54 miles per hour. The road is 2 lane asphalt paved, curved, and is 20.5 feet wide. The lanes are separated by two continuous painted yellow lines and the road is bordered on both sides by grass and trees. The driver of Vehicle 1 had allowed the vehicle to drift off the roadway to the south (driver's right) at a point 168.9 feet west of the point of impact with a concrete bridge abutment. The bridge abutment was 16 inches wide by 8.5 feet long and 24 inches high. It is 2.5 feet south of the road edge, and the shoulder has been allowed to drop 16 inches below the level of the roadway. The delta-V was calculated as 33 mph using the Crash PC damage only algorithm. No indications of evasive maneuvers were appraent from the point Vehicle 1 departed the roadway to the point of impact. At impact, the unbelted driver's head struck the windshield and "A" pillar resulting in a closed head injury with loss of consciousness for an unspecified period of time. Intrusion occurred in the floor/ toe pan area, was measured at 4.0 inches and combined with the documented contact points in the lower dash, caused a right open fracture of the patella and dislocated right hip. The driver of Vehicle 1 also sustained a fractured zygomatic arch which is attributed to an occupant contact point on the steering wheel which occurred either during the impact with the bridge or as the vehicle rotated counterclockwise and dropped 5.2 feet to the bottom of the drainage ditch at final rest. The driver was entrapped within the vehicle by sheet metal and plastic from the instrument panel. Extrication was accomplished by cutting off the vehicle's roof. The injuries sustained by the driver are listed below in OIC format:

BODY CONTACTS AND INJURIES TABLE- CASE 102
40 yr. old female; Driver; 1988 Suburu DL Wagon; Frontal Impact

OIC/AIS CODE	ICD-9	BODY CONTACTS AND INJURIES	CONTACT POINT
1. 2HWKB3 141111	854.06	Closed head trauma with location unspecified	Windshield & A pillar
2. 2FLFS2 041111	802.4	Fracture-left zygomatic arch	Steering wheel rim
3. 2PRDJ3 561111	835.02	Dislocated right posterior hip	Impact forces associated w/ toepan intrusion
4. 2KRFS2 091111	822.1	Fractured right patella	Lower instru-ment panel
5. 2KRLS2 091111	891.0	Laceration-right knee	Lower instru-

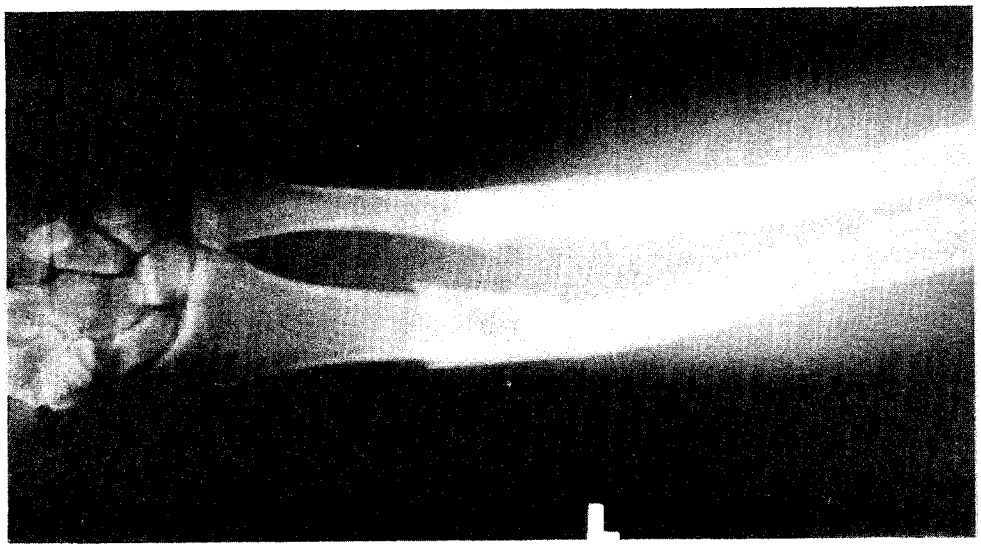

117C X-Ray revealing transverse fractures of the left ulna and radius.

Contact Point- Left instrument panel
Type of Crash- Frontal impact
Estimated Force of Impact- A Pillar- 780 lbs.

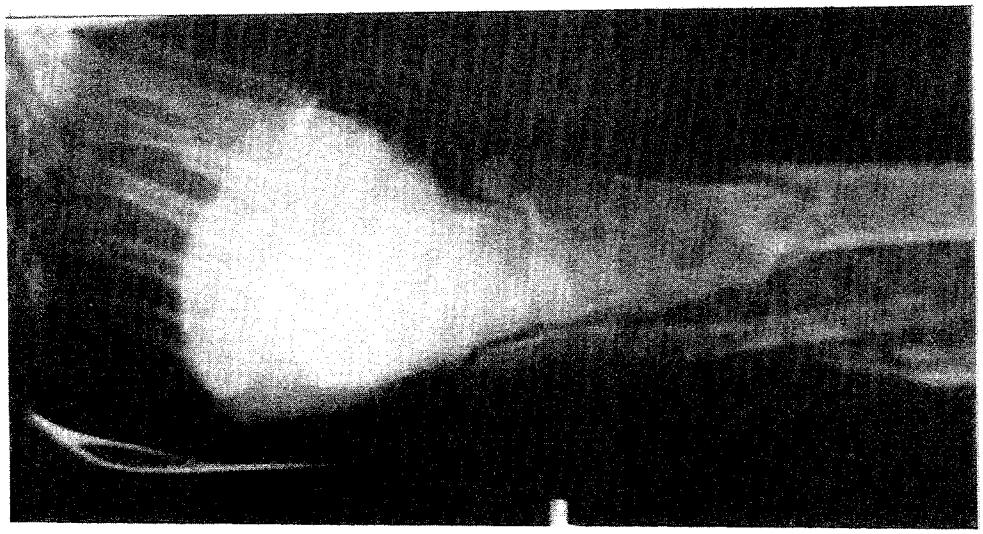

117D X-Ray revealing transverse fractures of left metatarsals numbers 1 through 4 as well distal tibial and fibular fractures.

Contact Point- Left toepan
Type of Crash- Frontal impact
Estimated Force of Impact- A Pillar- 780 lbs.

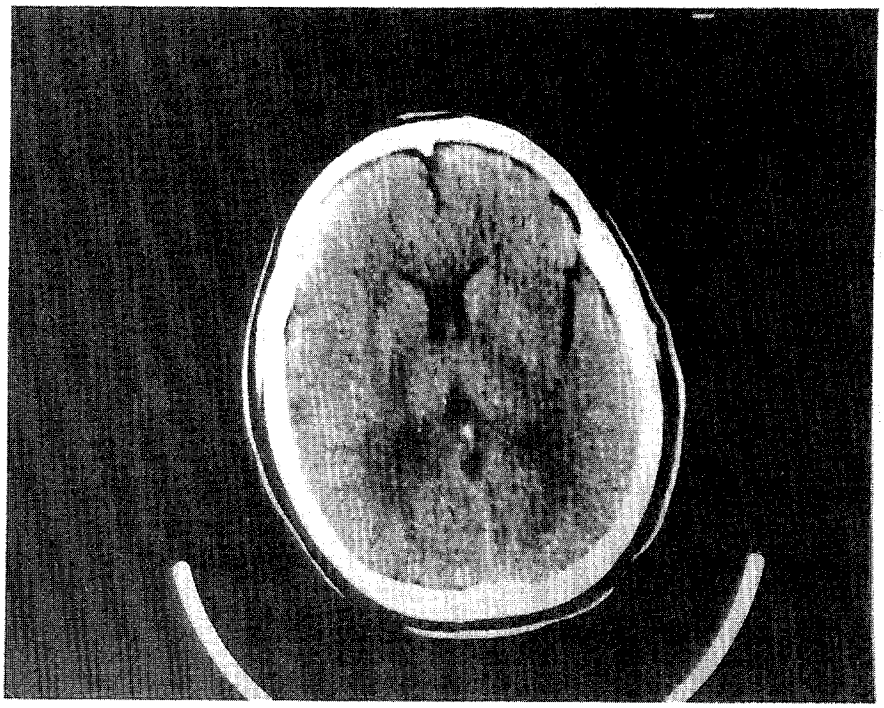

117A CT Scan revealing a right frontal brain contusion and right occipital horn hemorrhage.

Contact Point- Left Window Frame?
Type of Crash- Frontal impact
Estimated Force of Impact- Steering Frame- 660 lbs.

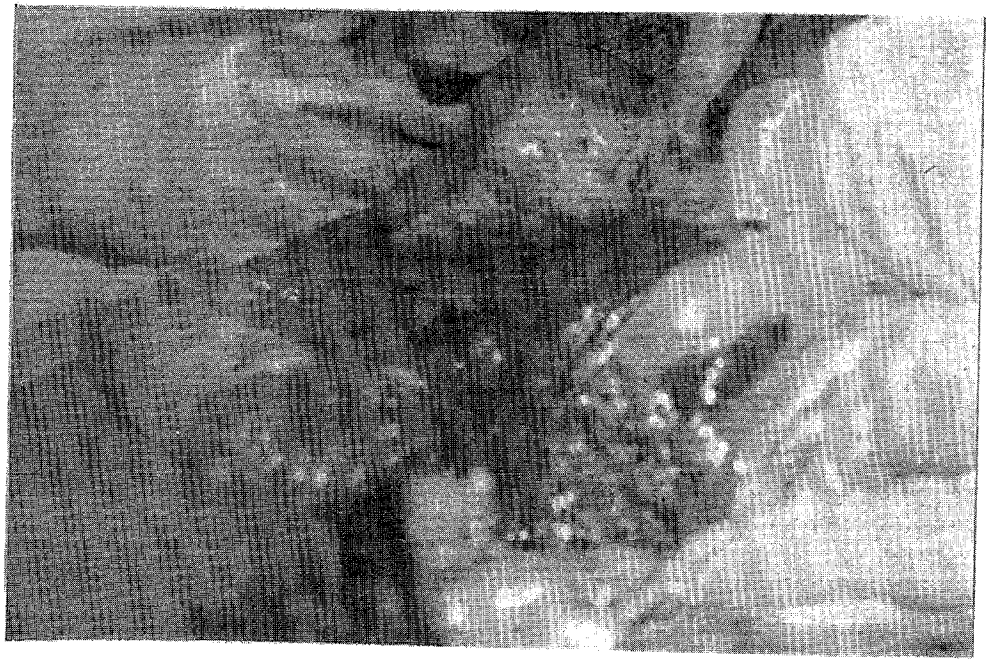

117B Operative photo of small bowel mesenteric tear.
This lesion is associated with use of a lap seat belt.

Contact Point- Seat belt
Type of Crash- Frontal impact
Estimated Impact Force of Lower torso & door- 1470 lbs.

SELECTED PHOTOGRAPHS, CASE 117

3.



V1 window frame (AIS-3,2,&1 head, forearm, face). Toepan (AIS-2 feet). Instrument panel (AIS-2,&1 leg). Lap & shoulder belt used.

4.



V2 (1985 Chevrolet Corvette). Side impact. Crush not measurable. Delta V = 32-35 m.p.h. Lateral floor pan intrusion = 13.5 inches

SELECTED PHOTOGRAPHS, CASE 117

1.

Scene. 6-lane concrete divided State Highway. V1 direction of travel near impact. V2 crossed into V1's path from the left.

2.

V1 (1987 Mazda B2000 Pickup). Front impact. Max crush = 32.9". Delta V = 38-42 m.p.h. Toepan intrusion 17", Inst. panel 15.8".

CASE 117
COLLISION SCHEMATIC

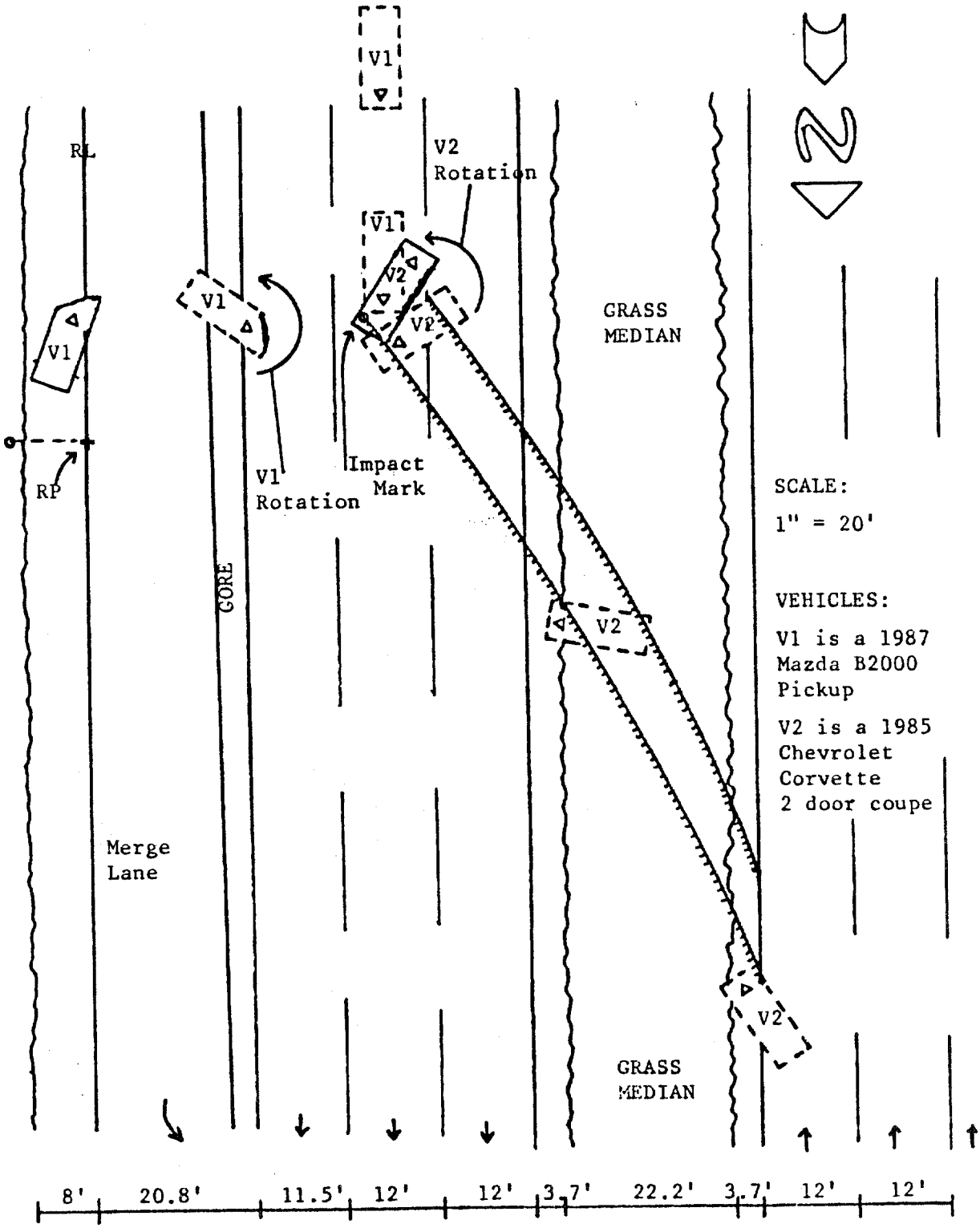

car. Our patient, however, had a negative toxicology screen.

In addition, as also mentioned by crash reconstructionist Jerry Jackson, prevention of the toe pan intrusion would undoubtedly have protected the lower foot by having a stronger support in this area. The possibility of a lateral airbag might have protected to some degree the extremity injuries, especially the upper extremity.

structure would also lessen the occurrence of longitudinal "A" pillar intrusion which has been an instrument of injury in many of our crashes. Our Case was using the available manual lap and shoulder belt, but as in case 251, intrusion moved the injury causing components to within the locked belt's stretch range. This perhaps is another case that would have benefited from a multi-point harness.

----Jerry Jackson

PREVENTION COMMENTS - CASE 117

The patient was a 44 year old male who was driving a Mazda pick-up truck who was struck by a Chevrolet Corvette with two occupants that lost control and crossed the midline striking the patient's car on the left front. The patient was belted, but the left side of the truck was massively injured with marked intrusion into the cabin. The patient sustained direct contact of the head with the left window frame resulting in a contrecoup frontal brain contusion with lacerations on the left side of the face as well as nasal fracture. He also had some significant injury to his left arm with fracture of the radius and ulna and to the left leg with fracture of the tibia and fibula as well as to the metatarsals on the left. The wearing of the seatbelt prevented him from being moved across the car but did result in some mild intra-abdominal tears of the reflection of the sigmoid colon with superficial tears of the spleen. However, these were easily handled and the seatbelt probably prevented further visceral injury since it avoided major contact with the steering rim. This demonstrates some significant preventional components. The first is that if the roadway had a barrier, the car crossing it would not have reached the patient's car. Secondly, there appears to be significant intrusion with poor prevention of cabin intrusion and weakness of the lateral driver's side of the car. Again, the closeness of the patient's head to the left window frame resulted in the brain injury which appears to be the most significant injury the patient sustained with regard to influencing his ability to function and return to work as a biochemist. Also, other injuries of the left arm were sustained by contact with the A-pillar, which could have been better padded and fracture of the tibia and fibula were related to contact with the instrument panel and to the foot with regard to the toe pan. Again in this case, the presence of an airbag probably would have made a major protection with regard to the extremity injuries; probably would not have prevented the head injury but some kind of lateral airbag or marked padding of the window frame areas might have decreased the severity. The seatbelt appears to produce some minor injuries, but probably prevented more significant ones from occurring. The influence of alcohol in this accident has not been ruled out with regard to the other

patient does not feel as close to them and he perceives that friends treat him differently.

Financial strains persist and family has refinanced home. Costs exceed $198,867 with out-of-pocket expenses $39,773.

1 Year

Patient has resumed full-time employment in same job capacity with increased supervision and exhibits less productivity. Physically patient had rod removed from leg causing some pain. Family feels at "chronic stage", and although patient feels well-adjusted, family continues to have difficulty coping with patient's obsessive behaviors. Patient continues to express some language based errors and short-term memory problems but has learned to compensate well. Wife seeing private therapist due to marital problems. Couple has little social life.

PREVENTION AND INJURY REDUCTION - CASE 117

This case like cases 088 and 038 involved a crash on a major divided highway which has no barrier to prevent vehicles from crossing over into opposing traffic. There is no doubt that a continuous Jersey Barrier would have prevented the out of control Corvette from impacting our case vehicle. The State Department of Transportation does not install barriers when there is a wide median.

This crash could probably have been avoided by safer driving practices, however driver error is almost always a factor in car crashes. Considering a Delta V of about 40 m.p.h. in this frontal collision, the case vehicle held up fairly well. There was 11.7 inches of longitudinal left "A" pillar intrusion and our case sustained an AIS-3 head injury. This is a very interesting observation. If you compare this to case 251 which was an 11 O'clock 24 m.p.h. side impact with 12.5 inches of longitudinal "A" pillar intrusion and an AIS-5 head injury, we begin to see the dramatic difference between frontal impacts and "frontal direction" side impacts as they relate to injury severity. Here we have a frontal impact with similar intrusion to that of a side impact at about half the Delta V, yet the low speed side impact produced more severe injury.

Since there was a substantial lateral component to the Delta V for the case vehicle, our case would certainly have benefited from the protection of an armrest mounted Air Bag, a steering hub mounted Air Bag, and/or an "A" pillar mounted Air Bag. In fact, if these devices had deployed and had the toepan area been strong enough to resist damage from the left front wheel, this case may have escaped injury completely. In my experience, toepan intrusion is caused most often by the rearward displacement of the axle/wheel. Strengthening the entire dashpanel (firewall)

probably falls within the 50th percentile of accidents that occur. As for injury severity, about 45% of all light truck accidents are going to result in an injury of AIS 1 or greater and about 3% will involve an AIS of 3 or greater. Further, the steering wheel and interior portion of the car (or truck) are the most common source of injury cause (34%), especially of severity AIS >= 3. As a percentage of all accidents that occur that involve hospitalization to an occupant, light truck accidents account for 2%. That involves about 52 thousand people per year.

Overall, it can be said that this was a common and very costly type of accident.

PSYCHOSOCIAL FOLLOW-UP - CASE 117

6 Months

Following 36 days acute care, patient discharged to out-of-state rehabilitation facility, dependent in activities of daily living and exhibiting memory deficits and inconsistent and inappropriate behavior. Patient remained at rehabilitation center for 73 days, discharged to local outpatient day program emphasizing language and vocational goals. Patient remained at program 48 days leaving due to expiration of insurance coupled with attaining maximum level of functioning at center. Patient and family continue psychotherapy two times monthly to discuss role changes, control issues and family functioning.

At 3 months post-trauma, at home with outpatient therapy and not as highly motivated, expressing frustration, boredom, irritability and inability to keep himself occupied. Memory and concentration continue to be a problem in spite of high scores, re: academic recall. Physically, patient independent in all activities of daily living with minimum residual effects. Patient downplays judgment ability and family reports he makes excuses for self, typical of brain injury recovery. Family relationships more aloof and distant, personality traits exaggerated including irritability, and affect somewhat flat.

Although patient's salary continued, expenses exhausted savings and family in process of refinancing home. Costs exceed $170,000.

At 6 months post-trauma, patient remains at home, having returned to work one day a week to begin to get more comfortable with environment with anticipated full-time return to work at 7-8 months post trauma. Although patient is confident of abilities to pursue research, he has not been put to the test. Employer willing to provide support and supervision initially.

Patient's affect becoming more appropriate, and although patient has some minor evidence of speech hesitancies, he compensates well. Emotionally, he continues to feel "parented" and resents frequent criticism by family. He feels he has developed a different personality but is pleased with same. Children are functioning better with less acting out although

Comparison of Crash Pulse Curves:

The curves obtained for the crash pulse determination are at Figures 117-6 through 117-9. The actual pulse used for the simulation was derived from these curves by the simulation engineer for GESAC and turned out to be 14 G's for 200 milliseconds when filtered.

Crash Test Injuries:

The impulse curves for the driver occupant dummies in the crash test are at Figures 117-10 and Figure 117-11. In this set of cases the data for the head center of gravity, x-axis was used. One of the cases in the test data base had no relevant occupant data so only three were used for comparison.

In case 845, the vehicle 1 driver suffered an HIC of 439 and a CSI of 287 while the driver occupant of vehicle 2 suffered an HIC of 420 and a CSI of 287. In both cases (Vehicles 1 and 2) the dummy struck the steering wheel of the vehicle as the first impact. In case 860, the driver occupant of vehicle 1 suffered an HIC of 302 and a CSI of 142, while the driver occupant of vehicle number 2 suffered an HIC of 614 and a CSI of 376. Again, the culprit in the injury was the steering wheel.

The driver of the case vehicle (Case 117) sustained AIS 3 severity multiple injuries to the head and abdomen. The most severe of the injuries in the actual case, however, seemed to be attributable to the intrusion of the "A" pillar, toe pan and instrument panel. Some abrasions were attributed to the steering wheel and this is entirely consistent with the CSI results in the crash tests.

Significance of this Case:

The FARS indicates that some 3700 fatal accidents involving two vehicles will occur in a year that involve a light truck and a car and that this is the second most frequent type of fatal accident to occur. About 20% of all fatal accidents (12,000) involve a light truck and this type of accident is the second most likely to be fatal in all road categories, Interstate to local. Of the various types of light trucks, pickup trucks have by far the highest incidence of fatalities (75%), and they represent about 13% of all vehicle occupant fatalities. The fact that there were no fatalities in this accident was very fortunate.

As for the NASS, the conditions of the accident as far as road type, time of day, weather conditions, visibility and impact are all among the most common categories of accident. In fact it

860	1	Honda	Accord	2789	-----	59.30	VTV	0
	2	Honda	Accord	2855	-----	59.30	VTV	0

So as to further determine the usefulness of these cases, it was necessary to see how close they come to the actual crash when compared as to the pattern shown in the actual damage profiles. Table 117-3 shows the crash test profiles and Table 117-4 shows the overall damage comparisons.

Table 117-3
Damage Profile Comparisons

TEST	V#	MAKE	MODEL	CRUSH POINT 1	CRUSH POINT 2	CRUSH POINT 3	CRUSH POINT 4	CRUSH POINT 5	CRUSH POINT 6
845	1	Dodge	Omni	34.00	29.00	22.90	15.50	6.80	1.20
845	2	Dodge	Omni	30.50	25.30	19.80	13.50	5.30	1.80
860	1	Honda	Accord	32.00	27.20	23.10	14.50	5.20	-7.40
860	2	Honda	Accord	31.50	24.50	21.90	16.80	6.00	-6.00

Table 117-4
Overall Damage Comparisons

TEST	V#	VDI	PDOF	LENCNT	DAMST	CRHDST
845	1	12FYEN4	0	32.80	-16.40	34.00
845	2	12FYEN3	0	32.80	-16.40	30.50
860	1	12FYEN3	0	30.30	15.10	32.00
860	2	12FYEN3	0	30.30	15.10	31.50

These tests all have the same or very close Vehicle Damage Index (VDI) and two each have similar Lengths of Identation (LENCNT). Moreover, the maximum crush in all of them come close to the actual accident (32.9) and the across the board damage profiles are similar to, though somewhat less than, the actual accident. The actual accident had a crush profile of:

The resulting cases appeared useable based on comparison of the crush profile. These are summarized in Table 117-5, below.

Table 117-5
Crush Comparison

The Actual Accident	33	22	21	17	5	1 (inches)
The Test Cases	31	25	20	14	5	2 (inches)

BIODYNAMICS STUDY
CRASH COMPARISON, Case 117

Preliminary Search Data:

An initial search of the NHTSA data base on vehicle make, model, year, angle of impact and speed found only three cases and none of these were good matches for the actual crash. The characteristics were totally different. Basically the speed and crush characteristics varied from the actual crash. The simulation team engineer was then contacted for a discussion of just how the search parameters should be broadened.

A subsequent search of the NHTSA vehicle database was made, using the vehicle weight and closing speed in vehicle to vehicle accidents as search fields without regard to angle of impact (i.e. VEHTWT = 2200 - 3200, TSTCFN = "VTV" and CLSSPD = 40) yielded 70 cases. At this point the actual PDOF of the accident in Case 117 was evaluated and found to be 310 degrees. An attempt to further narrow the range of crash test choices was made by using an angle of impact range of 300-330 (=/- 15 degrees) and 6 tests were isolated but their speeds were far too low (< 40 MPH).
We then went back to the second list of 70 cases. A careful review of the second group of 70 cases with the GESAC simulation engineer narrowed the search down to two cases involving vehicle to vehicle crashes which, in the opinion of the simulation engineer seemed to be best for use based on a comparison of the crush characteristics. These cases are shown in Table 117-1.

Table 117-1
Cases with Close Crush Profiles

MAK	MOD	BOD	T#	YR	WT.	LENGTH	WIDTH	COG	WBASE	SPEED	V	CRUSH
07	09	5H	845	83	2828	163.70	65.60	59.90	99.00	0.00	1	15.50
07	09	5H	845	83	2861	164.10	66.30	59.90	99.00	59.90	2	27.00
23	02	4S	860	84	2789	175.60	65.50	59.30	96.50	0.00	1	18.40
23	02	4S	860	84	2855	175.80	65.50	59.30	96.50	59.30	2	17.00

Table 117-2, below, Shows a summary of the test case characteristics.

Table 117-2
Summary of Retrieval

TEST	V#	MAKE	MODEL	WEIGHT	SPEED	CLOSE SPEED	TEST CONFIG	IMPACT ANGLE
845	1	Dodge	Omni	2828	-----	59.90	VTV	0
	2	Dodge	Omni	2861	-----	59.90	VTV	0

-Open reduction of left ulna fracture with internal fixation,
-Open reduction of left tibia fracture with intramedullary rodding,
-Open reduction of left metatarsal bone fractures,
-Resection and anastomosis of small bowel,
-Resection of small bowel mesentery,
-Repair of spleen injury.

T+ 24hours - 32 days: Patient spends 22 days in critical care and 10 days in intermediate care. Complications developed during the acute care phase of this patient include: sepsis and pneumonia.

T+ 32 days: Patient discharged from MIEMSS to an inpatient rehabilitation facility.

COGNITIVE-COMMUNICATIVE ASSESSMENT - CASE 117

The patient was initially evaluated on T + 18 days. The patient was endotracheally intubated and inconsistently following commands at this time. The majority of the battery could not be completed. The patient's cognitive- communicative skills were characteristic of an RLAS III (Rancho Los Amigos Scale)- Agitated/Confused Response. The patient was unable to respond to a pure tone hearing screening. The patient was also NPO (not permitted to ingest anthing orally) due to the intubation. Monitoring and treatment were recommended as the patient's medical status improved.

By the date of discharge, T + 32 days, the patient's cognitive-communicative skills were characteristic of RLAS V- Confused/ Inappropriate Response. The patient was able to comprehend some two step commands and to answer questions relating to a short story. He spoke in short sentences and was able to name some objects, but had significant word finding deficits. The patient was unable to read and comprehend words. He was able to write one word to name an object, but was unable to write other words in phrases. The patient had significant concentration, reasoning, and short-term memory deficits. The patient was able to respond to a hearing screening, however, he failed. Audiology diagnosed a bilateral mild-moderate hearing loss. The patient's swallowing functions were evaluated on T + 18 days. Therapeutic feeding was recommended. At discharge, the patient was recommended to receive a soft diet with regular liquids. Treatment for cognitive- communicative deficits was recommended while in rehabilitation.

T+ 14min: Ambulance arrives at scene. Initial field assessment reveals a blood pressure of 120/70, a heart rate of 76, a respiratory rate of and a Glasgow Coma Score of 7. Prehospital care includes fluid resuscitation with the administration of 2000cc of crystalloid, application and inflation of the MAST suit, spinal immobilization, application of restraints, splinting of extremity fractures, administration of oxygen, airway maintenance and monitoring of vitals. The patient required extensive extrication from the vehicle.

T+ 50min: Patient departs scene for MIEMSS/Shock Trauma by ground ambulance.

T+ 73min: Patient arrives at MIEMSS. Initial physiologic assessment of the patient reveals a blood pressure of 90/60, a heart rate of 104, a respiratory rate of 12, and a Glasgow Coma Score of 12. The patient's ISS (Injury Severity Score) = 27. Toxicology screen results were negative. Initial hospital care provided includes:

- -Evaluation by a MIEMSS trauma team,
- -Fluid resuscitation,
- -Diagnostic peritoneal lavage with positive results,
- -Full diagnostic evaluation including x-rays of the cervical spine, chest and pelvis. In addition to the toxicology screen, an arterial blood gas, a CBC (complete blood count), an SMA-6 (routine blood chemistry) and UA (urinalysis) were performed. The patient also underwent a Head CT Scan.

Injuries noted include:

- -Right Frontal Brain Contusion,
- -Small Right Occipital Horn Hemorrhage,
- -Left Forehead Laceration,
- -Left Eye Traumatic Mydriasis and Scleral Abrasion,
- -Closed Nasal Fracture with Hemorrhage into Ethmoid and Sphenoid Sinuses,
- -Left Chin Laceration,
- -Chest Abrasions,
- -Mesenteric Tears- Small Bowel,
- -Superficial Splenic Tears,
- -Laceration to the Left and Right Elbows,
- -Left Radius Fracture (Middle 1/3, Comminuted, Grade I),
- -Left Ulna Fracture (Middle 1/3, Transverse, Grade I),
- -Right Knee Laceration,
- -Left Tibia Fracture (Lower 1/3, Transverse),
- -Left Fibula Fracture (Lower 1/3, Transverse),
- -Right Talar Fracture (Proximal Articular Surface, Oblique),
- -Left First Metatarsal Fracture (Lower 1/3, Trasverse),
- -Left Second Metatarsal Fracture (Lower 1/3, Transverse),
- -Left Third Metatarsal Fracture (Lower 1/3, Transverse),
- -Left Fourth Metatarsal Fracture (Lower 1/3, Transverse)

Operative care includes:

- -Open reduction of left radius fracture with internal fixation,

sustained abrasions to the abdomen, mesenteric tears, and a tear in the peritoneal reflection of the sigmoid colon as a result of seatbelt loading. The driver's window control handle was broken from thigh contact, however, no resulting injuries were noted. He sustained a small right occipital horn hemorrhage which was possibly caused by contact to the rear window. This window was missing from the vehicle upon inspection and appeared to have been dislodged by vehicle damage rather than by occupant contact or rescue personnel. The driver also sustained a right frontal brain contusion, a laceration to the left forehead, a traumatic mydriasis of the left eye, a nasal fracture with blood in the ethmiod and sphenoid sinuses, and a laceration of the left chin. It is probable, given the directional forces involved, that these injuries occurred as a result of head contact to the same window frame that caused the left radius/ulna fractures, however, no definite residual evidence was noted.

At impact, the right upper "A" pillar of V2 intruded longitudinally 1 inch and laterally 1.4 inches. The right side floor pan intruded laterally 13.5 inches. The floor pan intrusion also decribes lower "A" pillar movement. No contact points were found from the driver of V2, however, there were abrasions to the right door from the torso of the right front passenger as he was forced to the right. There were also abrasions to the right "B" pillar from the passenger's head contact, and abrasions to the right instrument panel as a result of his knee contact.

Both vehicles rotated counterclockwise after impact, however, V2 rotated faster which caused the right side of V2 to subsequently impact the left side of V1. Wheel gouges from V1's left rear were noted just rearward of V2's right rear wheel. After impact, V1 was deflected approximately 76 degrees to the east of its northbound pre-impact direction of travel, and slid approximately 43 feet while rotating counterclockwise. V2 was deflected approximately 15 degrees to the south of its southeastbound pre-impact direction of travel, and slid approximately 6 feet while spinning counterclockwise. T + 1.47 seconds: V1 came to rest on the northbound shoulder and was facing south after rotating approximately 160 degrees from the point of impact. The driver of V1 was eventually transported to a hospital for treatment. V2 came to rest facing south after rotating approximately 206 degrees from the point of impact. Both the driver and passenger in V2 reportedly sustained incapacitating injuries and were eventually transported to a hospital for treatment. Both vehicles were towed from the scene with disabling damage, however, damage measurements could not be retrieved from V2 due to its fiberglass construction.

T + 3 minutes: Police were notified of the collision.

T + 5 minutes: Police arrived at the scene.

PREHOSPITAL AND HOSPITAL TIMELINE - CASE 117

T+ 4min: Ambulance receives call to respond.

minimum speed of 68 miles per hour and began rotating counterclockwise. This was possibly due to an abrupt high speed lane change. V1 was northbound in the middle northbound lane and the driver of V1 could clearly see that V2 was out of control. The driver of V1 was using the available manual lap and shoulder belt. Both occupants of V2 were also using the available manual lap and shoulder belts.

T - 1.04 seconds: As V2's counterclockwise yaw increased, it departed the southbound lanes to the southeast, crossed the 22 foot wide grass median, and entered the northbound lanes in a full broadside slide. By this time, the driver of V1 had applied brakes and V1 was traveling due north at an estimated speed of between 38 and 42 miles per hour just prior to impact. V2 was traveling southeast at an estimated speed of between 54 and 58 miles per hour and had a heading angle of approximately 59 degrees to the east of due north just prior to impact.

T - 0: V1's entire front bumper impacted the right side of V2 just rearward of the right front bumper corner and extending rearward past the right "A" pillar. Maximum longitudinal crush to the left front bumper corner of V1 was measured to be 32.9 inches and speed change at impact was estimated at between 38 and 42 miles per hour. The driver's toepan intruded longitudinally 17 inches and V1's driver sustained associated fractures of the left first through fourth metatarsals and right talus. The left instrument panel intruded longitudinally 15.8 inches and broken plastic with blood deposits were noted on the panel just below and to the right of the steering column. The driver sustained a laceration to the right knee from contact to this area. There was abraded and broken plastic and a fabric transfer on the lower far left instrument panel with associated left tibia/fibula fractures to the driver. The steering column intruded longitudinally 12 inches and there were tissue deposits on the deformed rim. The tissue was primarily dripped blood from after the impact, and the deformation suggests that the driver's chest loaded the steering wheel during impact. The driver sustained chest abrasions as a result, however, some of these abrasions may have been caused by the shoulder belt. The left "A" pillar intruded longitudinally 11.7 inches and laterally 3.3 inches. Evidence suggests that the driver lifted his left arm in order to cover his face or to brace himself just prior to impact. His left hand contacted the left "A" pillar while his left elbow contacted the exterior side mirror. Due to damage, the left window frame was positioned between the mirror and pillar, and as the driver was forced forward and left at impact, the window frame fractured his left radius and ulna. The side mirror lacerated his left elbow at the same instant. The driver's right hand was forced from the steering wheel and he sustained a laceration to the right elbow as his arm broke the windshield wiper control lever. Arm hair was noted in this area. The driver's door panel and armrest were deformed and abraded, and the driver sustained associated superficial tears in the spleen. The lap portion of the driver's seatbelt was noted to have stretched webbing. The driver

etc. The 19-year-old daughter was working full-time and appeared to have a close-knit support group and boyfriend, coping well and assisting mother in a more mature manner.

The support group for the family is small, although friends and neighbors are available. Wife has few relatives, having lost her own father at age 12 and mother 5 years ago. Her only sibling, a brother, was killed in an MVA at age 27, some 10 years ago. No other family is available and the wife is having a hard time meeting the children's needs due to her own difficulty managaing. Psychosocial intervention is being provided.

The wife states that the patient is a non-smoker, drinking alcohol 1-2 times weekly, with no past history of drug use and is quite health conscious.

At T + 25 days, the patient is awake and exhibiting behavioral changes and emotional liability and the expression of inappropriate sexual and social behavior. Although consistent with the healing process of the injured brain, this is nonetheless disturbing to the family. He is beginning to be somewhat aware of errors he is making and some memory deficits, describing himself as feeling "upside-down", an accurate description of what's going on. Although starting to eat and swallow better, he continues to receive tube feedings. He also expresses language-based errors, e.g. "apple-turkey" etc., again consistent with frontal lobe injury. The degree of long-term memory deficits and his potential ability to put information (e.g. knowledge of chemistry) in order remains unknown.

CRASH TIMELINE - CASE 117

T - 2 seconds: This was a 2 vehicle accident which occurred on a clear weekday afternoon. The accident involved a 1987 Mazda B2000 pickup truck (V1) with one 44 year old male occupant (our case), and a 1985 Chevrolet Corvette 2 door coupe (V2) with a 27 year old male driver and a 28 year old male right front passenger. The roadway is a major concrete U.S. Highway which has 3 southbound lanes each approximately 12 feet in width that are separated from 3 northbound lanes by a 22 foot wide grass median which is bordered by 3.7 foot wide paved asphalt shoulders. The northbound lanes are each approximately 12 feet in width and are bordered on the east by a tapered gore area and merge lane, which together, are 20.8 feet wide. The extreme outside (east and west) borders of the highway are 8 foot wide paved asphalt shoulders. The outside shoulders, the gore area, and the merge lane are separated from the travel lanes by solid white paint lines. The travel lanes are separated from each other by intermittent white paint lines, and the inside shoulders are separated from the travel lanes by solid yellow paint lines. The roadway is straight and level and at the time of the collision it was dry and had an estimated coefficient of friction of .8 as measured by an electronic drag sled.

V2 was southbound in the southbound lanes at an estimated

21.	2QLFS2 561101	825.25	Fracture, Left Third Metatarsal	Left Toepan
22.	2QLFS2 561101	825.25	Fracture, Left Fourth Metatarsal	Left Toepan
	UNKNOWN IF INJURED		Broken Plastic (left thigh contact)	Left Window Control Handle

PSYCHOSOCIAL SUMMARY - CASE 117

The patient is a 44-year-old married male who was the driver and single occupant of a light pickup truck, driving home from work on a major roadway when a sports car crossed the center median and collided with the subject case vehicle. The license plate on the sports car alluded to "speed". The subject patient sustained multiple lacerations, head trauma and extremity fractures.

The patient is the youngest of 2 brothers and both his mother and brother reside out-of-town. His father is deceased. The patient has been married for 20 years and has three children, ages 13, 17 and 19. His wife works full-time as a nurse on the evening shift at a county hospital. The patient has been employed for the past 20 years as a civilian chemist with the government, and is currently working on a Master's degree in Biochemistry. The patient's wife carried private health insurance coverage through her work and is uncertain of the disability benefits the patient may be eligible for through the government.

The patient's wife describes her husband as athletic, a jogger, and as the "most easy going person" she knows. Although he finds it difficult to verbalize his feelings and tends to keep to himself, he is happy and satisfied with life.

The wife and children are having great difficulty coping with this trauma and their anger toward the other driver, feeling that it was so "unfair" as the patient had never had an accident and was compulsive about wearing seatbelts and emphasized safe driving. The patient's 17-year-old son, a junior in high school refuses to return to school, and finish the year and has exhibited acting-out, destructive behavior. He is also demonstrating "role-confusion" e.g. wanting to assume responsibility for family and be the "father" and yet unable to find a safe outlet for his anger. The 13-year-old daughter is also exhibiting increased withdrawal and is unable to cry and verbalize feelings. This daughter was especially close to the father, as he always fixed the dinner and "raised" child while mother worked evenings. She refused to come to the hospital until her father knew her. The siblings continue to be confused by their father's inconsistent behavior often personalizing his actions e.g. if he called one child by the other's name, feelings of jealousy occurred, the one thinking Dad liked her better ,

2.	2HPUB3	603100	851.4	Small Right Occipital Horn Hemorrhage	Rear Window??
3.	2FSLI1	252100	873.42	Laceration, Left Forehead	Left Window Frame?
			379.43	Traumatic Mydriasis, Left Eye	Left Window Frame?
4.	2FCFS1	252100	802.0	Nasal Fracture With Blood in Ethmoid and Sphenoid Sinuses	Left Window Frame?
5.	2FILI1	252100	873.44	Laceration, Left Chin	Left Window Frame?
6.	2CUAI1	061103	911.0	Abrasions, Chest	Steering Rim/ Hub
7.	2MUAI1	411100	911.0	Abrasions, Abdomen	Seat Belt
8.	2MILD2	411100	863.20	Mesenteric Tears, Small Bowel	Seat Belt
9.	2MILD3	411100	863.44	Tear of Peritoneal Reflection, Sigmoid Colon	Seat Belt
10.	2MLLQ2	201100	865.02	Superficial Tears, Spleen	Door Panel Left
11.	2ELLI1	661100	881.01	Laceration, Left Elbow	Exterior Left Side Mirror
12.	2ERLI1	071103	881.01	Laceration, Right Elbow	Wiper Control Lever
13.	2RLFS2	261104	813.83	Fracture, Left Radius	Left A Pillar Window Frame/ Side Mirror
14.	2RLFS2	261104	813.83	Fracture, Left Ulna	Left A Pillar Window Frame/Side Mirror
15.	2KRLI1	091102	891.0	Laceration, Right Knee	Instrument Panel, Left
16.	2LLFS2	091102	823.82	Fracture, Left Tibia	Instrument Panel, Left
17.	2LLFS2	091102	823.82	Fracture, Left Fibula	Instrument Panel, Left
18.	2QRFS2	561101	825.21	Fracture, Right Talus	Left Toepan
19.	2QLFS2	561101	825.25	Fracture, Left First Metatarsal	Left Toepan
20.	2QLFS2	561101	825.25	Fracture, Left Second Metatarsal	Left Toepan

SUMMARY - CASE 117 (021)

This 2 vehicle accident occurred on a clear, spring, weekday afternoon. The accident involved a 1987 Mazda B2000 pickup truck with one 44 year old male occupant (our case), and a 1985 Chevrolet Corvette 2 door coupe with a 27 year old male driver and a 28 year old male right front passenger. The roadway is a major concrete U.S. Highway which has 3 southbound lanes that are separated from 3 northbound lanes by a 22 foot wide grass median. The estimated coefficient of friction is .8 as measured by an electronic drag sled. The Mazda was northbound in the middle northbound lane. The Chevrolet was southbound in the southbound lanes at a minimum speed of approximately 68 miles per hour and began rotating counterclockwise. This was possibly due to an abrupt high speed lane change. As the Chevrolet's counterclockwise yaw increased, it departed the southbound lanes to the southeast, crossed the 22 foot wide grass median, and entered the northbound lanes in a full broadside slide. By this time, the driver of the Mazda had applied brakes and the Mazda was traveling due north at an estimated speed of between 38 and 42 miles per hour just prior to impact. The Chevrolet was traveling southeast at an estimated speed of between 54 and 58 miles per hour and had a heading angle of approximately 59 degrees to the east of due north just prior to impact. The Mazda's entire front bumper impacted the Chevrolet's right side just rearward of the right front bumper corner and extending rearward past the right "A" pillar. Maximum logitudinal crush to the left front bumper corner of the Mazda was measured to be 32.9 inches and speed change at impact was estimated at between 38 and 42 miles per hour. The Mazda was deflected to the east at impact and came to rest on the northbound shoulder facing south after traveling approximately 43 feet and rotating counterclockwise approximately 160 degrees after impact. The Chevrolet came to rest facing south approximately 6 feet to the southeast of the impact point following approximately 206 degrees of after-impact rotation. The driver and right front passenger of the Chevrolet reportedly sustained incapacitating injuries and were transported to a hospital for treatment. Both occupants were wearing the available manual lap and shoulder belts. Damage measurements could not be retrieved from the Chevrolet due to its fiberglass construction. The driver of the Mazda (our case) sustained several extremity fractures and lacerations as well as closed head trauma and abdominal injuries up to AIS-3 in severity. He was using the available manual lap and shoulder belt and was transported to a hospital for treatment. A complete list of injuries for this case is included below in OIC format:

BODY CONTACTS AND INJURIES TABLE-CASE 117

44 year old male; Driver; 1987 Mazda pickup; Frontal impact

OIC/AIS CODE	ICD-9	BODY CONTACTS AND INJURIES	CONTACT POINT
1. 2HACB3 252100	851.0	Right Frontal Brain Contusion	Left Window Frame?

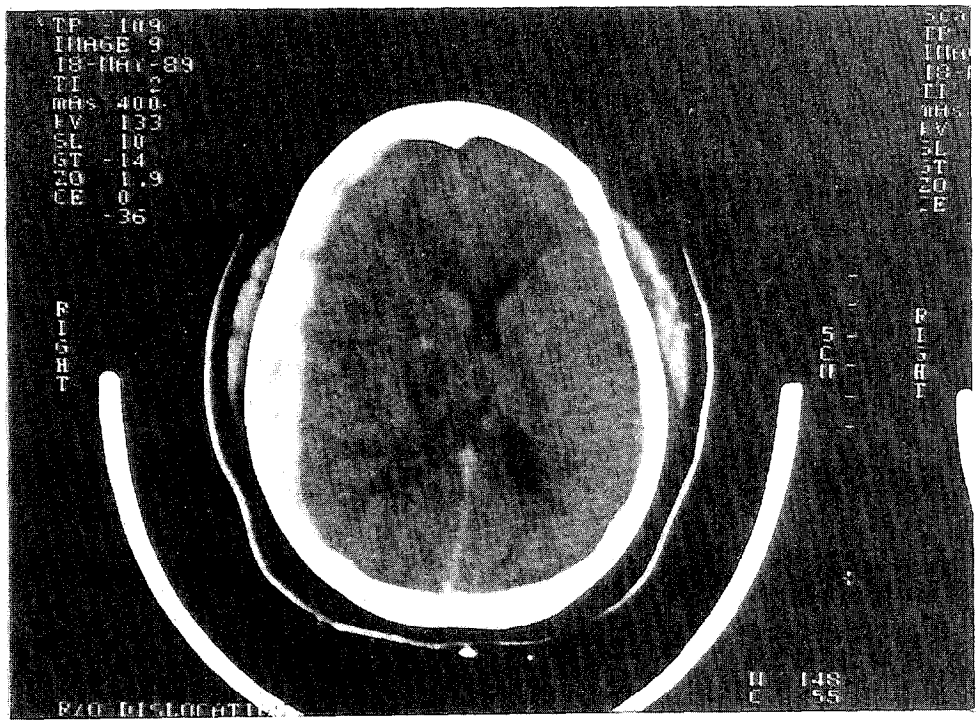

004C Head CT Scan revealing a complex right-sided subdural hematoma with ipsilateral compression of the ventricle and shift of the brain tissue from right to left across the midline.

Contact Point- Exterior undercarriage of other vehicle
Type of Crash- Frontal- left side impact

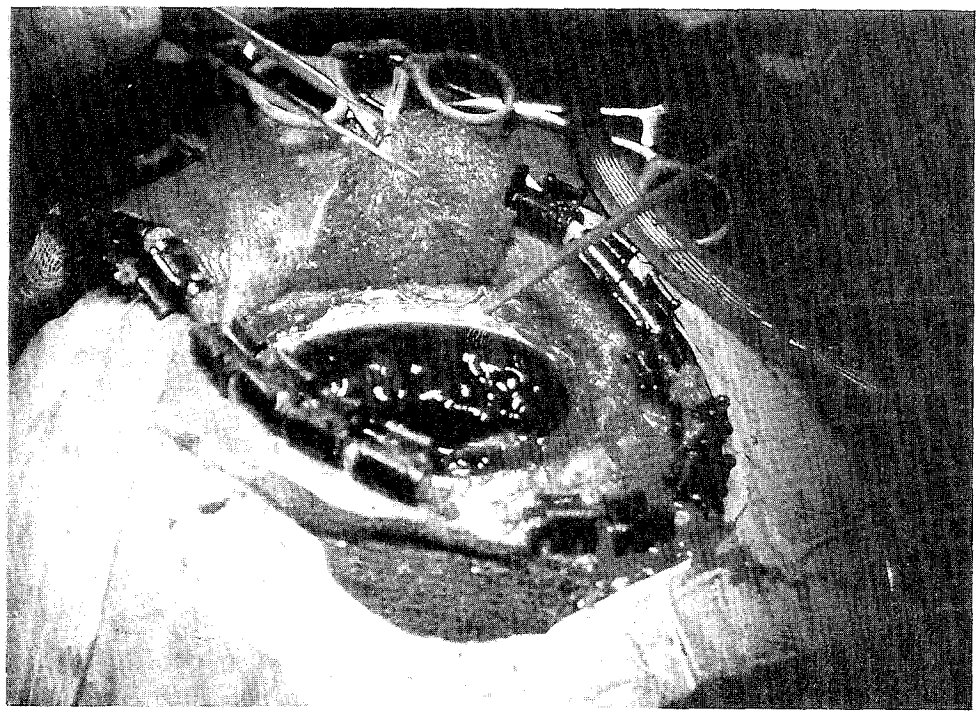

004D Operative photo revealing extrusion of blood clot from a right-sided subdural hematoma.

Contact Point- Exterior undercarriage- other vehicle
Type of Crash- Frontal- left side impact

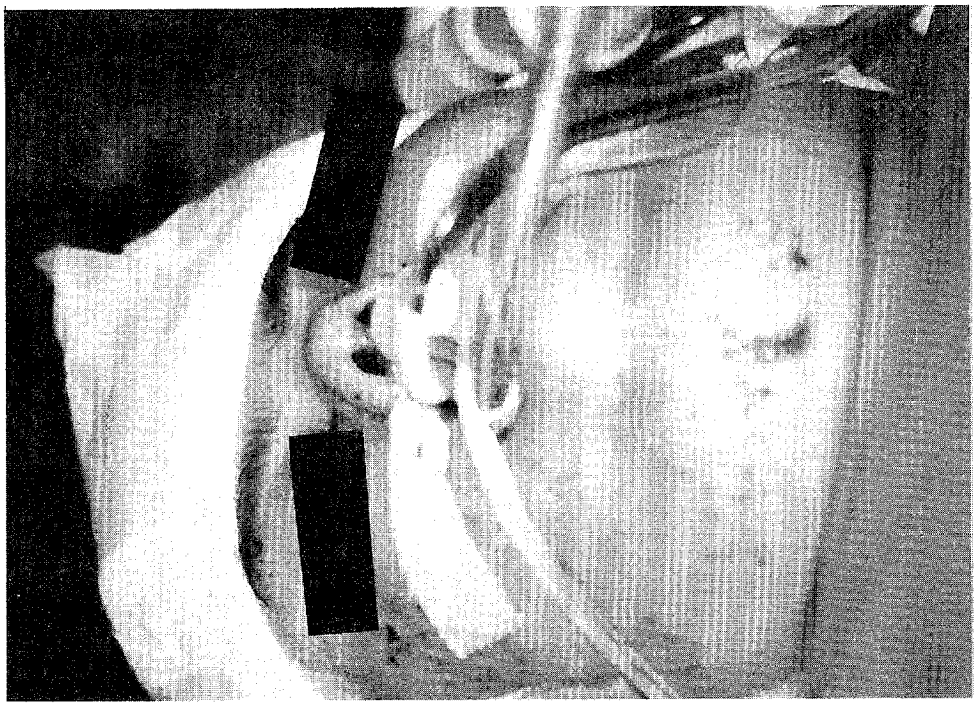

004A Multiple facial abrasions. The patient has been endotracheally intubated and is being ventilated by a respirator, and an oropharyngeal airway is in place. An intracranial pressure monitoring device is in place as well because of a closed head injury.

Contact Point- Exterior- other vehicle undercarriage
Type of Crash- Frontal-left side impact

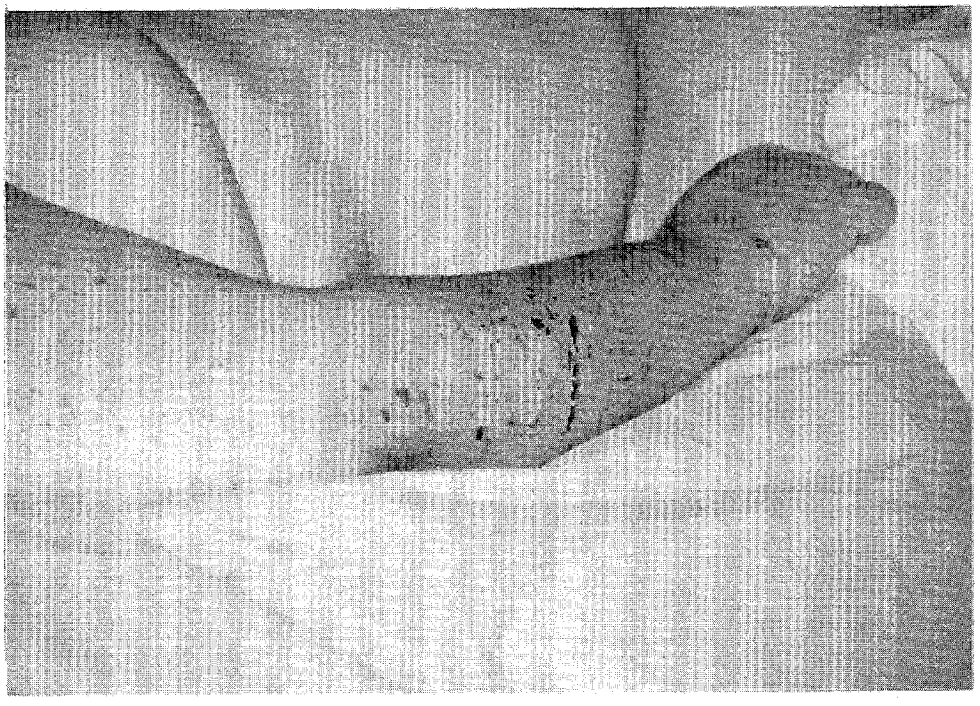

004B Multiple right arm abrasions.

Contact Point- Windshield flying glass and distorted instrument panel
Type of Crash- Frontal- left side impact

SELECTED PHOTOGRAPHS, CASE 004

3.



As V1 traveled under trailer frame, minor front end damage occurred. Full frontal contact at windshield (V1) caused shearing of windshield, "A" & "B" pillars (left) and "A" pillar (right).

4.

Tape marks show contact points of unbelted driver who "ducked" & traveled to passenger side--multiple lacerations & abrasions (AIS-2). V2 undercarriage contact--subdural hemotoma (AIS-4).

SELECTED PHOTOGRAPHS, CASE 004

1.

Scene photograph showing approach direction of V1. POI is located at skid marks in the center of the picture.

2.



V1; (1988 Plymouth Sundance 5 door hatchback); frontal impact; Max Crush 26.75" to right front bumper. Intrusion by V2 trailer (1984 Kenworth tractor trailer) 74.75" into occupant area.

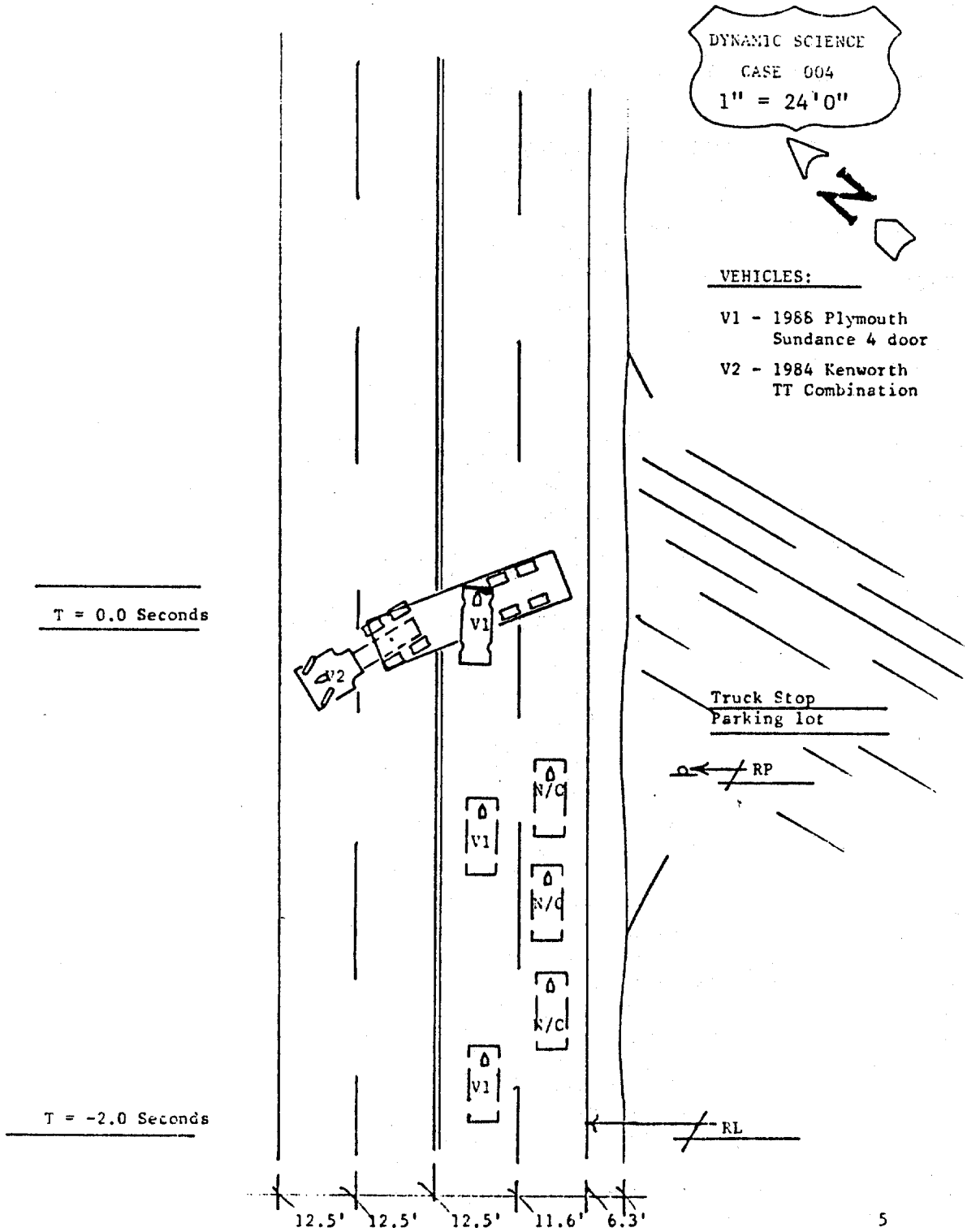
DYNAMIC SCIENCE
CASE 004
1" = 24'0"
N
VEHICLES:
V1 - 1988 Plymouth Sundance 4 door
V2 - 1984 Kenworth TT Combination
T = 0.0 Seconds
V1
V2
Truck Stop Parking lot
RP
N/C
V1
N/C
N/C
V1
T = -2.0 Seconds
RL
12.5'
12.5'
12.5'
11.6'
6.3'

5

programs. The use of these programs at license renewal time, mandatory in nature, could make the driver more aware of defensive driver tactics and the need to stay alert.

PREVENTION COMMENTS - CASE 004

This patient is an 18 year old female who drove under a tractor trailer which she obviously failed to see, since it blocked all four lanes of the road. She sustained a right complex subdural hematoma due to impact with the undercarriage of the tractor trailer, plus multiple facial lacerations due to the windshield and/or portions of the other vehicle's undercarriage. There were also other lacerations of the arm also related to windshield impact and flying glass. The patient was, in part, protected by the fact that in passing under the truck, her head first came into contact with the padded window sunvisor which to some extent protected her upper head from more serious injury, though the force was still transmitted through to the brain. She was unbelted and from the prevention point of view, belting certainly would have perhaps prevented her from moving more rapidly forward into the undercarriage, but probably would not have prevented the injuries. An airbag might possibly have provided cushioning between herself and the car structures, but from the enormous amount of damage to the windshield and A-pillar on impact even an airbag would not have totally protected her from injury.

T+ 35min: Patient arrives at MIEMSS. Initial physiologic assessment of the patient reveals a blood pressure of 220/20, a heart rate of 140, a respiratory rate of 42, and a Glascow Coma Score of 5. The patient's ISS (Injury Severity Score) = 20. Toxicology screen results were negative.

Initial hospital care provided includes:

- -Evaluation by a MIEMSS trauma team,
- -Fluid resuscitation,
- -Diagnostic peritoneal lavage with positive results,
- -Full diagnostic evaluation including x-rays of the cervical spine, chest and pelvis. In addition to the toxicology screen, an arterial blood gas, a CBC (complete blood count), an SMA-6 (routine blood chemistry) and UA (urinalysis) were performed.

Injuries noted include:

- -Complex Right Subdural hematoma (over frontal, parietal and occipital lobes),
- -Multiple lacerations and abrasions to the face (left and right cheeks),
- -Multiple lacerations and abrasions to the knees,
- -Multiple lacerations and abrasions to the right arm

Operative care includes:

- -Evacuation of blood from the right cerebral hemisphere,
- -Placement of an intracranial pressure monitoring device.

T+ 24hours - 10 days: Patient spends 10 days in critical care. The patient developed sepsis on T + 3 days and renal failure T + 9 days. The patient also developed pneumonia and cardiac failure as well.

T+ 10 days: Patient expires.

COGNITIVE-COMMUNICATIVE ASSESSMENT - CASE 004

This patient was not assessed due to the fact that at no point before her death was she neurologically stable.

PSYCHOSOCIAL FOLLOW-UP - CASE 004

No follow-up. Patient expired 10 days post trauma.

CRASH AND INJURY PREVENTION IDEAS - CASE 004

This accident occurred primarily because of driver inattention. the development of electronic "smart" highways, with the ability to analyze impending dangerous situations, and speed regulators, would greatly enhance the safety aspect of collision avoidance. The ability to overcome human error through the use of electronics will greatly reduce accidents such as this one. Drivers need constant reinforcement concerning safe driving

little or no speed change to Vehicle 1's forward momentum. As Vehicle 1's windshield was pushed rearward, a shearing action to the greenhouse occurred. Both the "A" and "B" pillars on the left side and the "A" pillar on the right side were deformed rearward and down approximately to the top of the right and left doors. Maximum intrusion to this area was approximately 75 inches rearward from the base of the windshield. The driver of Vehicle 1 sustained severe injuries consisting of a complex right subdural hematoma, AIS-4, and multiple facial lacerations and abrasions as a result of the windshield being forced rearward and by the exterior of the Vehicle 2 trailer as it intruded the driver's compartment.

T = + 0.13 Seconds (estimated): Vehicle 1 continued underriding the undercarriage of Vehicle 2 impacting the right forward tandem wheel of Vehicle 2's trailer. At impact Vehicle 1 sustained a maximum crush of 25 inches approximately 16 inches left of the left front bumper corner and rotated approximately 23 degrees clockwise and came to rest under the trailer of Vehicle 2. As the vehicle decelerated and rotated, the unbelted driver of Vehicle 1 was thrown from the left front seat forward and to the right into the right front seating area. Occupant contact points were noted at the left and right lower instrument panel consistent with the reported right and left knee lacerations and abrasions. The flying glass from the windshield and side windows contributed to the reported abrasions and lacerations as the occupant was propelled forward and over the floor mounted transmission shift lever console. Occupant contact points indicated the occupant loaded the right side of the steering wheel column, displaced the shift lever and console to the right, struck the right sun visor and glove compartment area and struck the right window just rearward of the "A" pillar. The hair and blood found in the area of the right "A" pillar indicate that it contributed to the head injury the occupant sustained.

T + 02:00 Minutes: The police and medical units were notified.

T + 04:00 Minutes: The police arrived and started investigative and medical relief efforts.

PREHOSPITAL AND HOSPITAL TIMELINE - CASE 004

T+ 2min: Ambulance receives call to respond.

T+ 4min: Ambulance arrives at scene. Initial field assessment reveals a blood pressure of 130/100, a heart rate of 60, a respiratory rate of 14, and a Glascow Coma Score of 3. Prehospital care includes fluid resuscitation with the administration of 100cc of crystalloid, endotracheal intubation, spinal immobilization, airway maintenance, and the monitoring of vitals. The patient required extrication from the vehicle.

T+ 23min: Patient departs scene for MIEMSS/Shock Trauma by ground ambulance.

currently in process of selling one in order to remain at hospital. The patient's father works as a welder for the state prison system. The patient has adequate private insurance coverage. The mother and patient were involved in an MVA a number of years ago which had a devastating effect on the mother and she has not driven since that time. The mother is extremely emotional, a reflection of the cultural background, yet kind and considerate of staff caring for daughter and able to integrate prayers and rituals at bedside in a non-cumbersome manner, touching all those around her. Rituals provide a safe outlet for the expression of emotions and the father was able to direct wife when necessary to get her to regain control.

The patient is a smoker, although rarely consumes alcohol and has no known history of drug use. The father admits to a casual attitude regarding seatbelt use, feeling belts are not effective, should be redesigned allowing for better left and right handedness. The father feels that drinking prior to driving does not cause more accidents due to tendency to drive slower and more cautiously, citing his own good driving record as an example. The family believes that alcohol should be taken off of the market if it is so dangerous.

The family is living at the hospital during the acute hospitalization with continued family service intervention and counselling while the patient remains comatose.

The patient expired at T + 10 days.

CRASE TIMELINE ANALYSIS - CASE 004

T = - 2.0 Seconds: The case occupant's vehicle, a 1988 Plymouth Sundance, was northbound at a speed estimated at 35 - 45 miles per hour on a 4 lane undivided asphalt paved highway in an urban area. The roadway is approximately 50 feet wide consisting of 2 northbound and 2 southbound lanes bordered on the east and west by businesses. The road has an estimated coefficient of friction of .70, and is straight and level at the point of impact. Traffic was light to moderate and no restrictions to visability were noted. Vehicle 2, a 1984 Kenworth tractor-trailer combination had departed a parking lot on the east side of the highway, crossed all 4 lanes of traffic and was attempting to turn south. Due to the length of the unit, the driver of Vehicle 2 had backed up in order to complete the turn and was just starting to move forward and to his left. Traffic in lane 1 northbound had stopped to allow the driver to clear the lanes.

T = - 1.0 Seconds: The driver of Vehicle 1, an 18 year old female, did not recognize that the lanes were blocked, and passed the stopped vehicles in lane 1.

T = 0.0 Seconds: Vehicle 1 struck Vehicle 2 forward of the left tandem wheels. Due to the differences in the vehicles' heights, Vehicle 1 passed under the undercarriage of Vehicle 2's trailer and contact was made at Vehicle 1's windshield. Some minor scrapes were noted on Vehicle 1's hood but would have made

				distorted instrument panel plastic
7.	2ALAI2	011111	913.0	Multiple L/arm abrasions	Windshield, flying glass, distorted instrument panel, plastic
8.	2KLAI2	091100	891.0	Multiple L/knee abrasions	Left instrument panel
9.	2KRAI2	111100	891.0	Multiple R/knee abrasions	Right instrument panel
10.	2KLLI2	091100	916.0	Multiple L/knee lacerations	Left instrument panel, flying glass
11.	2KRLI2	111100	916.0	Multiple R/knee lacerations	Right instrument panel, flying glass

PSYCHOSOCIAL SUMMARY - CASE 004

An 18-year-old obese, single female was admitted to MIEMSS Shock Trauma following a motor vehicle accident. The patient was the unbelted driver and sole occupant of a car which collided with a tractor trailer, becoming entrapped underneath the trailer, sustaining massive head trauma.

The patient is the youngest of two children and has a 20-year-old brother. Both children live at home with their parents. The patient had dropped out of high school during the past year due to emotional problems and difficulty with friends, low self-esteem due to weight and poor school performance having difficulty with both memory and concentration. The patient was once diagnosed as having a learning disability. Prior to the injury, the patient was working part-time in the dietary department of a local hospital and working towards getting a General Equivalency Diploma. The patient was also receiving workman's compensation due to a back injury received at work.

The patient's mother is Korean-born with a large extended family, Korean rituals, vigils and large support system. The family is deeply religious and the patient was in the process of converting to the Mormon religion, which is the faith of the paternal grandmother with whom she was extremely close. The patient was enroute to pick up the grandmother at the time of the accident. The father reports that the patient drives fast, is always in a hurry and gives little thought to safety.

The family owns and operates two sub shops although

SUMMARY - CASE 004 (020)

This two vehicle accident occurred during the morning hours of a weekday in May, 1989. It occurred on a 4 lane undivided asphalt paved road in an urban type area. The road is 50.0 feet wide and consists of 2 southbound and 2 northbound lanes and is bordered on the east and west by parking lots for various area businesses. Vehicle 1, a 1988 Plymouth Sundance 5 door hatchback was being driven northbound by an 18 year old female at a speed estimated at 35 - 45 miles per hour. Vehicle 2, a 1984 Kenworth tractor-trailer combination, was being driven by a 33 year old male. The driver of Vehicle 2 had just departed a parking lot on the east side of the northbound lanes and was attempting to turn southbound. Due to the length of his vehicle, he had blocked all 4 lanes while completing this maneuver. The driver of Vehicle 1 did not recognize that the lanes were blocked, passed several cars stopped in lane 1, and struck Vehicle 2 forward of the left side tandem wheels of the tractor. Vehicle 1 traveled under the trailer frame causing minor scrapes to the hood and made full frontal contact at the windshield. Severe shearing type forces sheared the windshield, deforming both "A" pillars and the "B" pillar of the left siderearward. The left exterior side of Vehicle 2's trailer intruded a total of 74.75 inches into the occupant compartment of Vehicle 1 as V1 continued forward striking the right side forward dual wheel of Vehicle 2. This impact produced a maximum crush of 26.75 inches located at C6 - the right front bumper corner of Vehicle 1. The driver of Vehicle 1 was not wearing the available lap/shoulder belts and sustained major injuries, the most severe being AIS-4 head injury. The driver of Vehicle 1 was transported to a major shock trauma unit and admitted. The reported injuries for the case occupant are listed in OIC format.

BODY CONTACTS & INJURY TABLE - CASE 004
18 year old female, 1988 Plymouth Sundance, frontal-left side impact

	OIC/AIS	ICD-9	BODY CONTACTS AND INJURIES	CONTACT POINT
1.	2HRUB4 801111	852.2	Complex right subdural hematoma	Exterior undercarriage other vehicle
2.	2FULI2 011111	873.59	Multiple facial lacerations	Windshield flying glass
3.	2FUAI2 801111	910.0	Multiple facial abrasions carriage	Exterior- other vehicle
4.	2ALLI2 011111	884.0	Multiple L/arm lacerations	Windshield flying glass
5.	2ARLI2 011111	884.0	Multiple R/arm lacerations	Windshield flying glass
6.	2ARAI2 011111	913.0	Multiple R/arm abrasions	Windshield glass,

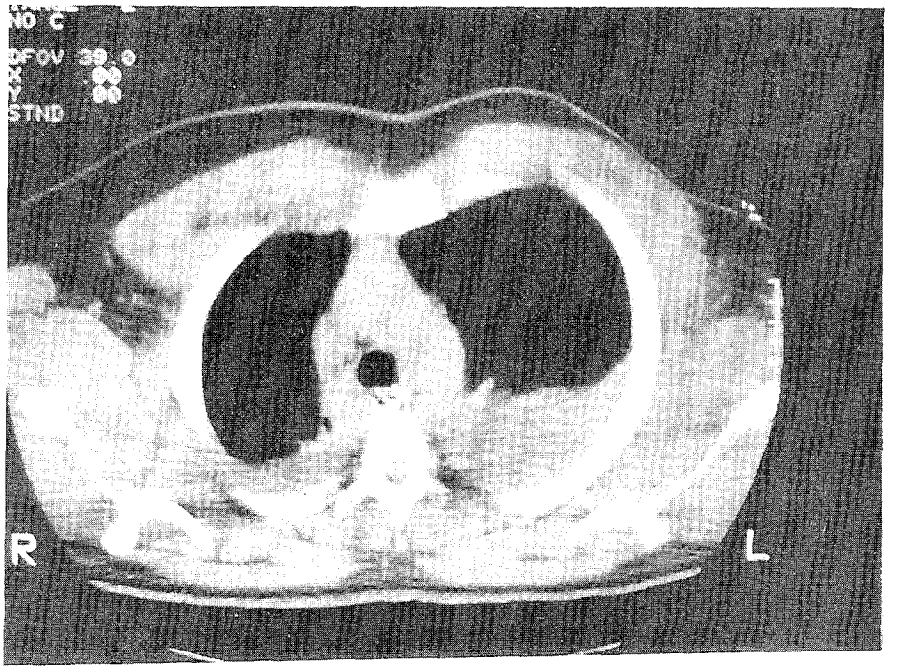

400C CT Scan revealing a bilateral hemothorax with blood in left and right pleural spaces as well.

Contact Point- Steering wheel combination
Type of Crash- Frontal impact

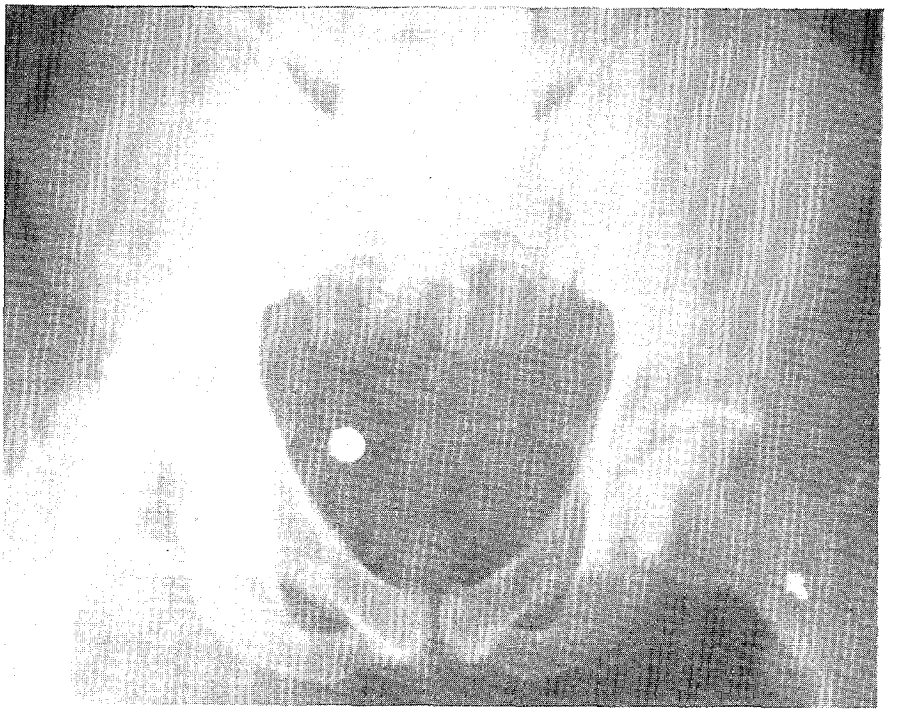

400D Pelvic X-Ray revealing a right acetabular fracture.

Contact Point- Steering wheel combination
Type of Crash- Frontal impact

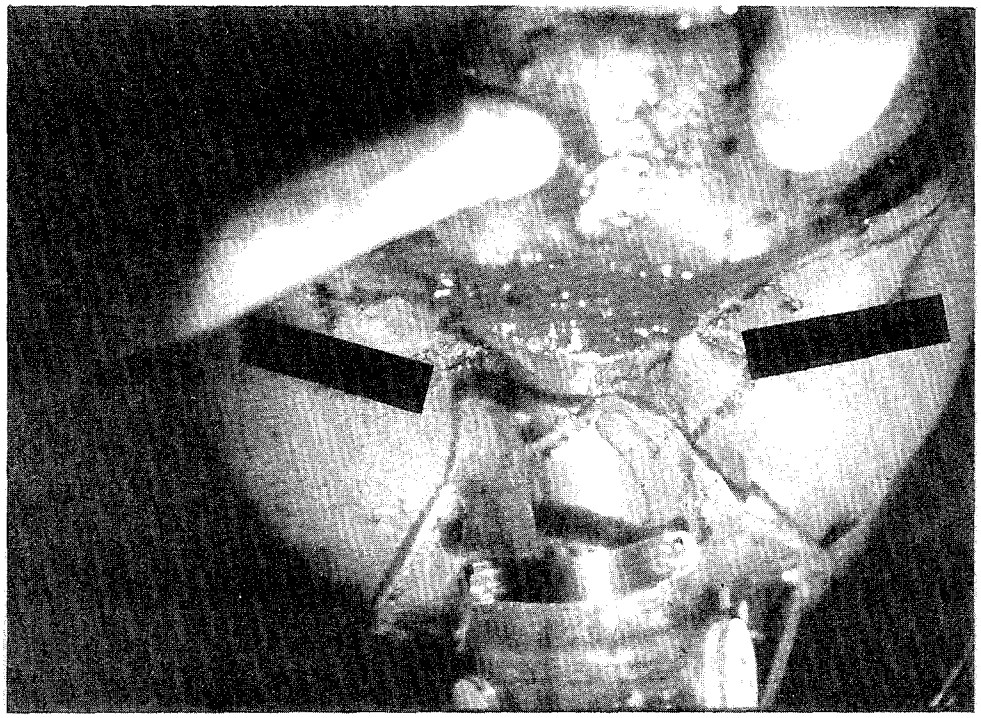

400A Extensive frontal scalp laceration. The patient is being administered oxygen by face mask at this time.

Contact Point- Windshield
Type of Crash- Frontal impact

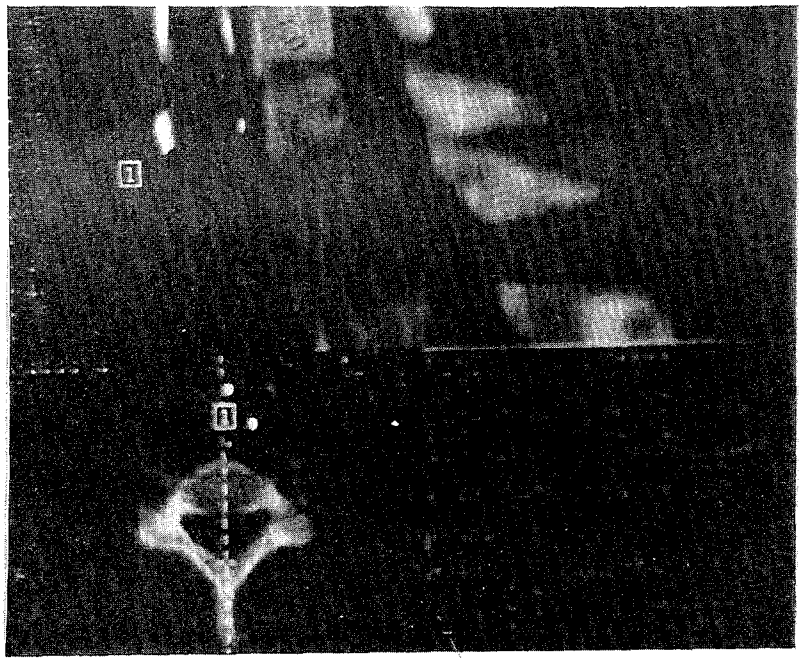

400B CT Scan revealing a C-7/T-1 spinal hyperdistraction. Note the widening between the C-7 and T-1 vertebral bodies. This is an unstable injury because of complete ligamentous disruption.

Contact Point- Windshield and impact forces
Type of Crash- Frontal impact

SELECTED PHOTOGRAPHS, CASE 400

3.

V1 - 1986 Volkswagen Jetta. Head-on impact. Max Crush = 38.5 inches at hood, bumper/midline. Intrusion (5 inches) and impact forces associated with this frontal impact caused

4.



the unbelted driver to contact the steering wheel and produce injuries of pulmonary contusion (AIS-4); right hip dislocation and right acetabular fracture (AIS-3).

SELECTED PHOTOGRAPHS, CASE 400

400-02

1.



Scene. From V1 direction of travel. Point of impact is located between yellow warning signs.

2.



V2 - 1969 Chevrolet C60 School Bus. Maximum Crush = 22.00 inches at left front bumper.

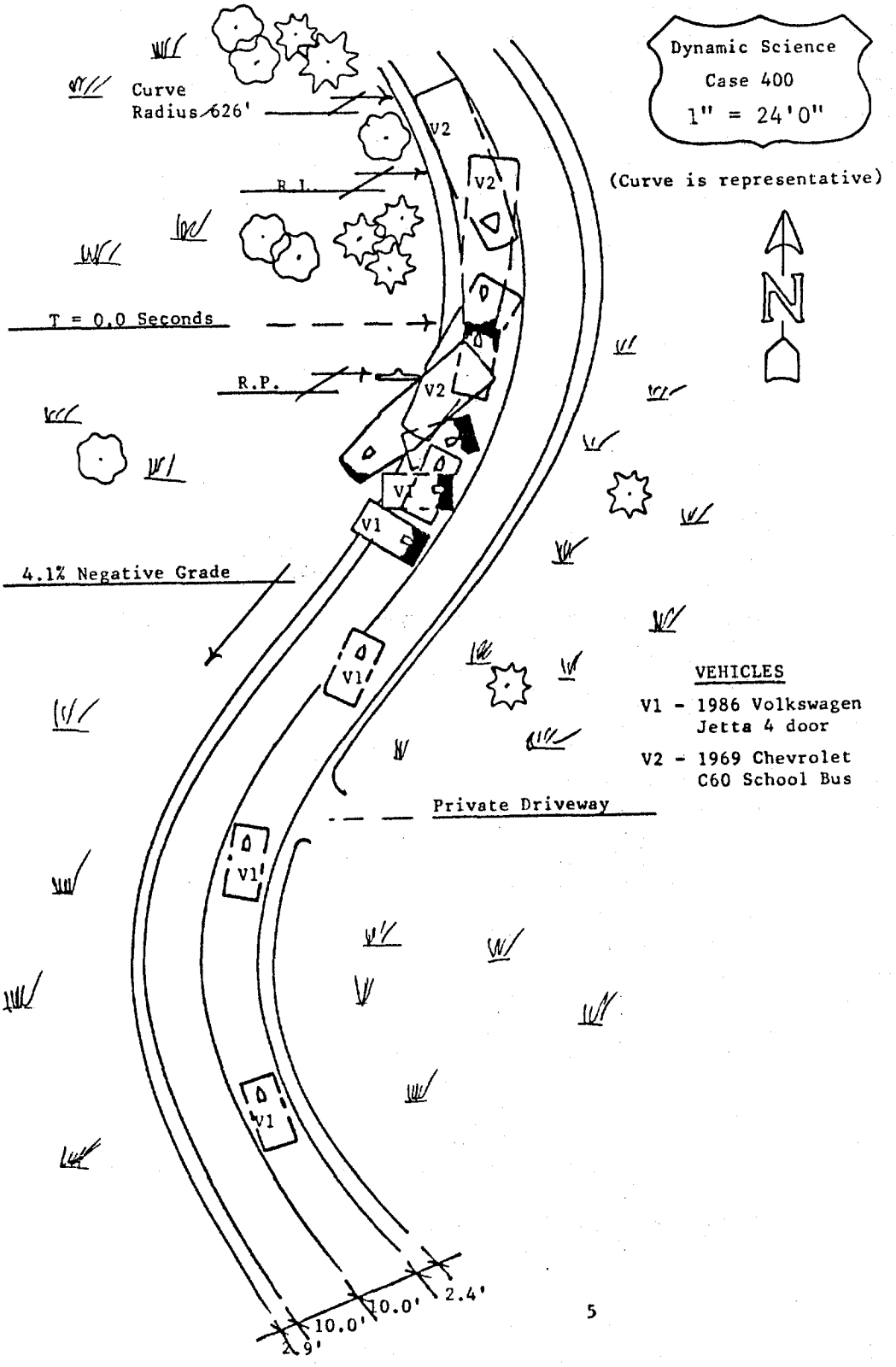
Dynamic Science
Case 400
1" = 24'0"
(Curve is representative)
Curve
Radius 626'
R.I.
T = 0.0 Seconds
R.P.
4.1% Negative Grade
Private Driveway
VEHICLES
V1 - 1986 Volkswagen Jetta 4 door
V2 - 1969 Chevrolet C60 School Bus
V1
V2
10.0'
10.0'
2.4'
2.9'
5

driver of a 1986 Vokswagon Jetta. He was traveling at a rate of speed too high to maintain control on a curve, crossed the center line and impacted head-on with a school bus. The patient sustained lacerations of the forehead due to impact with the windshield; dislocation at C7-T1 due to impact forces and the windshield; and a pulmonary contusion, right hip dislocation, and right acetabular fracture due to contact with the steering wheel combination.

Once again, had the automobile been provided with an airbag and the patient been wearing his seatbelt, the severity of these injuries should have been greatly reduced. This would be the case inspite of a maximum crush of 38.5 inches to the frontal plane of the vehicle.

the occupant did impact the steering wheel and the windshield which are the two biggest severe injury producers.

PSYCHOSOCIAL FOLLOW-UP - CASE 400

6 Months

At 4 months post-trauma, patient discharged to inpatient rehabilitation facility alert and oriented and non-ambulatory, where he remained for 38 days and was discharged home with continued outpatient rehabilitation twice a week. Patient was ambulating with canadian crutches and re-admitted to acute hospital at 6 months post-trauma due to spinal curvature evidenced by increased and sudden weakness in lower extremities.

Patient hospitalized the second time for 13 days in acute care and discharged to rehabilitation center for continued therapy to increase ambulation. Family continued to receive Medical Assistance Program and Social Services.

1 Year

Patient remained at inpatient rehabilitation center for 2 months following the second hospitalization and then discharged home for outpatient therapy 9 months post trauma. At one year patient continues to use wheelchair predominantly as developed edema in legs, blood clots and decreased mobility, never being able to ambulate independently.

Patient is an easy-going guy who rarely complains. Family currently receiving Social Security Disability benefits and Medical Assistance.

CRASH AND INJURY PREVENTION IDEAS - CASE 400

This accident occurred because a driver allowed his vehicle to drift across a center line while traveling at a speed faster than it was safe to do so on a curved road. Speed which could be electronically controlled by roadway signs on "electronically smart" highways would reduce the speed traveled and electronic sensing would warn the driver as he approached the center line and the approaching vehicle prior to impact. The development of electronically smart highways, with the ability to analyze impending dangerous situations and speed regulators would greatly enhance the safety aspect of collision avoidance. The ability to overcome human error through the use of electronics will greatly reduce accidents such as this one. While air cushion restraint systems and automatic belts would have probably reduced the sustained injuries, the difference in bumper heights also would have to be adjusted.

PREVENTION COMMENTS - CASE 400

This patient is a 37-year-old male who was the unrestrained

avaerage G's of the cases shown were approximately 40G's over 80 milliseconds.

Test Case Injuries:

The head COG curves for these test are shown at Figures 400-3 and 400-4. Perusal of the injury data in these cases show a HIC of 1008 for crash test #955 and 1290 for crash test #365. These seem consistent with the injury pattern of the actual crash. Further, the CSI's of the two cases are close at 1631 and 1151 and the parts of the vehicle impacted are also similar (steering wheel). In all, the crash test cases seem quite similar in result to the actual case even though the crush is somewhat less. The closeness of the test case to the actual is probably because we found a test case with almost the exact match as to type of vehicle and its dimensions.

Significance of the Crash:

This accident involved an unrestrained occupant. Aproximately 29% of all crashes resulting in injuries of any severity involved lack of use of available restriants. In fact the statistics show that unrestrained occupants are four times more likely to sustain AIS 3 or higher injuries than restrained and are 2.5 times more likey to be hospitalized or transported for treatment.

This case was a driver and we know from crash histories that 36% of the time the driver will be unrestrained. The conditions of the crash are fairly common. 43% of crashes with a vehicle in transport result in an AIS greater than 1 and head on crashes are two times as likely to result in an AIS greater than three than are crashes at any other angle. This accident was in a rural area travelling at a speed of 32-40 MPH. About 51% of all such crashes are passenger cars and 27% of those at this speed result in an AIS greater than or equal to 1. The driver is among the most uncommon age group (low relative to others) for incidences of this type (15%). The objects in the car which apparently caused the worst injuries are among the most common severe injury producers, the steering wheel and the Windshield (22% combined). The most interesting thing about this case is that it was not fatal. It should have been fatal in the statistical sense. 78% of the time accidents in passenger cars drivers of this age group suffer a fatality and 65% of all fatal crashes are passenger cars.

This crash is fairly common and the injury severity is consistent with the conditions of the accident as compared to national statistics. The only surprising thing is that it was not a fatal accident. After all, there was very severe crush involved and

school bus operated by a 33 year old male driver which carried 23 occupants, primarily teenage boys and girls.

COGNITIVE-COMMUNICATIVE ASSESSMENT - CASE 400

When initially consulted on T + 40 days, a tracheostomy had been performed on the patient who, at the time, was on a respirator and had upper extremity paresis. The patient was unable to write, therefore, he was presented with an electrolarynx. His initial evaluation was given on T + 48 days. Overall scores on the test were low due to his non-vocal status (the electrolarynx was used) and paresis. The patient was felt to be at an RLAS VI (Rancho Los Amigos Score) level. Recommendation was to reassess when the patient was vocal and in a better position to point. The patient failed a hearing screening and was NPO, or unable to be administered anything by mouth.

The patient was given a discharge evaluation on T + 60 days. He was no longer trached and was able to point. The most significant area of deficit was that of written expression which could not be assessed due to upper extremity paresis. Subtle or no deficits were noted in the areas of auditory comprehension, verbal expression, written comprehension, speech and cognition. The patient was diagnosed as having a mild hearing loss and was on a P.O. diet. No treatment was indicated and the patient was discharged from speech language pathology services.

CRASH COMPARISON, CASE 400

An initial pass through the data base showed some six cases for possible use in this crash comparison. They are shown below in Table 400-1.

Table 400-1 Results of Data Query

Mak	Mod	Bod	T#	YR	LBS.	Length	Width	COG	Wbase	Speed	V#	Crush
08	14	2S	797	85	2844	172.00	66.00	45.10	97.40	34.80	1	22.70
		4S	1208	88	2810	172.10	65.50	42.70	97.50	29.10	1	16.10
			955	85	2830	171.60	65.50	43.80	97.20	35.30	2	28.10
			277	81	2650	170.60	63.40	38.60	95.00	0.00	2	27.20
			338	81	2521	170.70	63.50	42.10	95.00	34.80	1	26.30
			365	81	2650	167.40	63.50	55.60	115.90	34.90	1	25.00

Of these cases, test numbers 955 and 365 were judged by the simulation team to be closest in characteristics, especially speed and crush. The Crash Test Curves for these cases are shown at Figures 400-1 through 400-2. The curves used were the Center of Gravity and the Engine. It is estimated that the

T + 6:00 Minutes: The police arrived and started investigative and medical relief efforts.

PREHOSPITAL AND HOSPITAL TIMELINE - CASE 400

T+ 1min: Ambulance receives call to respond.

T+ 9min: Ambulance arrives at scene. Initial field assessment reveals a blood pressure of 70/palp, a heart rate of 60, a respiratory rate of 18, and a Glascow Coma Score of 15. Prehospital care includes includes fluid resuscitation with the administration of 2000cc of crystalloid. The MAST suit was applied and inflated at the scene. The patient required extrication from the vehicle.

T+61min: Patient departs scene for MIEMSS/Shock Trauma by ground ambulance.

T+81min: Patient arrives at MIEMSS. Initial physiologic assessment of the patient reveals a blood pressure of 70/palp, a heart rate of 60, a respiratory rate of 18, and a Glascow Coma Score of 15. The patient's ISS (Injury Severity Score) = 27. Toxicology screen results were negative. Initial hospital care provided includes:

-Evaluation by a MIEMSS trauma team,
-Fluid resuscitation,
-Diagnostic peritoneal lavage with results.
-Full diagnostc evaluation including x-rays of the cervical spine, chest and pelvis. In addition to the toxicology screen, an arterial blood gas, a CBC (complete blood count), an SMA-6 (routine blood chemistry) and UA (urinalysis) were performed.

Injuries noted include:

-Right Posterior Hip Dislocation,
-Right Acetabular Fracture,
-Bilateral Pulmonary Contusions,
-C7- T1 Cervical/Thoracic Spine Hyperdistraction.

Operative care includes:

-Reduction and stabilization of the cervical hyperdistraction.

T+24hours - 106 days: Patient spends days in intensive care and days in intermediate care. Complications include the following: sepsis, adult respiratory distress syndrome (ARDS), and aspiration pneumonia. The patient also developed a pulmonary embolus for which a filter was surgically placed to prevent furher emboli development.

T+ 106 days: Patient discharged from MIEMSS to home unable to ambulate.

Other victims in the same crash within the same vehicle include a 4 year old female who was evacuated to the regional pediatric trauma specialty referral center. Vehicle #2 was a

to weekends, and drinking has not interfered with employment. She denies his use of other drugs but does state that the patient returned to smoking shortly after leaving the military. She describes the patient as a fairly safe driver, generally a seatbelt wearer and conscientious about seatbelts for the children.

The wife is an adaptable lady with a good sense of humor and is coping appropriately during this acute phase of injury.

CRASH TIME LINE ANALYSIS - CASE 400

T = 5.0 Seconds: Vehicle 1, a 1986 Volkswagen Jetta 4 door sedan, was northbound at an estimated speed of between 39 and 47 miles per hour. The roadway is a curved, hilly, 2 lane asphalt paved feeder route with a wet coefficient of friction estimated at .50. The "S" turn that Vehicle 1 departed has a radius of 626' and a positive grade of 4.1%. Neither the driver, a 37 year old male, nor the occupant in the right front seat, a 4 year old female, was wearing the available lap/shoulder belts. Vehicle 2, a 1969 C60 school bus with 23 occupants in various seating positions, was being driven southbound by a 33 year old male.

T - 1.0 Seconds (estimated): The driver of Vehicle 1 allowed the vehicle to cross over the center line and into the path of Vehicle 2. No evasive action by the driver of Vehicle 1 was evident. The driver of Vehicle 2 attempted braking and was restricted by terrain features from steering to his right.

T = 0.0 Seconds: Vehicle 1 had departed the northern portion of an "S" turn in a near straight path into the southbound lane and at point of impact was at a point 2.4' from the west edge of the roadway. Vehicle 1 sustained a maximum crush of 34.5" and a direct damage width of 53.0 inches. Due to the height of Vehicle 2's bumper, an underlying effect caused the damage to Vehicle 1 to be above the bumper and extend almost to the firewall. At impact the unrestrained driver moved forward contacting the steering wheel with his upper torso causing the steering assembly to be moved upwards an estimated 10 inches. This contact point is consistent with the pulmonary contusion medically reported. The combination deformation of the steering rim and intrusion of the lower dash shows contact points which would contribute to the right hip dislocation and right acetabular fracture. The driver struck the windshield with his head resulting in a large laceration to the forehead. As his vehicle decelerated to a stop and was pushed rearward by the heavier vehicle, the bus, impact forces combined with the head impact and probably caused the dislocation of the C7T1 vertebrae.

T + 0.5 Seconds (estimated): All forward movement by Vehicle 1 had stopped, and Vehicle 1 was pushed rearward coming to final rest 33 feet rearward of the point of impact facing east at the west side of the southbound lanes.

T + 1:00 Minutes: The police were notified and started responding.

Skin transfer, deformed Right leg & abraded plastic	light
Displaced shift lever	Right thigh
Deformed brake pedal	Right foot
Deformed plastic/ fabric transfer	Left knee
Deformed plastic fabric transfer	Right knee

PSYCHOSOCIAL TIMELINE - CASE 400

A 37-year-old married male was admitted to MIEMSS Shock Trauma after sustaining multiple injuries following a motor vehicle accident on a rainy morning. The patient was the driver of a car which collided with a bus head-on. At the time, the patient and his four-year-old daughter were returning from a store where they had just purchased flowers and cards for Mother's Day. The daughter was taken to the regional pediatric trauma center for treatment, observation and was later released. The patient was placed in a medically-induced coma and remained in such state 31 days post-trauma. The patient is now following commands and is oriented at five weeks post-trauma although unable to speak due to intubation.

The patient lives at home with wife of 16 years and has two daughters, ages 8 and 4. The patient's parents are alive and live in Florida. The patient is the oldest of four children, having 1 brother and 2 sisters who reside out-of-town. The patient is not close to his family of origin, primarily due to distance and patient's frequent travel while in the military. For the past 10 months, the patient has worked as a technician for an overhead garage door company after having left the armed services following 15 years of duty. He is a high school graduate with vocational training in electronics.

The wife decribes the patient as a bright man, dependable, physically active in sports and weight-lifting as well as enjoying outdoor activities such as fishing. Although leaving the military was an adjustment, the wife feels it was a successful one both personally and economically. However, the patient did not have adequate health insurance coverage and out of necessity, the family was forced to apply for medical assistance. The wife is currently not working and hopes to live on family savings until the patient's medical status is stable and future determined. Although the family had lived in Maryland previously, they had also lived in Florida, Italy and Japan for several years.

Wife indicates that the patient has had a problem with alcohol in the past, although minimizes its importance. She does admit that the patient was hospitalized in a 28-day alcohol treatment program two years prior to injury, following a DWI. She states that he continues to drink although primarily confined

SUMMARY - CASE 400 (019)

This accident occurred in the morning hours in the spring on a 2 lane rural road in central Maryland. The roadway is asphalt paved with an estimated coefficient of friction dry .65 and .55 wet. It is curved, hilly and has numerous warning signs concerning speed and conditions. Vehicle 1, a 1986 Volkswagen Jetta, being driven northbound by a 37 year old male, had a 4 year old female passenger in the right front seat. Neither the driver nor the passenger was wearing the available lap/shoulder belts. Vehicle 2, a 1969 Chevrolet C60 school bus, being driven by a 33 year old male, was southbound with 23 occupants of various ages, primarily teen-age boys and girls. This vehicle is not equipped with safety belts. The driver of Vehicle 1 failed to straighten his vehicle's path after exiting a right hand curve and crossed the center line into southbound traffic, striking Vehicle 2 frontal plane to frontal plane. Vehicle 1 sustained heavy frontal damage with a direct damage width of 53 inches and a maximum crush of 38.5 inches. The delta-V was computed as 39.1 miles per hour using Crash PC. The direct and induced damage extended rearward intruding the driver and passenger's compartment contributing to the severe injuries associated with this accident. The driver of Vehicle 1 sustained multiple injuries with the highest being AIS-4, a pulmonary contusion. His passenger received a closed head injury of at least AIS-2. The driver of Vehicle 2 was uninjured; his passengers received minor injuries with a reported maximum AIS-2.

BODY CONTACTS AND INJURIES TABLE-CASE 400

37 year old male; driver; 1986 Volkswagen Jetta; Frontal impact

OIC/AIS CODE		ICD-9	BODY CONTACTS AND INJURIES	CONTACT POINT
1.2FCLI2	011100	873.42	Laceration, large forehead	Windshield
2.2NPDV3	141100	839.07	C7/T1 dislocation	Windshield/ impact forces
3.2CLCP4	061111	861.21	Pulmonary contusion	Steering wheel combination
4.2PPDJ3	061111	835.01	Right hip dislocation	Steering wheel combination
5.2PRZJ3	061111	808.0	Right acetabular fracture	Steering wheel combination
Contact:	Unknown if injured		Abraded, deformed plastic	L/lower panel
			Abraded, skin transfer	"A" pillar
			Abraded, skin transfer	Upper L/F window frame
			Broken lens, deformed metal	Interior

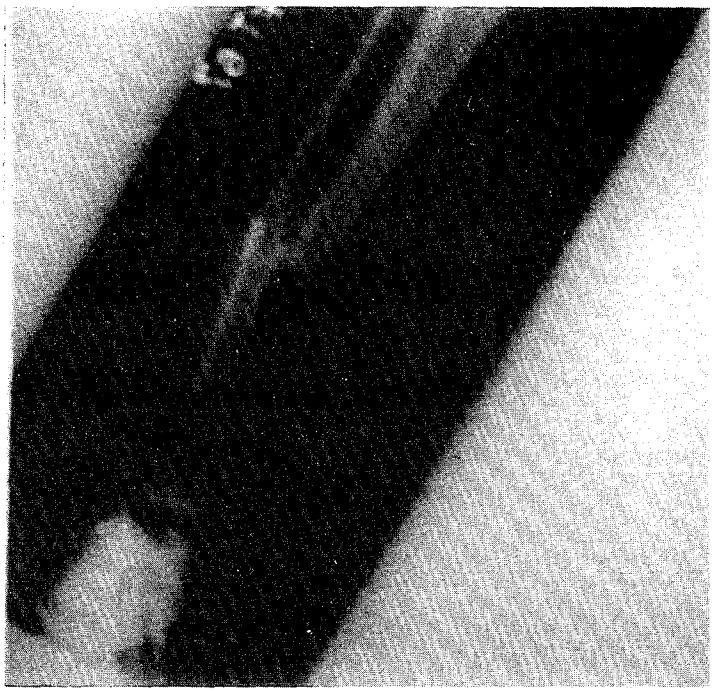

427C Prereduction X-Ray revealing transverse, midshaft fractures of the left tibia and fibula. The fracture pattern suggests a combination of axial and direct impacts to the bone without a rotatinal component.

Contact Point- Lower Right Instrument Panel and Exposed Chassis floorboard/toepan
Type of Crash- Frontal impact

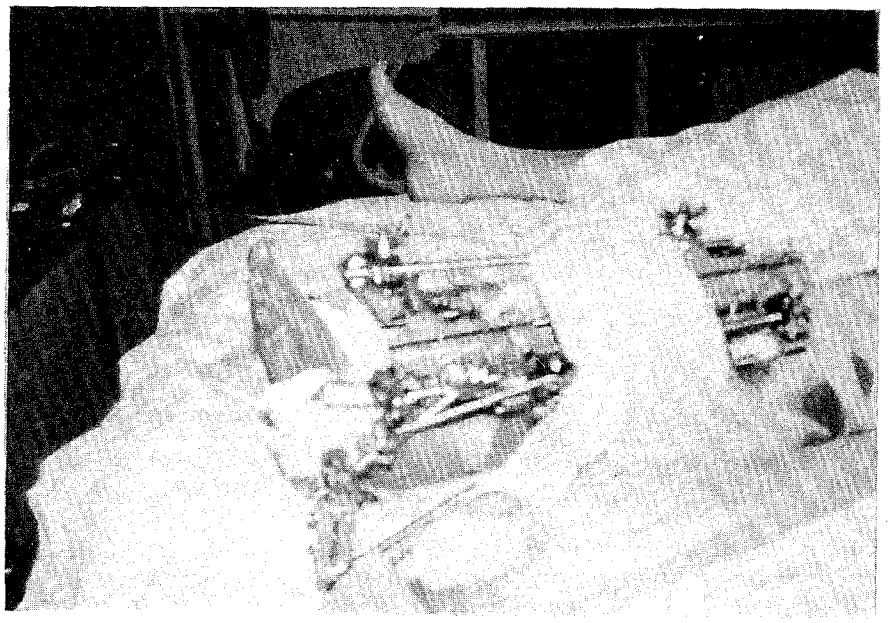

427D External fixator apparatus for stabilization of the fractures to the left tibia and fibula shown in 427C.

Contact Point- Lower Right instrument panel and exposed chassis floorboard/toepan
Type of Crash- Frontal impact

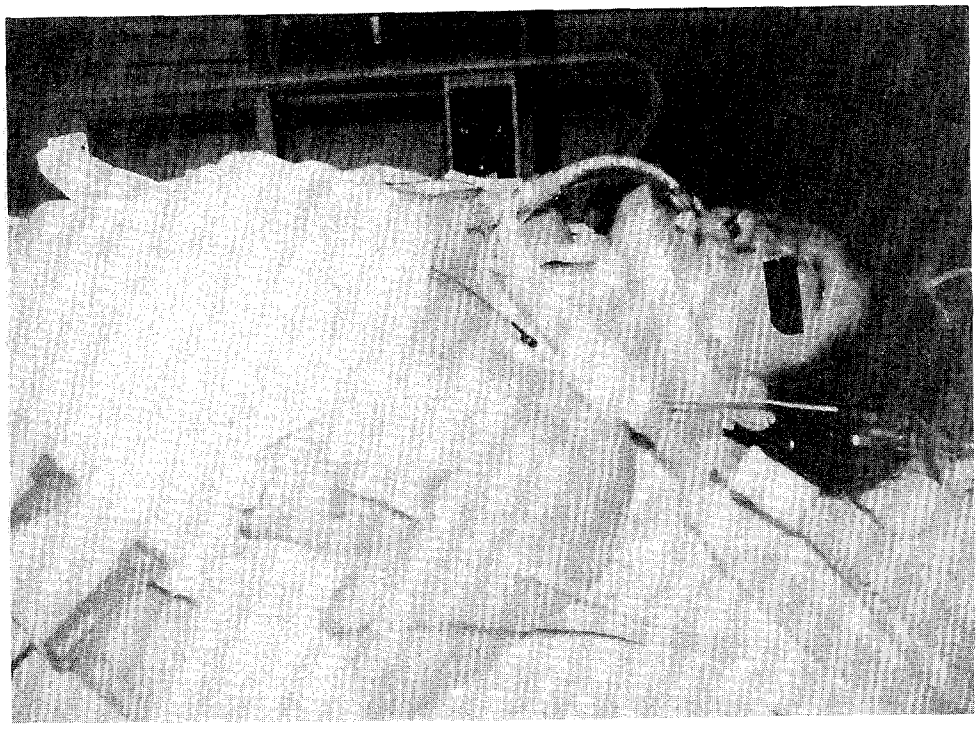

427A Multiple contusions and abrasions of the face and left chest. The patient has been endotracheally intubated, is being ventilated by a respirator and has a Philadelphia Collar which immobilzes the cervical spine.

Contact Point- Upper Right Instrument Panel
Type of Crash- Frontal Impact

427B X-Ray revealing a left femur fracture repaired with an intramedullary rod.

Contact Point- Glove box door
Type of Crash- Frontal impact

SELECTED PHOTOGRAPHS, CASE 427

3.



V1 (1967 Chevrolet Malibu 2 door sedan). Max crush = 30.7 inches. Delta V = 17 to 25 m.p.h. Roof, front, sides altered post-crash.

4.



V1 RF seat.Integrity loss;floor pan (AIS-3&2 ankle/fibula) Right instrument panel (AIS-3 femur/tib-fib, AIS-2&1 head/face/chest)

SELECTED PHOTOGRAPHS, CASE 427

1.

Scene. Wet 2-lane rural road. V1 direction of travel. Curve radius = 349 feet. Tree contacted is in center of photo.

2.

Scene. Tree contacted. 26 inch diameter (measured across the plane contacted by V1).

COLLISION SCHEMATIC
Case 427

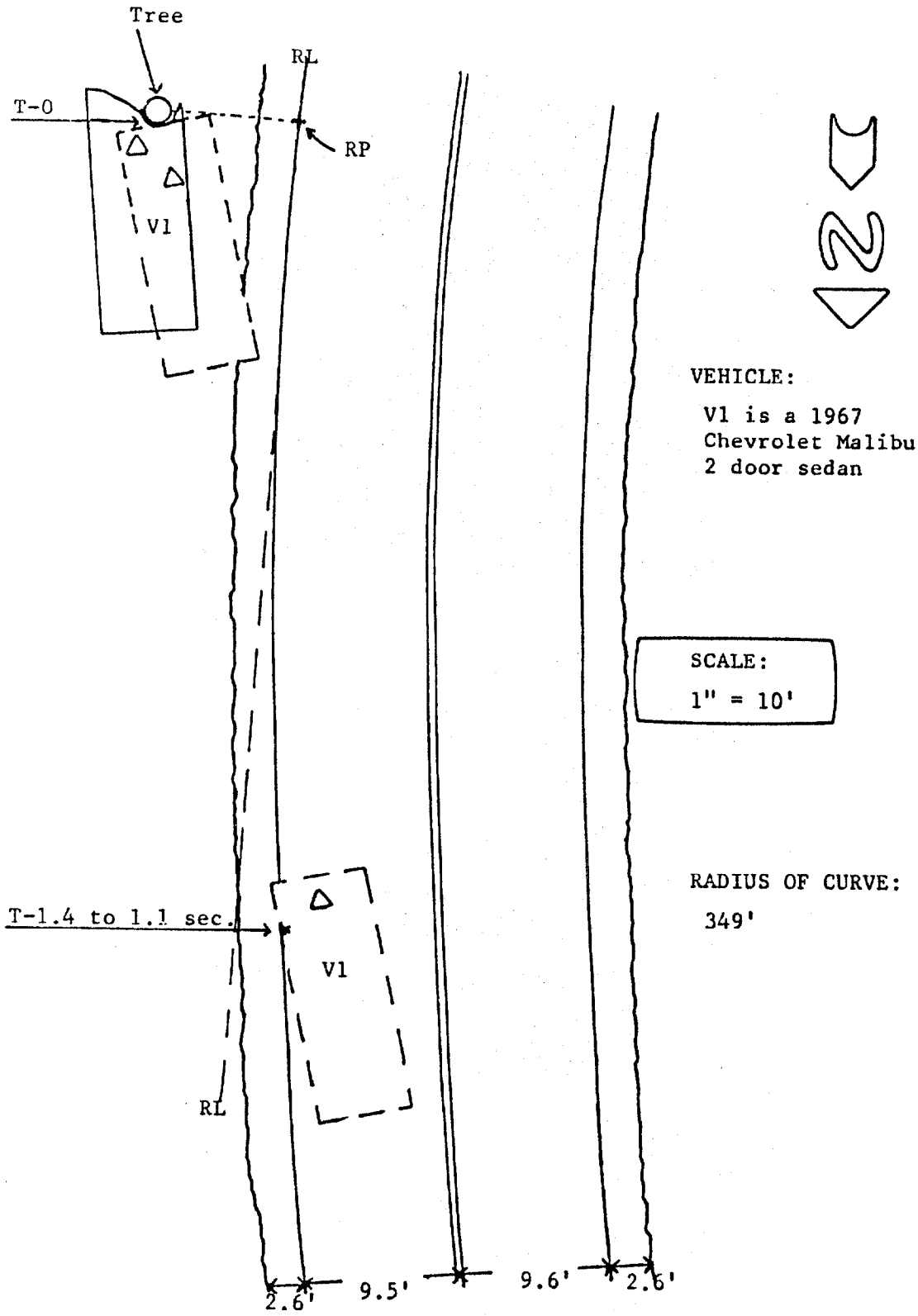

abuse. The patient sustained a fracture of the left femur on contact with the glove box door; lacerations of the nose on contact with the instrument panel; and most significantly, the toe pan gave way so that her foot was projected below the car where she sustained a severe, open comminuted Grade III injury to the left fibula and tibia, as well as a left fractured talus involving the proximal articular surface.

In terms of prevention, this alcohol related accident might have been totally prevented had there been some kind of a ignition check scheme to prevent an intoxicated driver from operating the car. Secondly, the contact point of the car was a tree fairly close to the roadway on a sharp curve; perhaps a program of clearing the roadway of such obstructions on sharp curves might be a prophylactic measure.

With regard to the car related injuries, as the patient was unbelted, a mandatory seatbelt or an airbag in the passenger compartment would probably have prevented the head trauma and the abrasions and lacerations of the nose and face. The seatbelt probably would have prevented some forward motion and might have reduced the impact of the left leg on the glove box door resulting in the fractured femur. However, most significantly the deteriorated rusted condition of the car allowed the toe panel to split, projecting the left leg below the chassis of the car so that it was severely lacerated and damaged on impact. This might have been prevented by having an inspection standard that would have eliminated this car from the road because of excessive rusting of the body and frame.

1 Year

Patient continues to undergo therapy and numerous surgical procedures for nose and face. She underwent gait training and ambulating with a cane. Also taking an Amputee Training Program in order to volunteer and assist other amputees as well as doing public speaking re: impact of crash. She is beginning to resume former activities and motivated to become fully independent. Currently receiving Social Security Disability and has begun a course in computer work paid for by Maryland State Rehabilitation Center. Patient continues to be covered by the Medical Assistance Program. Patient's husband has returned to sporadic work as a self-employed carpenter.

PREVENTION AND INJURY REDUCTION - CASE 427

This case is similar to cases 169 and 418 in that it involves a driver who was under the influence of alcohol and whose vehicle departed a curve and struck a tree. Another unfortunate similarity is the fact that the right front passenger was subjected to the most severe of the impact forces. Due to the age of the vehicle, it is hard to apply the structural failures in this crash to crashes involving newer automobiles. For example, the right front toepan separated from the dashpanel which exposed the vehicle's undercarraige. This integrity loss caused severe damage to the case's left ankle. It would be very unlikely given a Delta V of about 20 m.p.h. that these components would separate in newer vehicles due to today's construction techniques. It is also unlikely that our case's other injuries would have been as severe had she contacted a modern padded plastic instrument panel instead of a metal instrument panel. If she had used the available manual lap belt, she might have avoided the ankle injury, but her head would still have moved toward the metal instrument panel.

This case goes a long way in revealing some of the safety changes that have been made through the years as a result of highway safety research. Vehicle interiors are generally much more forgiving to occupant contact than they once were. The severe injuries suffered in this crash support the need for new advanced occupant protection devices and techniques. As for this particular type of crash, the ultimate preventative measure would be to effectively prohibit people from driving under the influence of alcohol.

---- Jerry Jackson

PREVENTION COMMENTS - CASE 427

This patient is a 36 year old female who was a right front seat passenger in a 1967 Chevy Malibu. Her husband had been drinking prior to the accident and had a long history of alcohol

1/3 with ischemia and distal 1/3 vascular deficit),
-Left Fibula Fracture (Closed, Oblique, Lower 1/3),
-Left Talar Fracture (Open Grade III, Comminuted, Proximal Articular Surface),
-Left Ankle Dislocation (Posterior Type with Multiple Ligament injury and Vascular injury)

Operative care included:
-Closed reduction of Left Tibia with external fixation and irrigation and dilation,
-Open reduction of Left Femur with intramedullary rodding,
-Closed reduction of Left Fibula with external fixation and irrigation and dilation,
-Closed reduction of Left Talus with external fixation and irrigation and dilation, and
-Delayed Open Reduction of nasal fracture with internal fixation

T+24hours - 17 days: Patient spends 6 days in intensive care and 11 days in intermediate care. No complications were reported during the acute care hospitalization of this patient.

T+ 17 days: Patient discharged from MIEMSS to home unable to ambulate.

COGNITIVE-COMMUNICATIVE ASSESSMENT - CASE 427

The patient's cognitive-communicative skills were evaluated on T + 6 days. Her major complaint in this area was that she felt that she had a difficult time concentrating since the collision. Evaluation results indicated that the patient's auditory comprehension, written expression, speech and cognitive skills were within normal limits. She was given suggestions about how to improve her concentration. The patient appeared to be at an RLAS VIII level (Rancho Los Amigos Score.) No therapy was indicated and she was discharged from speech language pathology services. Hearing and swallowing were within normal limits.

PSYCHOSOCIAL FOLLOW-UP - CASE 427

6 Months

Patient discharged to home 17 days post-trauma with physical therapy. Patient unable to ambulate at that time without assistance and confined to wheelchair. In the 6 months since injury, patient has experienced severe pain and foot doing poorly, necessitating re-admission and below the knee amputation at 6 months post-trauma. Patient received Medical Assistance Program and food stamps, although not eligible for Social Services due to small insurance settlement. Husband also not employed due to need for further therapy and difficulty finding employment.

case, and she was transported by helicopter to a trauma hospital for treatment. V1 was towed from the scene with disabling damage, however, the vehicle was further damaged after the crash. Upon inspection, the drive train, the rear suspension, the front wheels and tires, the steering wheel, and the doors were removed. V1 was removed from a pile of junk cars by forklift to enable the inspection. The exterior of V1 was found to have extensive damage that was not related to the crash, and it is probable that the crash related damage was altered when the drive train was removed. For these reasons, Intrusion could not be measured with any degree of accuracy, and the exterior crush measurements may not provide the exact crash related profile.

T + 4 minutes: The Police were notified of the crash.

T + 30 minutes: Police arrived at the scene.

PREHOSPITAL AND HOSPITAL TIMELINE - CASE 427

T+ 18min: Ambulance receives call to respond.

T+ 48min: Ambulance arrives at scene. Initial field assessment reveals a blood pressure of 140/80, a heart rate of 80, a respiratory rate of 15, and a Glascow Coma Score of 15. Prehospital care includes includes fluid resuscitation with the administration of 1700cc of crystalloid. The patient required extrication from the vehicle.

T+84min: Patient departs scene for MIEMSS/Shock Trauma by police medevac helicopter.

T+102min: Patient arrives at MIEMSS. Initial physiologic assessment of the patient reveals a blood pressure of 122/70, a heart rate of 113, a respiratory rate of 24, and a Glascow Coma Score of 15. The patient's ISS (Injury Severity Score) = 17. Toxicology screen results were negative. Initial hospital care provided includes:

-Evaluation by a MIEMSS trauma team,
-Fluid resuscitation,
-Diagnostic peritoneal lavage with negative results,
-Full diagnostic evaluation including x-rays of the cervical spine, chest and pelvis. In addition to the toxicology screen, an arterial blood gas, a CBC (complete blood count), an SMA-6 (routine blood chemistry) and UA (urinalysis) were performed.

Injuries noted include:

-Closed head injury with no loss of consciousness,
-Abrasions (Left Forehead, Nose and Right Eyelid),
-Superficial Lacerations (Left Chin/Jaw and Nasal Septum),
-Closed Nasal Fracture,
-Multiple Bilateral Chest Abrasions,
-Laceration (Left Elbow),
-Left Femur Fracture (Closed, Transverse, Middle 1/3),
-Left Tibia Fracture (Open Grade III, Comminuted, Middle 1/3 with ischemia and distal 1/3 vascular deficit),
-Left Fibula Fracture (Open Grade III, Comminuted, Middle

occurred on a rainy weekday night. The collision involved a 1967 Chevrolet Malibu 2 door sedan (V1) with a 39 year old male driver, a 36 year old female right front seat passenger (our case), and a 14 year old male middle rear seat passenger. None of the occupants were using the available manual lap belts. V1 was southbound on a winding 2 lane rural asphalt road. The roadway was wet and had an estimated coefficient of friction of .5. The northbound lane was approximately 9.5 feet wide and was separated from the southbound lane by a double yellow paint stripe. The southbound lane was approximately 9.6 feet wide. The roadway was bordered on each side by a 2.6 foot wide stabilized gravel shoulder and the shoulders were bordered by dirt and grass. The posted speed limit was 30 miles per hour and the road was not lighted.

V1 entered a sharp right hand curve which had a radius of approximately 349 feet. V1 began to sideslip to the left and the evidence suggests that the driver acted to decelerate and straighten the steering of V1 in order to avoid losing control of the vehicle. V1 crossed the double yellow center stripe and departed the roadway to the left.

T - 1.4 to 1.1 seconds: Upon departing the roadway, V1 was traveling an estimated speed of between 32 and 38 miles per hour. V1 continued south another 51.6 feet before impact.

T - 0: The front of V1 impacted a 26 inch diameter tree. Direct contact began 19.1 inches to the right of the left front bumper corner and extended 24 inches laterally to the right. Maximum longitudinal crush to the front bumper was measured to be 30.7 inches. The principal direction of force acting on V1 was approximately 20 degrees to the left of straight ahead, or 11 o'clock from the 3 occupants' perspectives. Estimated speed change at impact was between 17 and 25 miles per hour.

The driver reportedly sustained non-incapacitating injuries. The middle rear seat passenger was reported as possibly injured. The right front seat passenger (our case) sustained several serious (AIS-3) left leg and ankle fractures. Upon impact, the right toe pan separated from the floor pan which caused a hole large enough for the case's foot to go through. Her left foot probably contacted the right chassis frame rail as well as the sharp edges of the sheet metal floor. It is unknown whether or not her foot came in contact with any drive train components as the engine and transmission were removed upon inspection. Her left knee loaded the metal glove compartment door. The metal was abraded and tissue deposits were found. Our case sustained an associated left femur fracture as well as severe left tibia/ fibula fractures. There was deformed metal on the middle right instrument panel and our case sustained associated chest abrasions and a left elbow laceration. She also sustained facial lacerations and abrasions, a fractured nose, and closed head trauma as a result of contact to the upper right instrument panel. The plastic was abraded and strands of hair were found on this portion of the instrument panel. The vehicle's "A" pillars were cut and the roof was folded back during the rescue of our

3.	2FRFS2	401101	802.4	Fracture, Right Zygoma	upper left Back of right front seatback
4.	2FLFS2	401101	802.4	Fracture, Left Zygoma	upper left Back of right front seatback
5.	2FIFS2	401101	802.4	Le Fort I Maxillary Fracture	upper left Back of right front seatback
6.	2FRFS2	401101	802.24	Right Angle Fracture of the Mandible	upper left Back of right front seatback
7.	2FRFS1	401101	802.24	Right Ramus Fracture of the Mandible	upper left Back of right front seatback
8.	2FIFS2	401101	802.27	Fracture, Right Aveolar Process	upper left Back of right front seatback
9.	2FILI1	401101	873.43	Lacerations, Left Lower Lip	upper left Back of right front seatback
10.	2RLLI2	572100	881.00	Laceration, Left Forearm 15 cm	upper left Center Console?
11.	2RRLI1	402101	881.00	Laceration, Right Forearm	Back of right front seat?
12.	2RLFS2	402101	813.42	Left Interarticular Distal Radius Fracture	Back of right front seat?
13.	2TRFS3	401201	820.8	Fracture, Right Femoral Neck	Back of right front seatback central
14.	2TRFS3	401201	821.30	Fracture, Right Distal Femur (open, comminuted)	Back of right front seatback central
15.	2LRFS3	401101	823.10	Fracture, Proximal Right Tibia Grade II (open)	Back of right front seatback central
16.	2KRAI1	401101	916.0	Abrasions, Right Knee	Back of right front seatback

					central
17.	2KLAI1	401101	916.0	Abrasions, Left Knee	Back of right front seatback lower left
18.	2LWAI1	401101	919.0	Multiple Abrasions, Lower Extremities	Back of right front seatback lower
19.	2KRLI1	401101	891.0	Lacerations, Right Knee	Back of right front seatback central
20.	2KLLI1	401101	891.0	Lacerations, Left Knee	Back of right front seatback lower left
21.	2LWLI1	401101	894.0	Multiple Lacerations, Lower Extremities	Back of right front seatback lower

PSYCHOSOCIAL TIMELINE - CASE 420

A 77-year-old female was admitted to MIEMSS Shock Trauma after sustaining multiple trauma in a motor vehicle collision in which her husband was the driver. The husband was pronounced dead at the scene. Our case patient was a rear seat passenger and the front seat passenger sustained back injuries and was brought to a local hospital. The front seat passenger was an auto mechanic who was being driven back to the dealership after the car had been serviced. There are concerns whether the driver had medical problems just prior to the crash. The study patient was alert and oriented upon admission and had sustained multiple facial fractures, closed head injury and multi-long bone fractures. Although the patient was responsive to the environment, the patient was unaware of her husband's death and because of her injuries, was endotracheally intubated immediately.

The patient and husband are described by numerous friends as delightful, active, very mentally alert couple, appearing much younger than their years. Both were physically active swimmers and daily walkers with full, well-organized social lives.

The couple had planned to go to the upper Northeast for vacation one week prior to crash, but when ceiling of the apartment fell down, they were required to cancel their trip to supervise repairs. The couple had sold their summer home this past year and this was the first summer that they did not go to the beach.

Although appearing in good health, the husband apparently had a stroke at T - 1 year. The patient and her husband were

active in both Presbyterian and Christian Scientist churches. The patient takes her religion very seriously and rarely would vist a physician. In spite of these beliefs, the patient is cooperative and receptive to medical intervention. Although making a remarkable recovery, the patient feels depressed and saddened and has some difficulty talking. The patient is just beginning to deal with her husband's death and the impact of the loss has not been fully felt due to her own medical status.

The patient is a well educated woman, a writer, active in language clubs, and researcher of old shipping vessels. A spunky lady, the patient is reported to have been a polo player in the 1940's and a staunch supporter of the feline society, having two cats of her own. Her husband, a retired Ivy Leaguer and university professor of mathematics, was also active and on the board of maritime museums and a variety of local art groups.

The patient has no recall of the collision, although remembered taking the mechanic back to work. The patient is overwhelmed by the drastic change in her life and is coping appropriately day by day. Following 22 days of acute care hospitalization at MIEMSS, the patient was discharged to an inpatient rehabilitation facility.

CRASH TIMELINE - CASE 420

T - 3 seconds: This was a single vehicle collision which occurred on a clear weekday morning. The vehicle was a 1989 Ford Escort, Pony, 2 door sedan with an 87 year old male driver, a 23 year old male right front seat passenger, and a 77 year old female right rear seat passenger (our case).

The roadway is a major urban/residential arterial street which has 2 southbound lanes and 2 northbound lanes. The movements are separated by a 25 foot wide curbed grass median, however, in the area of the collision, the southbound lanes curve to the west which increases the width of the grass median. The radius of the curve is approximately 720 feet as measured in the center of the outside southbound travel lane. The roadway is of asphalt construction and has a negative 4 percent southbound vertical slope. The surface was dry at the time of the collision and had an estimated coefficient of friction of .7. The vehicle was southbound in the outside southbound lane and was traveling at an estimated speed of between 38 and 46 miles per hour. The posted speed limit was 30 miles per hour. As the road began curving to the right, the vehicle continued traveling due south and crossed the inside southbound lane.

T - 1.52 seconds: The vehicle impacted and mounted a 6 inch high continuous concrete curb at the east edge of the southbound shoulder. The first wheel to impact the curb was the left front which was followed by the right front, the left rear, and finally the right rear. The vehicle then rolled south across the grass median covering a distance of approximately 81.5 feet from the point of the curb impact.

T - 0: The front of the vehicle impacted a brick "gazebo" type building. The building was rectangular and was supported by a 24 inch diameter, square pillar at each corner. There was a 34 inch high, 6 inch wide concrete wall around the perimeter of the building which connected the pillars. The estimated speed change at impact was 33.9 miles per hour. Maximum longitudinal crush to the front of the vehicle was measured to be 27.2 inches. The brick pillar at the northeast corner of the building was displaced to the south approximately 3 inches (photo 420-16 shows the imprint of this pillar on the front of the vehicle).

All 3 occupants were forced forward at impact. The driver and right front seat passenger were using the available automatic 2 point shoulder belts as well as the available manual lap belts. There was occupant contact to steering rim as evidenced by deformation and clothing fabric deposits on the lower left rim. The driver was reportedly killed at impact, however, the 2 instrument panel contacts made by the right front seat passenger suggest that this passenger was leaning to assist the driver at impact. Due to the driver's age (87), it is possible that the restraint systems contributed to his injuries even though the result would have been much worse had he not used the restraints. The right front seat passenger reportedly sustained incapacitating injuries and was eventually transported to a hospital for treatment.

The right rear seat passenger (our case) was not using the available manual lap belt. Most of our case's injuries were caused by contact to the back of the right front seatback. The seatback was intruded rearward 9.2 inches which indicates that our case may have sustained 2 impacts. The first occurring upon impact with the building, and the second occurring as a result of rearward rebound by the right front front seat passenger. 3 areas of abraded and torn fabric were noted to the vinyl on the back of the right front seat. Our case's head contacted the upper left side of the seatback and she sustained closed head trauma (AIS-2), a small subdural hemorrhage of the falx (AIS-4), 5 AIS-2 facial fractures, 1 AIS-1 facial fracture, and 1 AIS-1 lip laceration. This contact point lies directly over the upper lateral seatback support brace. Our case's right knee contacted the center of the seatback. From this contact point, she sustained AIS-1 abrasions and lacerations to the right knee and leg, an open fracture of the right, proximal tibia (AIS-3), an open, comminuted fracture of the distal right femur (AIS-3), and a right femoral neck fracture (AIS-3). Her left knee contacted the lower left side of the seatback which produced AIS-1 abrasions and lacerations to the left knee and leg. While this contact was centered over the left vertical seatback support brace, the contact appeared to be a glancing blow as our case's left knee slid around the left side of the seatback. Our case also sustained a left forearm laceration (AIS-2), and left interarticular, distal radius fracture (AIS-2). These injuries may have been caused by contact to the center console which was positioned between the front seat cushions. The console was

damaged, but positive occupant contact could not be determined. Our case was eventually transported to a trauma center for treatment.

T + 6 minutes: Police were notified of the collision.

T + 10 minutes: Police arrived at the scene.

PREHOSPITAL AND HOSPITAL TIMELINE - CASE 420

T+ 1min: Ambulance receives call to respond.

T+ 4min: Ambulance arrives at scene. Initial field assessment reveals a blood pressure of 100/palp, a heart rate of 96, a respiratory rate of 12, and a Glascow Coma Score of 12. Prehospital care includes fluid resuscitation with the administration of 1000 cc of crystalloid. The patient required extrication from the vehicle. The MAST suit was applied and inflated.

T+ 60min: Patient departs scene for MIEMSS/Shock Trauma by police medevac helicopter.

T+ 65min: Patient arrives at MIEMSS. Initial physiologic assessment of the patient reveals a Glascow Coma Score of 10. The patient's ISS (Injury Severity Score) = 34. Toxicology screen results were negative. Initial hospital care provided includes:

- -Evalutaion by a MIEMSS trauma team,
- -Fluid resuscitation,
- -Full diagnostic evaluation including x-rays of the cervical spine, chest and pelvis. In addition to the toxicology screen, an arerial blood gas, a CBC (complete blood count), an SMA-6 (routine blood chemistry) and UA (urinalysis) were performed.

Initial clinical findings included the following:

- -Closed head trauma with small subdural hematoma of falx,
- -Bilateral zygomatic fractures,
- -LeForte I maxillary fracture,
- -Right angle/ramus fracture of mandible,
- -Right alveolar process fracture,
- -Right hip fracture,
- -Right distal femur fracture (comminuted, open),
- -Right Grade II proximal tibia fracture,
- -Left interarticular distal radius fracture,
- -Left lower lip lacerations,
- -Left forearm laceration (major),
- -Multiple abrasions and lacerations (superficial) of the lower extremities and knees

Operative care includes:

- -Open reduction with internal fixation of the right mandible and alveolar process fracture,

-External fixation and stabilization of the Right distal femur and proximal tibia fractures,
-Irrigation and dilation of the left forearm laceration,
-Closed reduction, splinting and casting of the left distal radius fracture,
-Open reduction with internal fixation of the Right hip fracture

T+24hours - 27days: Patient spends 17 days in intensive care and 10 days in intermediate care. There were no complications during this patient's acute care phase.

T+ 27 days: Patient discharged from MIEMSS to an inpatient rehabilitation hospital.

COGNITIVE-COMMUNICATIVE ASSESSMENT - CASE 420

The patient was initially evaluated on T + 8 days. The patient was only able to nod "yes"/"no" due to a tracheostomy and mandibular fracture. She was unable to effectively point or write due to upper extremity injuries. Based on the patient's yes/no responses, it was felt that she was functioning at the RLAS (Rancho Los Amigos Score) level of VI. The patient, however, may have been higher. Recommendation was made that she be re-evaluated when she is better able to communicate. Augmentative communication diagnosis and treatment and swallowing diagnosis and treatment was given in the interim. The patient's hearing could not be assessed and she was NPO, or unable to be administered anything by mouth.

The patient was given a discharge evaluation on T + 21 days. She was able to speak and write. All areas assessed (cognitive-communicative) appeared grossly within normal limits. She appeared to have no deficits related to her closed head injury. The patient was felt to be functioning at the RLAS VIII level. No treatment or follow-up was indicated or recommended. The patient had a diagnosed moderate left ear hearing loss and a profound hearing loss in the right ear. The patient was on a P.O. diet at the time of discharge.

PSYCHOSOCIAL FOLLOW-UP - CASE 420

6 Months

Seventy-seven (77)-year-old white female discharged from Shock Trauma following 22 days acute care to inpatient rehabilitation facility where she remained for 2 1/2 months post-trauma. Ambulation progressed slowly and patient continues to use walker and wheelchair. She had many physical setbacks and difficulty with eating, due to problems with teeth as a result of facial fractures. Patient remains at home receiving physical therapy 3 times a week. She has hired a homemaker to assist with household tasks and shopping. She continues to mourn loss of

husband although received support from friends and church.

1 Year

Patient lives alone in apartment and ambulating totally independently without assistance. Her feisty spirit and energy enhanced her full recovery and return to many pre-injury activities such as travel, club work, reading and taking long walks. Patient highly intelligent and coping appropriately over death of husband. Patient has large social network of friends and activities and doing very well.

PREVENTION AND INJURY REDUCTION - CASE 420

This case is interesting in that the case vehicle had been returned to the dealer because it was hard for the owner to steer it. At the time of the collision, a representative of the dealer was in the right front seat, and the owner of the vehicle was "test driving" it after work had been performed. The collision occurred as the result of a failure by the driver to steer the vehicle around a curve. State Police inspected the steering assembly after the crash and found no defects. Since the vehicle was new (807 miles on the odometer), there were probably no wear related steering defects. It is unknown whether or not a manufacturer's defect was present, however, given the fact that the vehicle had been inspected by the dealer, it is unlikely that a defect existed.

A more likely explanation is the fact that the newer, smaller cars often have "stiffer" steering than the traditional full size American sedan. The stiffer steering often feels more accurate to the driver, and some newer models even have variable power assisted steering systems. The idea here is to provide maximum power assist at low speeds, and minimal power assist at highway speeds. This gives the driver a surer feel for the road at highway speeds.

It is possible that the driver in this case was accustomed to a car that steered much easier, and due to his age (87 years), found it hard to steer his new vehicle.

Our Case was sitting in the right rear seat position. At impact, she was forced forward into the right front seatback. Her head contacted the upper left corner of the seatback, and she sustained 9 head/facial injuries up to AIS-4 in severity. While there was some padding on the upper seatback, the surface was still relatively hard. There were impacts from both knees to the central area of the seatback. Our case's left knee contacted the hard siderail on the left side of the seatback, but her knee moved around the left side of the seat which prevented full engagement between her left knee and the seatback. Her right knee fully engaged the center of the seatback just below the relatively unpadded, center, lateral, seatback frame support. She sustained open fractures of the right tibia and femur. Use of the available manual lap belt might have prevented the lower

extremity injuries, and the availability and use of a lap and shoulder belt might have prevented her head and facial injuries as well.

--- Jerry Jackson

COLLISION SCHEMATIC
CASE 420

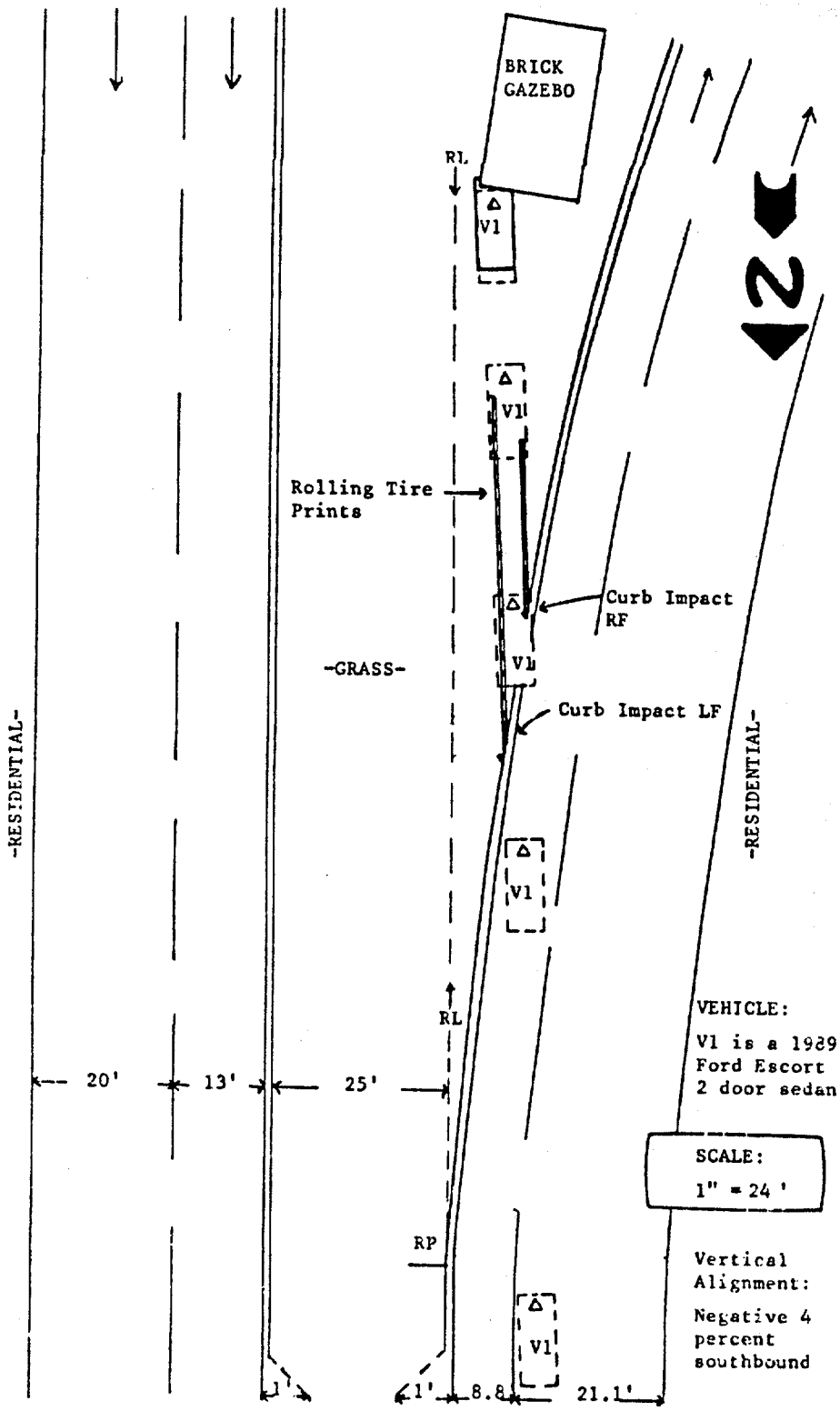

SELECTED PHOTOGRAPHS, CASE 420

1.

Scene. V1 direction of travel. V1 departed roadway to the left and rolled straight into building. Support posts installed later.

2.



Point of impact. Corner pillar moved back 3 inches. 12 o'clock frontal impact. No rotation.

SELECTED PHOTOGRAPHS, CASE 420

3.



V1. 1989 Ford Escort 2 door. Max crush = 27.2 inches. Delta V = 33.9 m.p.h. Note pillar imprint to the sheetmetal.

4.



Right rear seat. Injury source = seatback. AIS-4 head, 5 AIS-2 facial fractures. 3 AIS-3 leg fractures. Case= 77 year old female

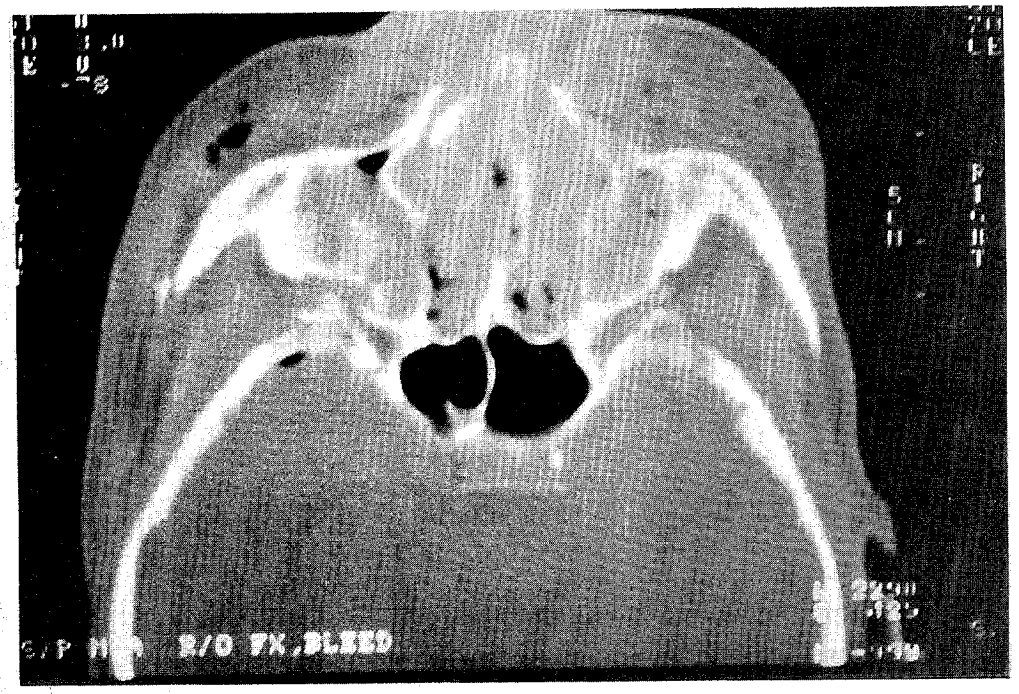

420A CT Scan revealing extensive facial bone fractures including a Left zygomal fracture and bilateral LeForte I maxillary fractures. Both maxillary sinuses are filled with blood.

Contact Point- Back of Right Front seatback (upper left)
Type of Crash- Frontal

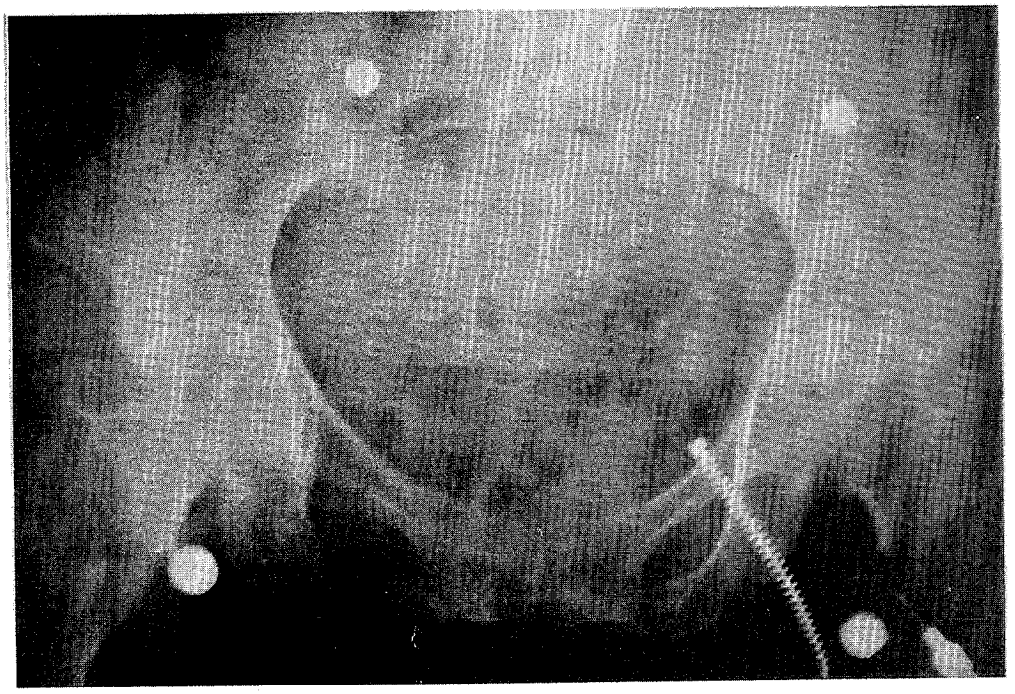

420B X-Ray revealing a right femoral neck fracture.

Contact Point- Back of Right Front seatback (central)
Type of Crash- Frontal

420C X-Ray revealing an open comminuted fracture of the right distal femur.

Contact Point- Back of Right Front seatback (central)
Type of Crash- Frontal

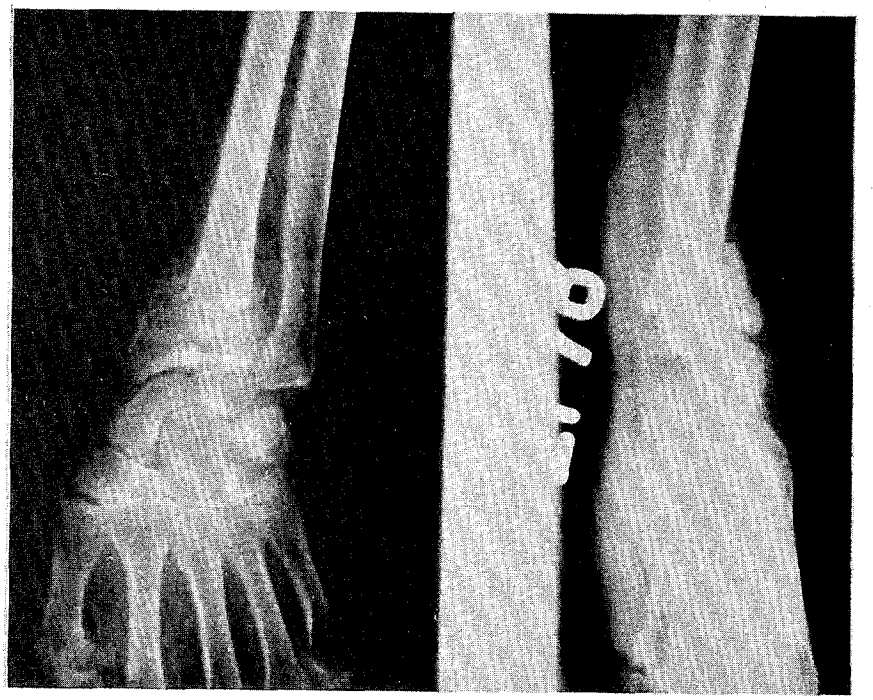

420D X-Ray revealing an interarticular fracture of the left distal radius.

Contact Point- Back of Right Front seatback?
Type of Crash- Frontal

SUMMARY - CASE 312 (029)

This 2 vehicle collision occurred on a clear, summer, weekday afternoon. The collision involved a 1988 Cadillac Coupe de Ville 2 door sedan with one 61 year old female occupant (our case), and a 1989 Jeep Cherokee Laredo 3 door 4x4 truck-based utility with one 48 year old female occupant. The driver of the Cadillac had a poodle dog in her lap. The roadway is a busy suburban collector street which has 1 eastbound lane and 1 westbound lane each approximately 11 feet in width. In the area of the collision, the roadway is curved (curve radius; 768 feet) and the travel lanes are separated by a double yellow paint stripe. The Cadillac was eastbound in the eastbound lane while traveling an estimated speed of between 19 and 25 miles per hour and was negotiating a left-hand curve. The Jeep was westbound in the westbound lane while traveling an estimated speed of between 29 and 35 miles per hour and was negotiating a right-hand curve. The Jeep crossed the double yellow center stripe and impacted the Cadillac head-on in the eastbound travel lane. At impact, the Cadillac was headed approximately 94 degrees to the east of due north and the Jeep was headed approximately 95 degrees to the west of due north. Maximum longitudinal crush to the front of the Cadillac was measured to be 28.7 inches. Maximum longitudinal crush to the front of the Jeep was measured to be 25.4 inches. The estimated speed change at impact was 24 miles per hour for each vehicle. The Cadillac rotated counterclockwise approximately 12 degrees and came to rest about 6.5 feet to the southwest of the impact point. In other words, the Cadillac was pushed rearward at impact (see photograph number 312-03). The Jeep was deflected to the northwest and traveled about 10.8 feet to final rest after approximately 36 degrees of counterclockwise rotation. Both vehicles were towed due to damage. The driver of the Jeep reportedly sustained incapacitating injuries and was transported to a hospital for treatment. The driver of the Cadillac (our case) sustained AIS-1 facial and chest injuries, and AIS-2/AIS-3 lower extremity injuries. Her face and chest area were cushioned from the steering rim by her pet dog. The dog was killed, and our case was transported to a hospital for treatment. A complete list of injuries for this case is included below in OIC format:

BODY CONTACTS AND INJURIES TABLE-CASE 312

61 year old female; Driver; 1988 Cadillac Coupe de Ville; Head-on

OIC/AIS CODE	ICD-9	BODY CONTACTS AND INJURIES	CONTACT POINT
1. 2FRCO1 041201	921.2	Contusion, Right Periorbital Area	Steering Rim/dog
2. 2FILI1 041201	873.43	Laceration, Upper and Lower Lip (left side)	Steering Rim/dog
3. 2SLCI1 041201	923.00	Contusion, Left Clavicle Area	Steering Rim/dog
4. 2CUCI1 041201	922.1	Contusion, Chest	Steering Rim/dog

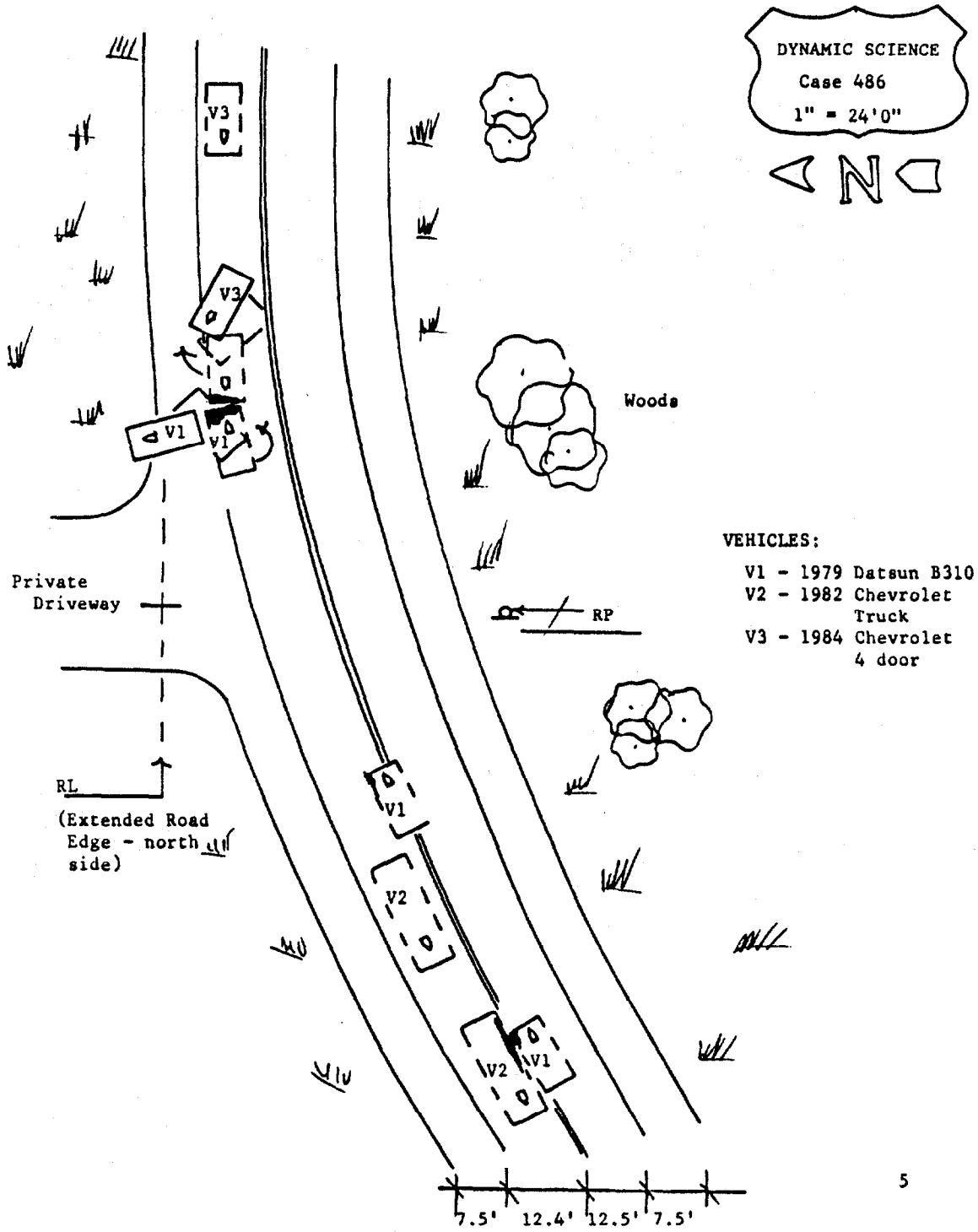
DYNAMIC SCIENCE
Case 486
1" = 24'0"
N
V3
V3
V1
V1
Woods
Private
Driveway
RP
RL
(Extended Road
Edge - north
side)
V1
V2
V2
V1
7.5'
12.4'
12.5'
7.5'
VEHICLES:
V1 - 1979 Datsun B310
V2 - 1982 Chevrolet
Truck
V3 - 1984 Chevrolet
4 door

CRASH TIMELINE - CASE 312

T - 2 seconds: This was a 2 vehicle collision which occurred on a clear weekday afternoon. The collision involved a 1988 Cadillac Coupe de Ville 2 door sedan (V1) with one 61 year old female occupant (our case), and a 1989 Jeep Cherokee Laredo 3 door 4x4 truck-based utility vehicle (V2) with one 48 year old female occupant. The driver of V1 had a poodle dog in her lap. The roadway is a busy suburban collector street which has 1 eastbound lane and 1 westbound lane each approximately 11 feet in width. In the area of the collision, the roadway is curved (curve radius; 768 feet) and the travel lanes are separated by a double yellow paint stripe. The roadway coefficient of friction was estimated at .75 and was adjusted for speed estimates according to the 1 percent superelevation and the positive 3 percent westbound/negative 3 percent eastbound roadway slope. In the area of the collision, the asphalt roadway was dry and had a posted speed limit of 35 miles per hour.

V1 was eastbound in the eastbound lane and was negotiating a left-hand curve. The driver (our case) had a small dog in her lap (or on her shoulder). Our case's seat was positioned close to the steering rim and her left hand was positioned at 9 o'clock on the steering rim. She was using the available manual lap and shoulder belt. V1 was traveling an estimated speed of between 19 and 25 miles per hour. V2 was westbound in the westbound lane and was negotiating a right-hand curve. V2 was traveling an estimated speed of between 29 and 35 miles per hour. The driver was wearing eyeglasses. Her seat was positioned close to the steering rim and she was using the available manual lap and shoulder belt. V2 moved to the left, crossed the double yellow center stripe, and entered the eastbound travel lane. Just prior to impact, V2 was headed 95 degrees to the west of due north and the driver's right foot was on the brake pedal. V1 was headed 94 degrees to the east of due north.

T - 0: The left half of the front of V2 impacted the left half of the front of V1. Maximum longitudinal crush to the front of V1 was measured to be 28.7 inches. Speed change at impact was estimated to be 24 miles per hour. V1's left front wheel was displaced rearward causing 3.6 inches of longitudinal intrusion to the left toepan. The driver (our case) sustained an associated right trimalleolar fracture as she was forced forward at impact. The left instrument panel intruded longitudinally 1.1 inches. Both of our case's knees contacted the left instrument panel. She sustained a fractured left patella and an open fracture of the distal left fibula. The fibula fracture was associated with the downward movement of instrument panel components as the steering assembly intruded downward. Our case loaded the steering wheel at impact as the instrument panel intruded. This combination forced the shear capsule out and allowed the steering column to move downward. Our case's loading of the steering wheel was cushioned by her dog. Animal hair was found embedded in the lower steering rim. Our case sustained a contusion of the right periorbital

area, a laceration to the left side of both lips, and contusions to the chest and left clavicle area. Since the driver's seat was positioned close to the steering assembly, and the dog was between our case and the steering rim, the shoulder belt could not prevent occupant impacts, however, it is possible that the shoulder belt was partially responsible for the chest and left clavicle area contusions. The dog did not survive.

At impact, V2 sustained a maximum longitudinal crush of 25.4 inches. Speed change at impact was estimated at 24 miles per hour. The left toepan intruded longitudinally 7.2 inches and the side panel forward of the "A" pillar intruded laterally 9.5 inches. Since the side panel was positioned in front of the brake pedal after impact, the brake pedal must have been depressed when the intrusion occurred. The brake pedal was deformed from foot contact, however, there was no evidence of pre-impact skidding. This suggests that the right foot of V2's driver reached the brake pedal almost at the instant of impact. The driver's seat was positioned close to the steering rim and there was a heavy left knee impact to the left instrument panel. There was a smudge and some mucous found on the steering hub. The driver's head sprung forward and hit the steering hub as the steering assembly was displaced upward due to impact damage. A pair of broken eyeglasses were found in the vehicle. There was stretched webbing to the driver's shoulder belt and blood on the belt latch. Since there was no blood on the "B" pillar near the blood stained belt latch in its hanging position, and since the blood on the latch corresponded to blood on the driver's seat in the area of the belt anchorage buckle, the manual lap and shoulder belt was confirmed as being in use at the time of collision. The belt may have been worn loosely enabling the driver to contact the instrument panel and steering hub.

T + .72 seconds: V1 was stopped and forced rearward at impact and came to rest 6.5 feet to the southwest of the impact point after approximately 12 degrees of counterclockwise rotation. The driver's door was forced open by rescue personnel and our case was eventually transported to a hospital for treatment. Her dog was found dead on the road near V1. V1 was towed due to damage.

T + .94 seconds: V2 was deflected to the northwest at impact and came to rest 10.8 feet from the impact point after approximately 36 degrees of counterclockwise rotation. The driver was eventually transported to a hospital for treatment and V2 was towed due to damage.

T + 10 minutes: Police were notified of the collision.

T + 12 minutes: Police arrived at the scene.

PREHOSPITAL AND HOSPITAL TIMELINE - CASE 312

T+ 12min: Ambulance receives call to respond.

T+ 17min: Ambulance arrives at scene. Initial field assessment reveals a blood pressure of 120/98, a heart rate of

96, a respiratory rate of 22, and a Glascow Coma Score of 15. Prehospital care includes fluid resuscitation with the administration of 100 cc of crystalloid. The patient required extrication from the vehicle.

T+ 40min: Patient departs scene for MIEMSS/Shock Trauma by ground ambulance.

T+ 58min: Patient arrives at MIEMSS. Initial physiologic assessment of the patient reveals a blood pressure of 170/103, a heart rate of 93, a respiratory rate of 25, and a Glascow Coma Score of 15. The patient's ISS (Injury Severity Score) = 22. Toxicology screen results were negative.

Initial hospital care provided includes:

-Evaluation by a MIEMSS trauma team,
-Fluid resuscitation,
-Peritoneal lavage with negative results,
-Full diagnostic evaluation including x-rays of the cervical spine, chest and pelvis. In addition to the toxicology screen, an arterial blood gas, a CBC (complete blood count), and SMA-6 (routine blood chemistry) and UA (urinalysis) were performed.

Initial clinical findings included the following:

-Right periorbital area contusion and ecchymosis,
-Left lip (upper and lower) laceration,
-Rule out cardiac contusion,
-Left patella fracture,
-Right trimalleolar fracture,
-Left open distal fibula fracture,
-Left clavicular and chest ecchymosis.

Operative care includes:

-Open reduction of right tibia
-Open reduction of left fibula
-Open reduction of left patella

T+24hours - 7 days: Patient spends 2 days in intensive care and 5 days in intermediate care. No complications occurred during the acute care phase for this patient.

T+ 7days: Patient discharged from MIEMSS to home unable to ambulate.

COGNITIVE-COMMUNICATIVE ASSESSMENT - CASE 312

The patient's initial evaluation revealed subtle deficits in comprehension of complex paragraph material. She also had subtle difficulties in reading and following complex directions. The patient's spontaneous speech was appropriate. Deficits were noted in describing complex actions. Vocal skills were intact. the patient achieved a Rancho Los Amigos Score at a level of VIII. Cognitive skills inculding visual discrimination, memory and concentration were intact. Hearing and swallowing were within normal limits.

No speech - language pathology services were recommended as the patient had only mild and resolving deficits.

CRASH COMPARISON - CASE 312

The cases used for comparison are covered in our simulation write up. The simulation engineer retrieved and analyzed the crash curves.

Significance of the Crash:

This accident involved a restrained occupant. Age group 55-64, in which our case fits, use restraints 70% of the time which places them in the top category (70%) except for occupants under age 5. There is only an 18% chance of an injury greater than AIS 1 where drivers are restrained. 82% escape with no injury at all, only 1% are hospitalized and 6% are transported and released. All this would seem to indicate a low incidence of severe injury.

There are other factors involved that acted to increase the chances of severity. Head on accidents are twice as likely to be serious than other accidents and have 43% chance of an AIS >= 1 and a 2% chance of AIS greater than 3. Further, with intrusions of 2 to 4 inches, 66% of the injuries will be AIS >= 1 and 4% AIS >= 3. This is the median group of injuries where there is intrusion of any kind. This lady was apparently saved from even more severe injury by the presence of the dog. The steering wheel is one of the most common producers of serious injury. She was seriously injured by the number 2 producer of serious injury (front interior).

This type of head-on accident is a fairly common occurrence with a high incidence of severe injury. On the other hand, the speed (25 MPH or less) represents the lowest class of all injury producing accidents, a full 16% lower than those at the next group (45-50 MPH).

All things considered, this case was very fortunate to have lowered speed the level she did and to have beeen restrained with a dog in her lap. This seems to give support to the contention that air bags would do a great deal to reduce the severity of injuries (the dog in this case being a surrogate for the air bag).

The conditions of the crash are fairly common. 43% of crashes with a vehicle in transport result in an AIS greater than 1 and head on crashes are two times as likely to result in an AIS greater than three than are crashes at any other angle. As an additional interesting statistic, of the passenger car class, the two door coupe is the most likely configuration of all to be involved in a fatal accident. This accident was not fatal but could very easily have been.

The accident occurred on a suburban collector road with a posted speed of 35 MPH. The Delta V was estimated at under 24 MPH by the accident investigation team. About 27% of all such crashes result in an AIS greater than or equal to 1.

This crash is fairly common and the injury severity is consistent with the conditions of the accident as compared to national statistics.

PSYCHOSOCIAL FOLLOW-UP - CASE 312

6 Months

This 61-year-old married white female discharged from Shock Trauma after 7 days acute care to an inpatient rehabilitation facility where she remained for 4 weeks undergoing physical and occupational therapy. Patient discharged home to continue with outpatient therapy although not fully weight-bearing until 6 months post-trauma at which time patient began to ambulate independently. Patient remained at home with part-time help in caring for self and household. Depression and lack of motivation persist. Patient feels crash was a tremendous shock physically and psychologically and taking longer than anticipated to recover.

1 Year

Patient fully independent in activities of daily living and ambulating without difficulty although tires more easily. Patient had been a "walker" pre-injury, and she returned to this activity 8 months post-trauma which increased her confidence and ability to become more independent. She began to drive a car at 8 months post-trauma and gradually ventured out into the world. Patient feels fully involved in pre-injury activities at 1 year post-trauma but feels it has taken her 1 year to recover to this degree. She continues to have 25% disability in left leg and 15% in right as per orthopedic evaluation.

PREVENTION AND INJURY REDUCTION - CASE 312

This collision occurred in a curve on a 2 lane undivided road. The travel speeds of the 2 vehicles were not causative factors. Both vehicles were traveling at relatively moderate speeds, but one vehicle crossed the centerline of the roadway and entered the opposing traffic lane. Driver inattention might have been the primary causative factor. This factor is possibly the most avoidable yet the most common cause of car crashes.

Our Case was driving with a dog in her lap. Even though the case vehicle did not cross the centerline, the dog may have affected our Case's ability to make appropriate or timely avoidance maneuvers.

The steering column was forced downward at impact. This

caused deformation across the entire lower left instrument panel which contributed to our Case's AIS-3 fibula fracture. Had the lower left instrument panel been constructed in sections so that the center section immediately below the steering column could deform downward, while the areas to the right and left of the column remained intact, our Case's leg might have contacted a padded surface rather than exposed edges.

There was definite evidence that our Case's manual lap and shoulder belt failed to catch. The plastic, headrest mounted, shoulder strap guide showed "melting" due to frictional heat caused by the high speed movement of the shoulder strap through the plastic guide.

Since the dog was fatally crushed against the lower steering rim by our Case, one must review the possible hazards of transporting animals or children without the proper restraint systems. Had this dog been a small child, and no doubt children are often transported in the laps of adults, the consequences might have been even more tragic.

--- Jerry Jackson

COLLISION SCHEMATIC
CASE 312

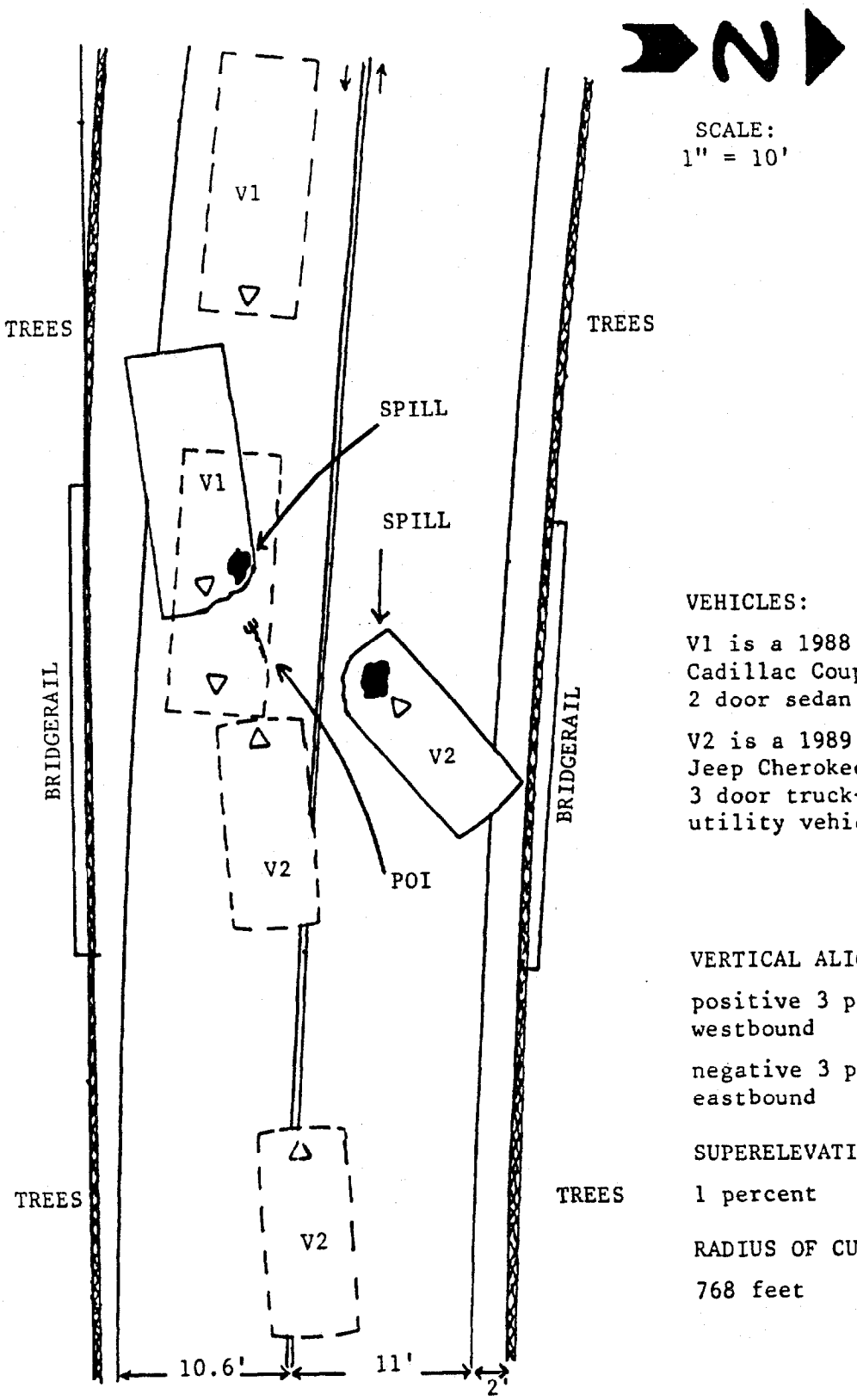

VEHICLES:

V1 is a 1988
Cadillac Coupe de Ville
2 door sedan

V2 is a 1989
Jeep Cherokee Laredo
3 door truck-based
utility vehicle

VERTICAL ALIGNMENT:

positive 3 percent
westbound

negative 3 percent
eastbound

SUPERELEVATION:

1 percent

RADIUS OF CURVE:

768 feet

SELECTED PHOTOGRAPHS, CASE 312

1.

Scene. V2 direction of travel. Curve radius = 768 feet. "X" to right of center stripe = FRP V2. "X" to left is V1 FRP near POI.

2.

V1 (1988 Cadillac Coupe de Ville 2 door). Delta V = 24 m.p.h. Max crush = 28.7 inches. Head-on with front override.

SELECTED PHOTOGRAPHS, CASE 312

3.



V1. Hood caused integrity loss to windshield. Left door damaged during rescue. LF wheel displacement: 3.6" left toepan intrusion.

4.

V1 Driver seat. Steering assembly: shear capsule disengaged, column forced down dislodging lower instrument panel:AIS-3 fibula

SELECTED PHOTOGRAPHS, CASE 312

5.



V1 interior. Dog hair on upper steering rim. AIS-1 face/shoulder/ chest. Right knee contacted inst. panel. Lap & shoulder belt used

6.



V2 (1989 Jeep Cherokee 4x4 Laredo 3 door). Max crush = 25.4". Delta V = 24 m.p.h. LF wheel displaced: Toepan intrusion = 7.2".

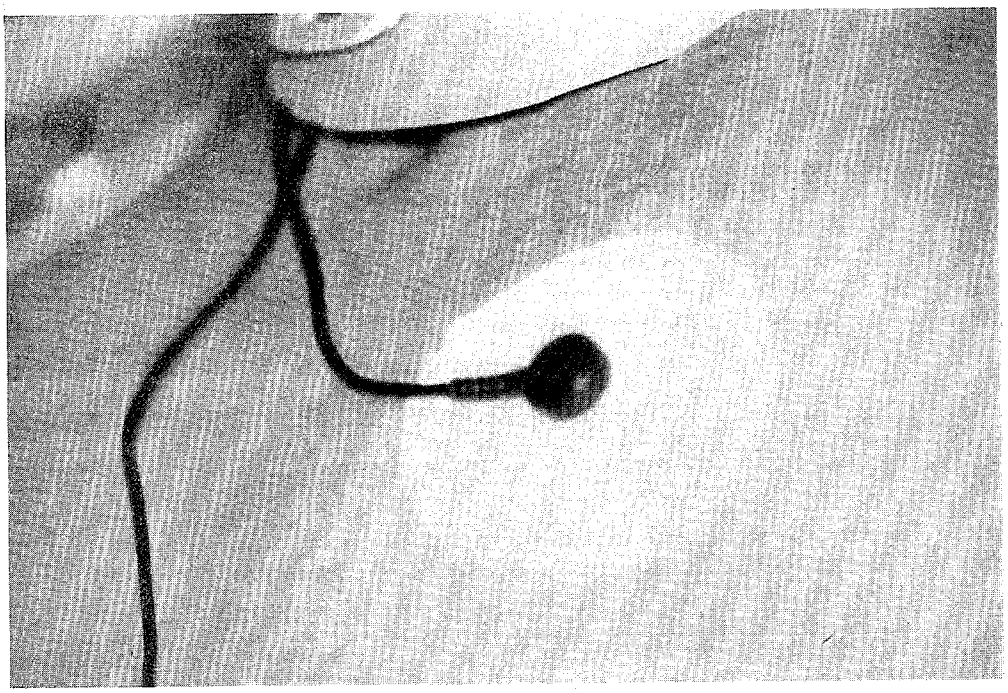

312A Contusion of the left chest and clavicular area. An EKG monitoring pad with lead wire is in the foreground.

Contact Point- Steering Rim and Dog
Type of Crash- Frontal

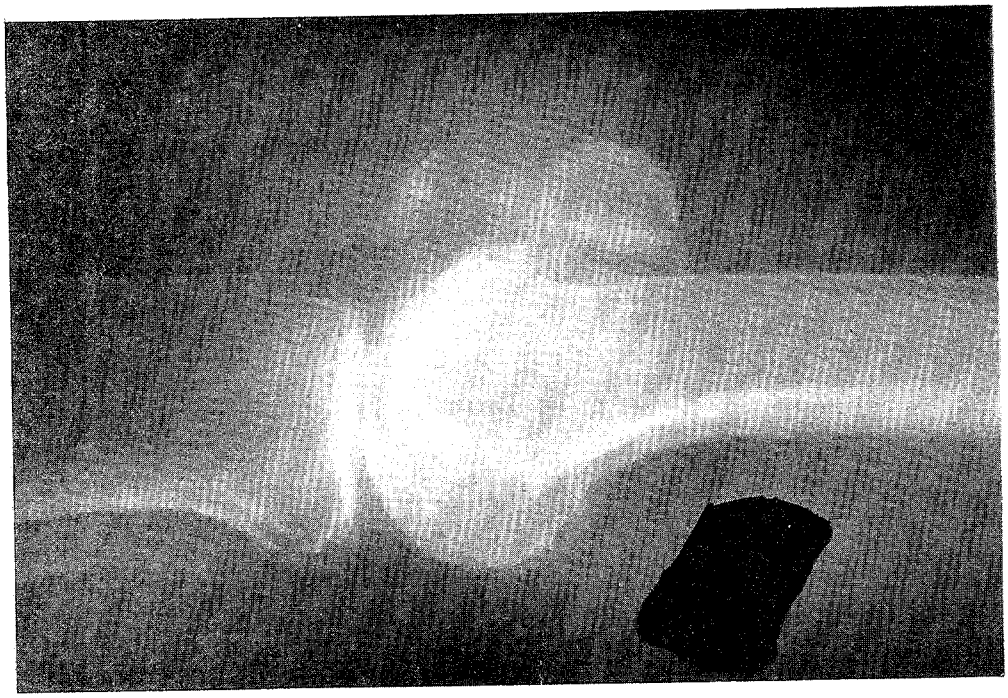

312B X-Ray revealing a fracture of the left patella.

Contact Point- Left Instrument Panel
Type of Crash- Frontal

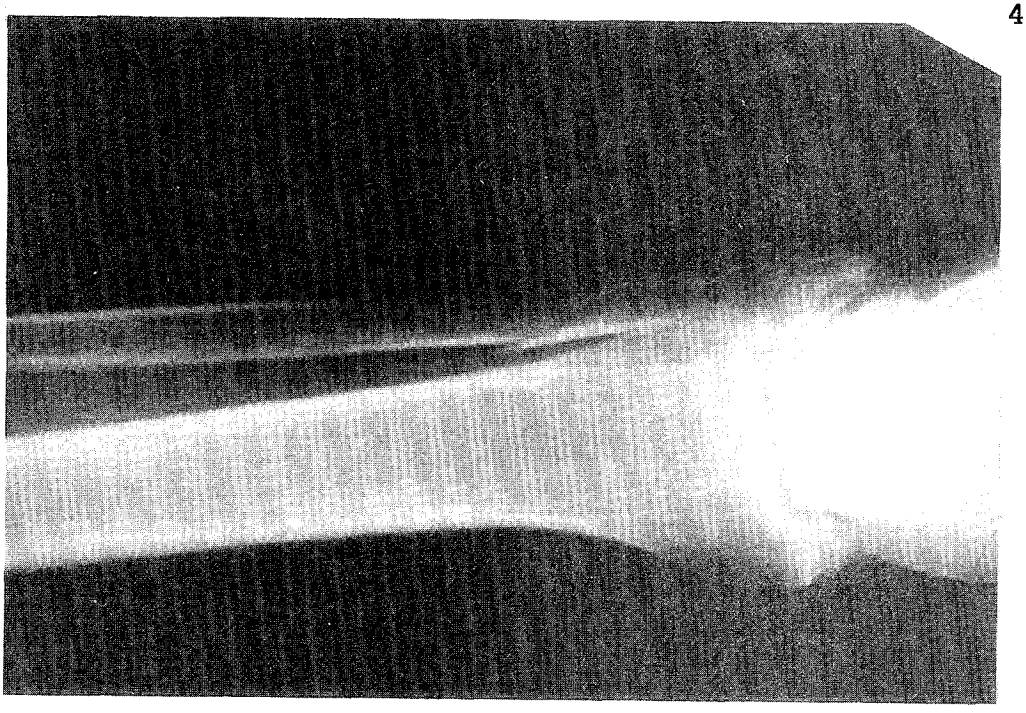

312C X-Ray revealing an open fracture of the left distal fibula.

Contact Point- Left Instrument Panel
Type of Crash- Frontal

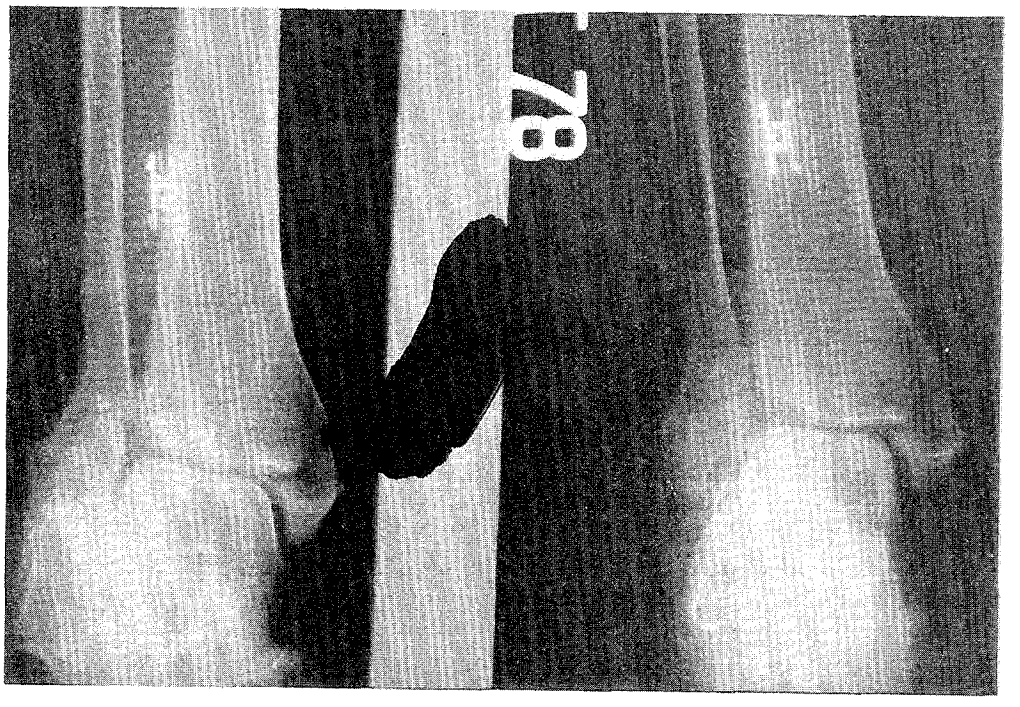

312D X-Ray revealing a triamalleolar fracture of the right ankle.

Contact Point- Left Toepan
Type of Crash- Frontal

SUMMARY - CASE 064 (030)

This two vehicle 90 degree intersection accident occurred during midday, midweek, in the summer. Vehicle 1, a 1980 Oldsmobile Delta 88 4 door sedan was being driven by a 28 year old female northbound at a speed estimated between 64 and 74 miles per hour. The driver of Vehicle 1, the only occupant, was not wearing the available lap/shoulder belt and the Vehicle is not equipped with an air cushion restraint system. Vehicle 2, a 1985 Ford LTD 4 door sedan with four occupants, was being driven eastbound by a 41 year old female at a speed estimated at 35 - 40 miles per hour. Neither the driver nor the three other occupants were wearing the available active restraints and the vehicle is not equipped with an air cushion restraint system. The area in which the accident occurred is a rural wooded area and the traffic density was light. The weather was clear and the roadway is asphalt paved with an estimated coefficient of friction of .65.

The driver of Vehicle 1 failed to stop at a traffic sign prior to entering the eastbound traffic lanes and was struck by Vehicle 2 in the vicinity of the left front wheel. The initial impact produced 67 inches of direct and induced damage and a maximum crush of 21.5 inches. The impact forces involved caused Vehicle 1 and Vehicle 2 to rotate while engaged and produced a total of 205.0 inches of left side damage to Vehicle 1. Vehicle 2 sustained 61.5 inches of direct and indirect damage prior to the vehicle rotating counterclockwise and converting into a right side impact with 183.5 inches of induced and direct damage and a maximum crush of 22.0 inches.

After impact and rotation, Vehicle 1 departed the initial impact and continued a counterclockwise rotating slide to the northeast corner of the intersection and impacted a utility pole in a near broadside slide. This impact produced direct and induced damage of 66.5 inches and a maximum crush of 17.5 inches to Vehicle 1. The damage was located at the right front wheel. The impact forces involved caused Vehicle 1 to rotate approximately 120 degrees and depart in a northeasterly direction rearward and to come to rest 16.9 feet from point of impact #2, facing southwest. Forces involved during the impacts and subsequent rotation caused the driver to be displaced from behind the steering wheel to the rear seating area of Vehicle 1.

Vehicle 2 continued in a counterclockwise rotating skid and slide to final rest facing east southeast on the northeast corner of the intersection. The driver of Vehicle 2 was displaced from the driver's seat across the front seat, struck the windshield and "A" pillar at the extreme right side and was partially ejected out the right front window. The passenger in the right front seat also struck the windshield and "A" pillar on the right side and was pinned in his seat by the driver. The driver (case occupant 054) sustained injuries including a closed head injury with loss of consciousness for more than 15 mins., a subarachnoid hemorrhage, intracerebral bleeding, left thalamic/basal ganglia

hemorrhagic contusion, (highest AIS of 4) and other less severe injuries which are documented in Case 054. Our case DSI-CIT-Case Number 064 sustained multiple severe injuries, the highest being a cardiac contusion, AIS-3. She was transported by helicopter to a major shock trauma hospital and admitted for further treatment. Both vehicles were towed due to damage.

BODY CONTACTS AND INJURIES TABLE-CASE 064
28 year old female; Driver; 1980 Oldsmobile Delta 88; 90 Degree Angle Impact

OIC/AIS CODE	ICD-9	BODY CONTACTS & INJURIES	CONTACT POINT
1. 2FIFS2 221111	802.37	Fractured Mandible	Left "A" pillar
2. 2CLFS2 241100	807.09	Multiple Left Rib Fractures	Combination left side interior surfaces & left side hardware or armrest
3. 2CCCH3 061200	861.01	Cardiac Contusion	Combination steering wheel hub & spoke
4. 2LRFS2 091100	823.00	Right Tibia, Plateau Fracture	Left instrument panel & below
5. 2QRSJ1 971200	845.00	Strain, Right Ankle	Left instrument panel & below

PSYCHOSOCIAL TIMELINE - CASE 064

A 28-year-old married female who was the single occupant/driver of a car in a rural intersection auto collision was admitted to MIEMSS Shock Trauma for multiple trauma. Unsure if she was wearing a seatbelt and having no recall of the accident, the patient was conscious but confused upon admission. Injuries upon presentation included a fractured mandible, fractured ribs, rule out cardiac contusion and other injuries. The patient states that the roadway was unfamiliar to her.

The patient, a married woman and mother of three children ages 3, 7 and 9 years, lives with her husband on her in-laws' farm. The husband works for a painting and roofing company and farms as well. The patient has a high school degree and has been a homemaker for several years. At the time of the accident, the patient was returning from a cleaning job which she

occasionally does during the summer months. The patient states that she had been thinking about some personal thoughts at the time of the collision and attributed this to her lack of recall as well as the fact that she was on an unfamiliar road with high corn fields on either side. The patient initially thought that her children were with her; however they were at a sitter's home. The patient's sister is helping out with their care during the patient's acute care hospitalization.

The patient describes a close-knit family, being the youngest of five children, although all family members, except for one sister, reside out-of-state.

Although the patient denies any particular stressor, she admits to personal and marital concerns and the illness of her mother (cancer) over the past six months. The patient is a non-smoker and denies all use of alcohol or drugs. The patient states that an extended family member is currently being treated for alcoholism.

The patient's primary outside interest other than her family is singing which she does at church and at other public functions.

The patient states that the use of seatbelts is sporadic, although she generally encourages kids to use them. The husband does not wear seatbelts.

The husband, family and friends visit daily and are very supportive of the patient's needs. The patient was discharged at T + 5 days with a full recovery anticipated.

CRASH TIMELINE - CASE 064

T - 02:00 seconds: Vehicle 1, a 1980 Oldsmobile Delta 88, was being driven by a 28 year old female northbound at an estimated speed of between 64 - 74 miles per hour. The driver was not wearing the available lap/shoulder belt, and the vehicle is not equipped with an air cushion restraint system. The northbound roadway is straight asphalt paved and has an estimated coefficient of friction of .65. Vehicle 2, a 1985 Ford LTD 4 door sedan with 4 occupants, was being driven eastbound at a speed estimated at 35 - 45 miles per hour by a 41 year old female. Neither the driver nor the 46 year old male in the right front seat was wearing the available lap/shoulder belt. The 2 rear seat occupants were also not wearing the lap belts available for the rear seating area. The eastbound lane of travel has a curve to the right with a radius of 834.0 feet. The area is rural and the traffic was light at the time of the accident.

T - 0.4 seconds: The driver of Vehicle 1 passed the stop sign controlling her direction of traffic and failed to apply braking action.

T = 0.0 seconds: Vehicle 1 entered the prolongation of the eastbound lanes and was struck in the left front wheel area. This impact produced 67 inches of direct and induced damage and a

maximum crush of 21.5 inches. The forces involved caused both Vehicle 1 and Vehicle 2 to rotate while maintaining full engagement into a conversion impact to the left side of Vehicle 1 and the right side of Vehicle 2. This conversion type impact produced a total of 205.0 inches of direct and induced damage and a maximum crush of 21.5 inches to Vehicle 1 and 185.5 inches of direct and induced damage to Vehicle 2. Vehicle 2 sustained 22.0 inches of maximum crush. Vehicles 1 and 2 separated while rotating counterclockwise. Vehicle 1 slid in a northeasterly direction approximately 62.2 feet in a near broadside slide and impacted a utility pole. Impact forces and intrusion caused by impact number 1 contributed to the fractured mandible as the case occupant moved forward and left into the "A" pillar. Side intrusion at the mid area of the "A" pillar and left door surface caused the multiple left rib fractures. As the case occupant moved forward, she contacted the steering wheel assembly which probably caused the listed cardiac contusion.

T + 1.11 seconds (estimated): Vehicles 1 and 2 had separated and Vehicle 1 entered a near broadside slide impacting a utility pole 62.2 feet northeast of the original impact. The utility pole did not fracture and this impact produced direct and induced damage located at the right front wheel of 66.5 inches and a maximum crush of 17.5 inches. The delta-V was computed at 12.5 miles per hour using the CrashIII-PC. Vehicle 2 was also rotating and sliding to a position of final rest 85.6 feet from point of impact #1.

Forces acting upon an unbelted driver would have caused the driver of Vehicle 1 to move toward the right side of the vehicle. As a result of the impact with the utility pole and resulting rotation, the driver would be displaced right and rearward. This action and contact points on the left and left center lower instrument panel contributed to the fractured right tibia and sprained right ankle.

T + 3.0 - 3.5 seconds: Vehicle 1 rotated approximately 120 degrees at pole impact, departed rearward facing southwest and came to rest after impacting an embankment.

T + .75 - 1:00 minutes: Patrons of a local establishment alerted by the sounds of this impact ran to the vehicles. The driver of Vehicle 1 was found in the rear seating area as a result of impact forces including the rotational forces associated with the clockwise rotation at impact #2 and sudden deceleration while traveling rearward to final rest.

T + 5:00 minutes: The police were notified.

T + 15:00 minutes: The police arrived and started medical and investigative relief efforts.

PREHOSPITAL AND HOSPITAL TIMELINE - CASE 064

T+ 3min: Ambulance receives call to respond.
T+ 6min: Ambulance arrives at scene. Initial field

assessment reveals a blood pressure of 98/60, a heart rate of 54, and a Glascow Coma Score of 14. Prehospital care includes includes fluid resuscitation with the administration of 500 cc of crystalloid. The patient required extensive extrication from the vehicle.

T+ 98min: Patient departs scene for MIEMSS/Shock Trauma by police medevac helicopter.

T+ 110min: Patient arrives at MIEMSS. Initial physiologic assessment of the patient reveals a blood pressure of 116/61, a heart rate of 88, a respiratory rate of 22, and a Glascow Coma Score of 15. The patient's ISS (Injury Severity Score) = 24. Toxicology screen results are negative. Initial hospital care provided includes:

- -Evaluation by a MIEMSS trauma team,
- -Fluid resuscitation,
- -Full diagnostic evaluation including x-rays of the cervical spine, chest and pelvis. In addition to the toxicology screen, an arterial blood gas, a CBC (complete blood count), an SMA-6 (routine blood chemistry) and UA (urinalysis) were performed.

Initial clinical findings included the following:

- -Rule out central mandible fracture,
- -Chin laceration,
- -Alveolar process injury,
- -Multiple left sided rib fractures,
- -Right tibial plateau fracture,
- -Rule out Right ankle fracture with ligamentous injury.

Operative care includes:

- -Open reduction of mandibular fracture
- -Closure of chin laceration.

T+24hours - 5 days: Patient spends one day in intensive care and 4 days in intermediate care. No complications were reported during this patient's acute care hospitalization.

T+ 5 days: Patient discharged from MIEMSS to home unable to ambulate.

COGNITIVE-COMMUNICATIVE ASSESSMENT - CASE 064

The patient's cognitive- communicative skills were initially assessed on T + 4 days. The patient was completely oriented and had no complaints about concentration skills or memory other than not being able to recall the collision. Results of the evaluation indicated functional and appropriate auditory comprehension, written comprehension, verbal expression, written expression, speech, cognitive and hearing skills. Hearing and swallowing were both within normal limits. No further follow-up was indicated and the patient was discharged from speech-language pathology services.

PSYCHOSOCIAL FOLLOW-UP - CASE 064

6 Months

Patient, a married homemaker, discharged to home with physical therapy following 5 days acute hospitalization. She has not returned to any type work at 3 months post-trauma. Financial impact undetermined and patient reports her life has returned to pre-injury status although she continues to exhibit a slight limp and notices problems with memory and concentration. Family had not yet retained a lawyer although patient recognizes she speeded through intersection, impacting other vehicle, killing driver. Patient retains strong religious outlook which has helped her cope with trauma and aid in her recovery.

1 Year

Patient has made full recovery and continues in her homemaker/mother role, working part-time. Patient has returned to pre-injury activities. Financial impact has been small.

CRASH AND INJURY PREVENTION IDEAS - CASE 064

This accident occurred primarily because the driver "ran a stop sign" at a high rate of speed. An electronic warning device, as part of a "smart highway" would have made this driver aware that the sign was there and no speed reduction was being made. Automatic seat belts and air cushion restraint systems would have restrained the driver and probably reduced her injuries by keeping her protected within the driver's area.

It is noted that with the present electronic engine controls, and present roadside telecommunications capabilities, it is possible to have roadside speed signs transmit a maximum speed capability for passing vehicles, and even stop signs which initiate an automatic stop sequence.

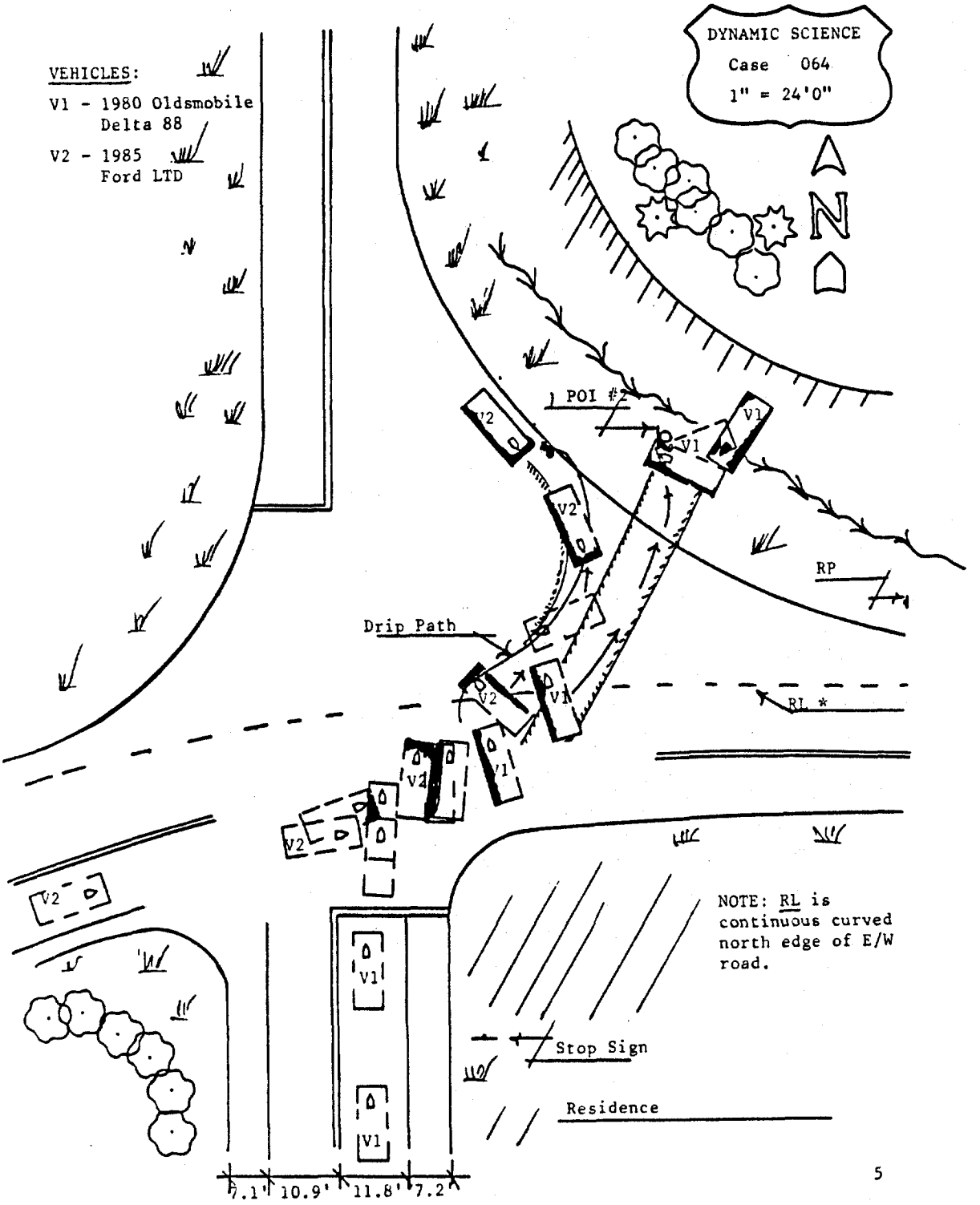
DYNAMIC SCIENCE
Case 064
1" = 24'0"
N
VEHICLES:
V1 - 1980 Oldsmobile Delta 88
V2 - 1985 Ford LTD
POI #2
RP
Drip Path
RL *
NOTE: RL is continuous curved north edge of E/W road.
Stop Sign
Residence
7.1'
10.9'
11.8'
7.2'

SELECTED PHOTOGRAPHS, CASE 064

064-02

1.

Scene - V1 approach path to point of impact #1 at intersection, CCW rotation and skidding to POI #2 with telephone pole at right.

2.



Scene - Close up of skidding to site of impact #2 with telephone pole and V1's final rest position in the ditch.

SELECTED PHOTOGRAPHS, CASE 064

3.



V1; 1980 Oldsmobile Delta 88; #1 impact w/V2 caused 21.5" max. crush to left front wheel; indirect & induced damage of 67".

4.



Impact #2 w/utility pole caused direct & induced damage of 66.5" with maximum crush of 17.5" at right front wheel.

SELECTED PHOTOGRAPHS, CASE 064

5.



V1 unbelted driver contacted steering wheel hub/spoke sustaining cardiac contusion (AIS-3) & other injuries as driver was displaced from behind steering wheel to rear seating area.

6.



V2; 1985 Ford LTD - 61.5" direct and induced damage to left side prior to rotating CCW & damaging right side. (see Case 054).

NOTE:

No Injury Photographs
Available For This Case

SUMMARY - CASE 054 (031)

This two vehicle 90 degree angle intersection accident occurred during midday, midweek, in the summer.

Vehicle 1, a 1985 Ford LTD 4 door sedan with four occupants, was being driven eastbound by a 41 year old female at a speed estimated at 35 - 40 miles per hour. Neither the driver nor the three other occupants were wearing the available active restraints and the vehicle is not equipped with an air cushion restraint system. Vehicle 2, a 1980 Oldsmobile Delta 88 4 door sedan, was being driven northbound at a speed estimated between 64 and 74 miles per hour by a 28 year old female. The driver of V2, the only occupant, was not wearing the available lap/shoulder belt and the vehicle is not equipped with an air cushion restraint system. The area in which the accident occurred is a rural wooded area and the traffic density was light. The weather was clear and the roadway is asphalt paved with an estimated coefficient of friction of .65.

The driver of Vehicle 2 failed to stop at a traffic sign prior to entering the eastbound traffic lanes and was struck by Vehicle 1 in the vicinity of the left front wheel. The initial impact produced 67 inches of direct and induced damage and a maximum crush of 21.5 inches. The impact forces involved caused Vehicle 1 and Vehicle 2 to rotate while engaged and produced a total of 205.0 inches of left side damage to Vehicle 2. Vehicle 1 sustained 61.5 inches of direct and induced damage prior to the vehicle rotating counterclockwise and converting into a right side impact with 183.5 inches of induced and direct damage and a maximum crush of 22.0 inches.

After impact and rotation, Vehicle 2 departed the initial impact and continued a counterclockwise rotating slide to the northeast corner of the intersection and impacted a utility pole in a near broadside slide. This impact produced direct and induced damage of 66.5 inches and a maximum crush of 17.5 inches to Vehicle 2. The damage was located at the right front wheel. The impact forces involved caused Vehicle 2 to rotate approximately 120 degrees and depart in a northeasterly direction rearward and to come to rest 16.9 feet from point of impact #2, facing southwest. Forces involved during the impacts and subsequent rotation caused the driver to be displaced from behind the steering wheel to the rear seating area of the vehicle. Vehicle 2's delta-V at impact #1 was computed using the damage only algorithm of Crash PC as 18.5 miles per hour and 12.5 miles per hour for impact #2.

Vehicle 1 continued in a counterclockwise rotating skid and slide to final rest facing east southeast on the northeast corner of the intersection. The driver of this vehicle was displaced from the driver's seat across the front seat, struck the windshield at the extreme right side and was partially ejected out the right front window. The passenger in the right front seat also struck the windshield and was pinned in his seat by the driver. Vehicle 1's delta-V was computed at 15 miles per hour.

The reported closed head injuries, maximum AIS-5, consisting of a subarachnoid hemorrhage, intracerebral bleeding, and left thalamic/basal ganglia hemorrhagic contusion were sustained as impact and rotational forces projected the case occupant (driver) forward and to the extreme right where contact points indicate the windshield, right "A" pillar and right front door, glass and frame were struck. There is a high probability that the exterior left side of Vehicle 2 was also contacted during partial ejection of the driver of this Vehicle. The facial lacerations sustained by the case occupant were consistent with rearview mirror and metal frame contacts noted to the right side of the vehicle and the broken glass on the left side of Vehicle 2. The upper right and left extremity lacerations would confirm that both flying and fixed glass contact were made. The lower extremity injuries were sustained as the occupant was thrown forward and upward contacting the lower steering rim and being displaced toward the right and contacting the lower center radio console. The driver of Vehicle 2 (case ocupant 064) was also thrown from behind the steering wheel into the rear seat sustaining multiple rib fractures, an alveolar fracture and a cardiac contusion, maximum AIS-3. The drivers of Vehicle 1 and Vehicle 2 were transported by helicopter to a major shock trauma hospital and admitted for further treatment. Both vehicles were towed due to damage.

BODY CONTACTS AND INJURIES TABLE-CASE 054

41 year old female; Driver; 1985 Ford LTD; 90 Degree Angle Impact

OIC/AIS CODE	ICD-9	BODY CONTACTS & INJURIES	CONTACT POINT
1. 2HWKB5 151100	845.05	Closed Head injury w/loc > 24 hrs.	1. Windshield including 1 or more of the following: front header, "A" pillar, instrument panel, rear view mirror, right door, including glass & exterior left side of other vehicle during rotation & partial ejection.
2. 2HUUB3 151100	852.05	Subarachnoid hemorrhage	
3. 2HUUB4 151100	853.05	Intercerebral bleeding (SIC)	
4. 2HLUB4 151100	851.05	Left thalamic/basal ganglia hemorrhagic contusion	
5. 2HRLI2 781100	873.0	Right frontal-parietal full thickness cruciform laceration	2.Combination right side window glass/

6.	2HRLI2	781100	873.0	Right temporo-occipital full thickness laceration	frame side surface on left side of other vehicle.
7.	2FRLO2	781100	873.40	Right partial thickness orbital laceration	
8.	2HRLI2	781100	873.0	Right full thickness mastoid laceration	
9.	2HRLE1	781100	872.01	Right pinna laceration	
10.	2XRLI2	781100	884.0	Multiple right upper extremity lacerations	
11.	2XLLI2	781100	884.0	Multiple left upper extremity lacerations	
12.	2TRCI2	061100	924.00	Large right hematoma, femoral, prominence	Combination steering wheel rim, hub/spokes
13.	2KRLJ2	101100	891.0	Right knee, laceration	Center lower instrument panel
14.	2LRCI2	101100	924.10	Large right shin contusion	

PSYCHOSOCIAL TIMELINE - CASE 054

A 41-year-old married female was admitted to MIEMSS Shock Trauma after sustaining massive head trauma in a collision in which she was the unbelted driver of a car with three other passengers. The patient's husband was the front-seat passenger and the patient's son and his girlfriend were in the rear-seat. The husband was hospitalized at a local hospital due to a fractured ankle and leg injury and subsequently released after refusing knee surgery. The crash occurred in a rural roadway intersection and involved another vehicle which was supposedly speeding. The patient was driving a rental vehicle which had handicap license due to her husband's previous leg injury resulting from a falling tree at T - 7 months. At the time of the crash, the patient was driving her husband and son back to work after having lunch at home.

The patient is described as a strong woman, very altruistic, who has endured past crises, mst recently the death of her youngest son to cancer at age 18. The family had made numerous trips to a local hospital for the son's treatment. The patient chose to die at home and died at T- 18 months.

The patient is an only child, having a sister who died when she was age 15. Prior to the injury, the patient worked as a geriatric aide and was involved in numerous charity drives and organizations. The patient is a strong believer in organ donation as evidenced by a car sticker- "Kidney Donors Save Lives." She is an avid gardener and mother of two sons, ages 19 and 22. Her husband is currently unemployed due to his leg injury and in the process of applying for social services. At the

time of injury, the patient and the son's girlfriend had worked at a nursing home, a job which she had obtained at T - 2 days due to a layoff at a former job.

The family had relocated to the present area at T - 4 months and were still in the process of getting settled and obtaining jobs. Neither the son nor husband is able to return to work at this time at a small college where they were employed as groundskeepers. The son's girlfriend, although receiving minor injuries, nevertheless feels unable to work due to severe headaches.

The patient is a non-smoker, although her husband and brother-in-law have a history of drinking problems, as did the son. Both state that they have received treatment for problems; however the husband admitted getting drunk at T - 1 month.

The family is very open, verbal and sharing, keeping a daily diary where they all enter their thoughts and feelings. The family describes the patient as the mainstay of the family and the glue that held them all together. The mother was the one who was health and safety conscious and always doing for others, from taking in runaway teens, court-adjudicated adolescents and stray animals. The patient is described as a fighter and lady with perseverance who worked hard, even taking a tractor to work during a rural snowstorm, and coping with son's death, providing him with a dignified and personal death.

The family has kept together through past crises and presents as, "We can do it together and we will." However, the family may have difficulty viewing the situation realistically and would benefit from ongoing counselling and support.

CRASH TIMELINE - CASE 054

Vehicle 1, a 1985 Ford LTD 4 door sedan with 4 occupants, was being driven eastbound at a speed estimated at 35 - 45 miles per hour by a 41 year old female. Neither the driver nor the 46 year old male in the right front seat was wearing the available lap/shoulder belt. The 2 rear seat occupants also were not wearing the lap belts available for the rear seating area. The eastbound lane of travel has a curve to the right with a radius of 834.0 feet. The roadway is paved asphalt and has a coefficient of friction estimated as .65. The area is rural and the traffic was light at the time of the accident.

T - 02:00 seconds: Vehicle 2, a 1980 Oldsmobile Delta 88, was being driven northbound by a 28 year old female at an estimated speed of between 64 - 74 miles per hour. The driver was not wearing the available lap/shoulder belt, and the vehicle is not equipped with an air cushion restraint system. The northbound roadway is straight, asphalt paved, and has an estimated coefficient of friction of .65.

T - 0.4 seconds: The driver of Vehicle 2 passed the stop sign controlling her direction of traffic and failed to apply braking action.

T = 0.0 seconds: Vehicle 2 entered the prolongation of the eastbound lanes and was struck in the left front wheel area by Vehicle 1. This impact produced 67 inches of direct and induced damage and a maximum crush of 21.5 inches. The forces involved caused both Vehicle 1 and Vehicle 2 to rotate while maintaining full engagement in to a conversion impact to the right side of Vehicle 1 and the left side of Vehicle 2. This conversion type impact produced a total of 205.0 inches to Vehicle 2 and 185.5 inches of direct and induced damage to Vehicle 1. Vehicle 1 sustained 22.0 inches of maximum crush. Vehicles 1 and 2 separated while rotating counterclockwise. Vehicle 2 slid in a northeasterly direction approximately 62.2 feet in a near broadside slide and impacted a utility pole. Scene evidence indicates the driver of Vehicle 1 took no evasive action prior to impact. At impact, the unbelted driver of Vehicle 1, (our case occupant) moved forward, deforming the steering wheel rim to a near horizontal position and as the vehicle rotated counterclockwise, was displaced toward the right side of her vehicle. Contact points along this path of displacement contributed to her contusion in the right femoral area, right knee laceration and right shin contusion. Impact and rotational forces involved as Vehicle 1's frontal impact further enhanced the case occupant's displacement and contact points indicate she struck the rear view mirror, windshield on the passenger side and right "A" pillar. These contact points probably caused our case occupant's closed head trauma consisting of loss of consciousness greater than 24 hours, subarachnoid hemorrhage, intracerebral bleeding and left thalamic/basal ganglia hemorrhagic contusion. Multiple lacerations to the head, face and upper right and left extremities probably were sustained during partial "ejection" and contact with the left side glass of Vehicle 2.

T + 1.11 seconds (estimated): Vehicles 1 and 2 separated and Vehicle 2 entered a near broadside slide impacting a utility pole 62.2 feet northeast of the original impact. Vehicle 1 rotated an additional 270 degrees while sliding 85.6 feet to the northeast corner coming to final rest facing approximately east. At impact #2, (Vehicle 2 and the utility pole) the utility z0e did not fracture and this impact produced direct and induced damage located at the right front wheel of 66.5 inches and a maximum crush of 17.5 inches. The delta-V was computed at 12.5 miles per hour using the
CrashIII-PC.

T + 3.0 - 3.5 seconds: Vehicle 2 rotated approximately 120 degrees at pole impact, departed rearward facing southwest and came to rest after impacting an embankment.

T + .75 - 1:00 minutes: Patrons of a local establishment, alerted by the sounds of this impact, ran to the vehicles. The driver of Vehicle 2 was found in the rear seating area as a result of impact forces including the rotational forces associated with the counterclockwise rotation at impact #2 and sudden deceleration while traveling rearward to final rest. The driver of Vehicle 1 was found hanging head down over the right

front door/lower window frame.

T + 5:00 minutes: The police were notified.

T + 15:00 minutes: The police arrived and started investigative and medical relief efforts.

PREHOSPITAL AND HOSPITAL TIMELINE - CASE 054

T+ 3min: Ambulance receives call to respond.

T+ 11min: Ambulance arrives at scene. Initial field assessment reveals a blood pressure of 90/70, a heart rate of 78, a respiratory rate of 24, and a Glasgow Coma Score of 3. Prehospital care includes the placement of an esophogeal obturator airway and the application and inflation of MAST. The patient required extrication from the vehicle.

T+ 64min: Patient departs scene for MIEMSS/Shock Trauma by police medevac helicopter.

T+ 88min: Patient arrives at MIEMSS. Initial physiologic assessment of the patient reveals a blood pressure of 140/80, a heart rate of 136, a respiratory rate of 21, and a Glasgow Coma Score of 3. The patient's ISS (Injury Severity Score) = 40. Toxicology screen results were negative.

Initial hospital care provided includes:

- -Evaluation by a MIEMSS trauma team,
- -Fluid resuscitation,
- -Diagnostic peritoneal lavage with slightly positive results,
- -Full diagnostic evaluation including x-rays of the cervical spine, chest and pelvis. In addition to the toxicology screen, an arterial blood gas, a CBC (complete blood count), an SMA-6 (routine blood chemistry) and UA (urinalysis) were performed. The patient aslo underwent head CT Scan.

Initial clinical findings included the following:

- -Closed head trauma with intracerebral bleed of the basal ganglia and subarachnoid
- -Brainstem contusion
- -Two large lacerations of the right temporo-occipital area

Operative care included:

- -Tracheostomy
- -Placement of (Intracerebral Pressure Monitor) ICP Monitor.

T+24hours - 42 days: Patient spends 42 days in intensive care. Complications developed during the acute care phase include: pneumonia, pulmonary failure, sepsis on the 6th day, adult respiratory distress syndrome on the 26th day, and multiple organ failure on the 41st day.

T+ 42 days: Patient expired.

PSYCHOSOCIAL FOLLOW-UP - CASE 54

No follow-up. Patient expired 40 days post trauma.

CRASH AND INJURY PREVENTION IDEAS - CASE 054

This accident occurred because another vehicle ran a stop sign at a high rate of speed. An electronic sensing device, "Smart Highway", would have detected the lack of speed reduction and warned the driver, who appeared pre-occupied, of the probability of failing to stop. Automatic seat belts would have restrained the case driver and reduced her injuries. The combination of air cushion restrain systems and automatic belts probably would have eliminated the sustained injuries. In several cases, the height-weight ratio of the driver or occupants may have contributed to their lack of belt usage. The lap/seat belt combination made for the average person can be very uncomfortable for those who are apreciably larger or smaller than the norm.

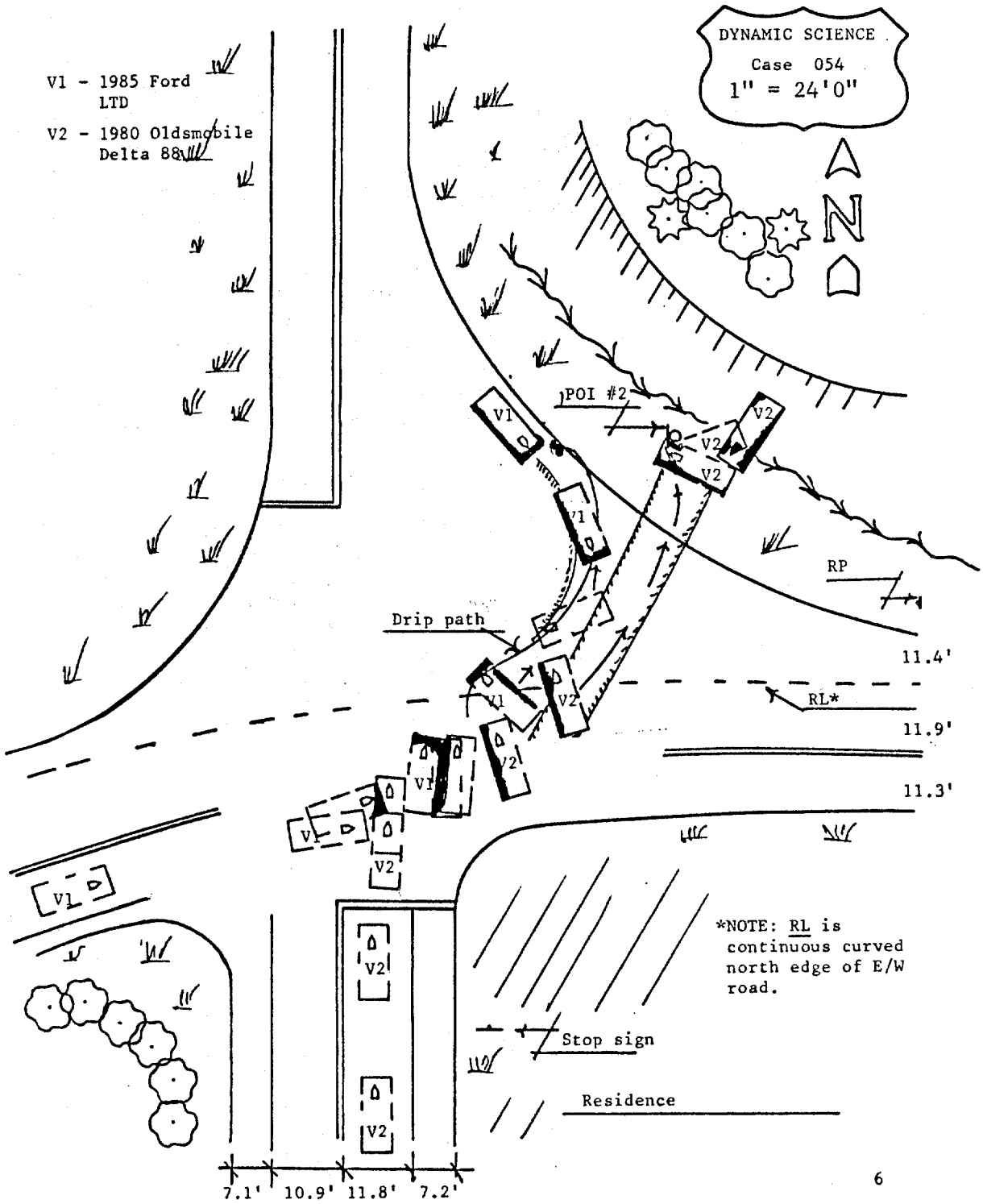
DYNAMIC SCIENCE
Case 054
1" = 24'0"
N
V1 - 1985 Ford LTD
V2 - 1980 Oldsmobile Delta 88
POI #2
RP
Drip path
RL*
11.4'
11.9'
11.3'
*NOTE: RL is continuous curved north edge of E/W road.
Stop sign
Residence
7.1'
10.9'
11.8'
7.2'

SELECTED PHOTOGRAPHS, CASE 054

1.

V1 approach path to point of impact at intersection.

2.

V1's point of impact with V2, counterclockwise rotation marks veering left and final rest position (V1).

SELECTED PHOTOGRAPHS, CASE 054

3.



V2-1980 Oldsmobile Delta 88; #1 impact w/V2-21.5" max crush to left front wheel; direct & induced damage of 67". (See Case 064)

4.



V1-1985 Ford LTD; #1 impact - 61.5" direct & induced damage, rotated CCW, converted to right side impact w/183.5" direct and induced damage, max crush 22.0".

SELECTED PHOTOGRAPHS, CASE 054

5.

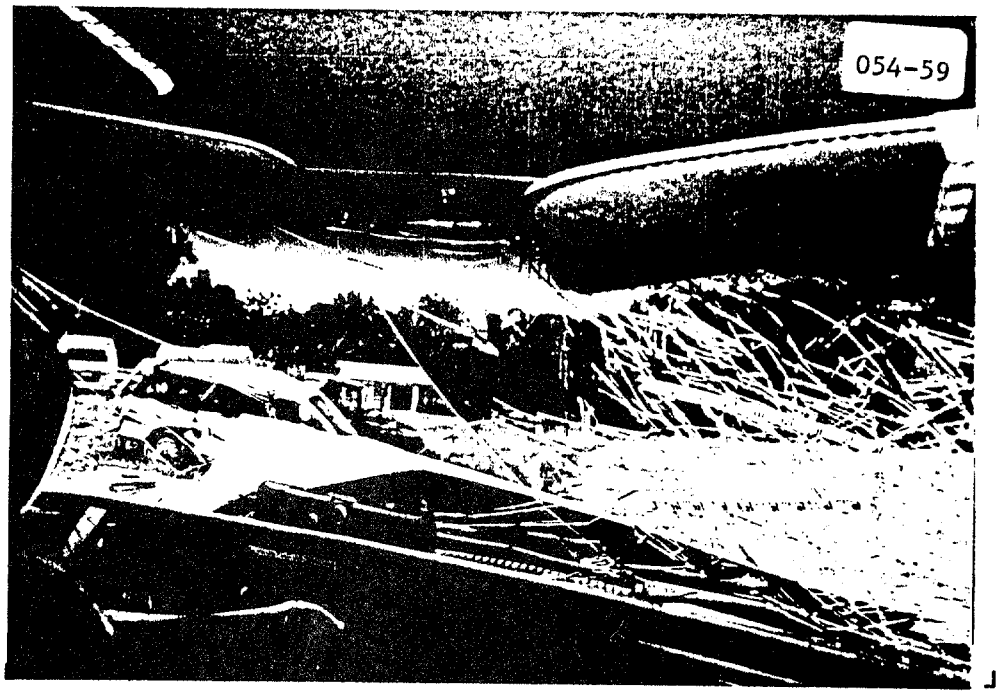

V1 unbelted driver was displaced across front seat contact windshield sustaining closed head injury w/loc > 24 hrs (AIS-5),

6.



contacting other locations sustaining less severe injuries and was partially ejected out right front window. (see steering wheel position in photo #5).

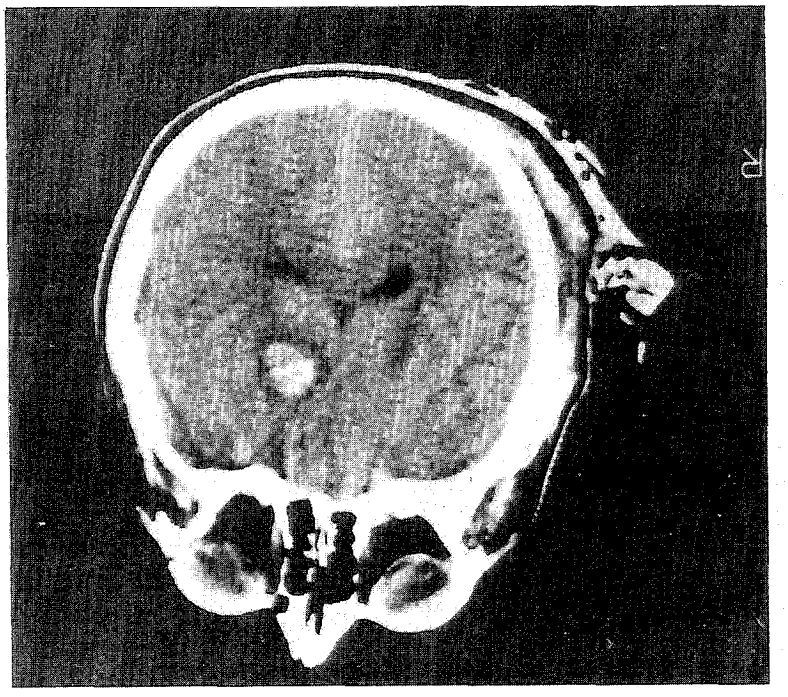

054A CT Scan revealing an intercerebral hemorrhage.

Contact Point- Windshield including 1 or more of the following: front header, "A" pillar, instrument panel, rear view mirror, right door, including glass and exterior left side of other vehicle.
Type of Crash- Frontal

054B Laceration of the right forehead and temporo-occipital area. The patient has been cervicallly immobilized with a Philadelphia collar. The patient has been endotracheally intubated and is being ventilated by a respirator.

Contact Point- Combination right side window glass/frame & side surface on left side of other vehicle.
Type of Crash- Frontal



054C Right elbow laceration and multiple forearm abrasions.

Contact Point- Combination right side window glass/frame & left side surface of other vehicle.
Type of Crash- Frontal

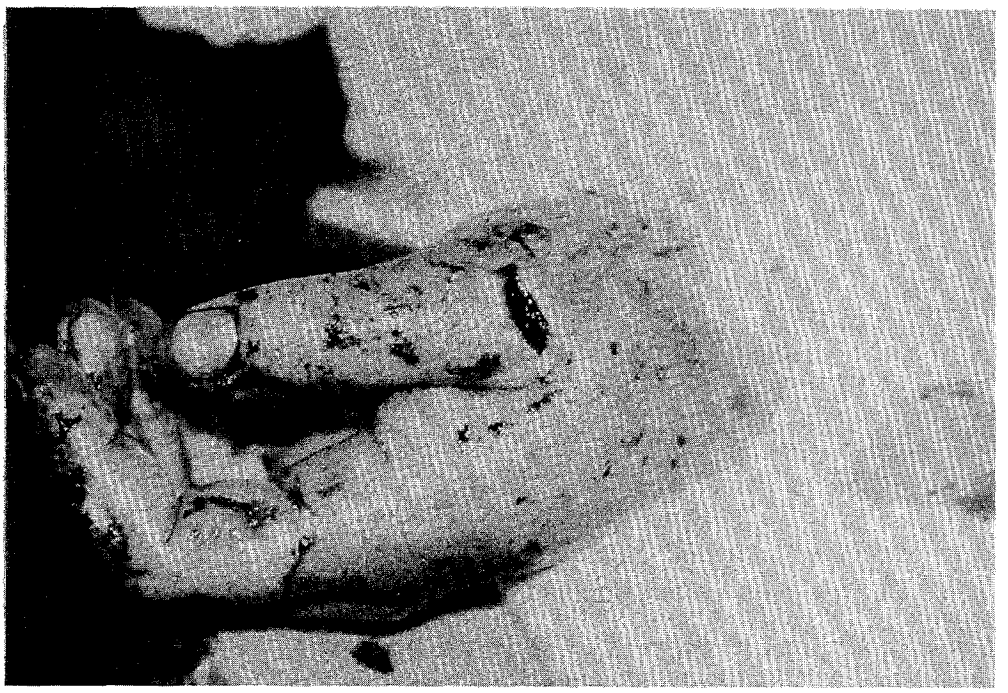

054D Laceration of the left thumb and multiple abrasions of the left hand.

Contact Point- Combination right side window glass/frame and left side surface of other vehicle.
Type of Crash- Frontal

SUMMARY - CASE 107 (032)

This two vehicle accident occurred on a clear weekday in the summer. The roadway is a 4 lane asphalt paved U.S. route and has an estimated coefficient of friction of .70. The traffic was moderate and the area is rural/business. Vehicle 1, a 1985 Chrysler Fifth Avenue, was being driven northbound at an estimated speed of 50 - 55 miles per hour by a 53 year old male. The driver, our case occupant, was not wearing the available lap/shoulder belt and the vehicle is not equipped with an air cushion restraint system. Vehicle 2, a 1988 Chevrolet C2500 crew cab pickup towing a large utility trailer, was being driven southbound at an estimated speed of 50 - 55 miles per hour by a 25 year old male. Neither the driver nor the three other occupants were wearing the available lap/shoulder belts and this vehicle is not equipped with an air cushion restraint system.

The driver of Vehicle 1 apparently did not see or misjudged Vehicle 2's approach speed and turned left across lane 2, entering the prolongation of southbound lane 1. The driver of Vehicle 2 took evasive action consisting of full braking with lockup/skidding and turning left. This action was unsucessful and Vehicle 2 struck Vehicle 1, frontal plane to right side. This impact produced 142.0 inches of direct and induced damage and a maximum crush of 19.5 inches to Vehicle 1. Damage to Vehicle 2 consisted of 61.0 inches of direct and induced damage and 27.75 inches of maximum crush. At impact, Vehicle 1 rotated counterclockwise and was pushed in front of Vehicle 2 approximately 23 feet to its final rest position facing east, straddling the west curb. Vehicle 2 continued sliding 53 feet to its final rest. Impact and rotational forces caused the unbelted driver to be displaced toward the right side of Vehicle 1. Intrusion occurring during the impact and contact by the case to the right side door and door hardware probably caused the right fractured rib and right posterior liver lobe laceration. Multiple lacerations to the case occupant's right arm were attributed to the broken glass from the right passenger window and windshield.

The case was treated at the scene, transported by ambulance to a major shock trauma hospital and admitted for further treatment. His vehicle was towed from the scene due to damage. The four occupants in Vehicle 2 were reported as having possible injuries. Vehicle 2 was also towed from the sscene due to damage.

BODY CONTACTS AND INJURIES TABLE-CASE 107
53 year old male; Driver; 1985 Chrysler 5th Avenue;
front to right side collision

OIC/AIS CODE	ICD-9	BODY CONTACTS & INJURIES	CONTACT POINT
1. 2CRFS1 371113	807.01	1st right rib fracture	Right side interior surfaces including hardware
2. 2MRLL5 371113	864.03	Laceration, R/posterior lobe of liver	

3.	2XRLI1 911113	881.0	Multiple R/arm lacerations	Glass (R/window and windshield)

CRASH TIMELINE - CASE 107

T - 5:00 Seconds: Vehicle 1, a 1985 Chrysler 5th Avenue, was being driven northbound on a 4 lane undivided U.S. route at a speed estimated at 50 - 55 miles per hour. The driver, a 53 year old male, was not wearing the available lap/shoulder belt and the vehicle is not equipped with an air cushion restraint system. Vehicle 2, a 1988 Chevrolet C2500 Crew Cab pickup truck, was being driven southbound at a speed estimated at 50 - 55 miles per hour. Neither the driver nor the right front seated passenger was wearing the available lap/shoulder belts. This vehicle is not equipped with an air cushion restraint system and was towing an equipment trailer with a total estimated weight of 2500 pounds. The roadway is asphalt paved, located in an urban area, and has an estimated coefficient of friction of .70. The weather was clear; the roadway was dry and traffic was moderate.

T - 2:00 Seconds (estimated): The driver of Vehicle 1 decelerated in lane 2 and started turning left across the southbound lanes.

T = 0:0 Seconds: Vehicle 1 had decelerated to an estimated 35 - 40 miles per hour, crossed lane 2 and entered the prolongation of lane 1 southbound traffic. The driver of Vehicle 2 had taken evasive action by applying brakes and turning right. The action was not successful and Vehicle 2 impacted the right side of Vehicle 1 frontal plane Vehicle 2 to right side plane of Vehicle 1. At impact, Vehicle 1 sustained intrusion in the vicinity of the "A" pillar. At impact, the forces involved displaced the unbelted Vehicle 1 driver from behind the steering wheel towards his vehicle's right side. This movement would have been magnified by the 2:1 weight difference and Vehicle 2's stiffness. This difference combined with a near 90 degree impact angle also contributed to Vehicle 1 being lifted and carried to its final rest position. Contact points indicated that the intrusion of the right side door and door hardware contributed to the case occupant's right 1st rib fracture and right posterior liver lobe laceration. The multiple right arm lacerations were caused by the fractured windshield and right side glass.

T + 1.4 Seconds (estimated): Vehicle 2 pushed/carried Vehicle 1 in a clockwise rotating movement to its final rest position straddling the curb facing east.

T + 2.4 Seconds (estimated): Vehicle 2 struck the west curb while sliding to final rest. The final rest position of Vehicle 2 was parallel and against the west curb facing south.

T + 1:00 Minutes: The police were notified.

T + 4:00 Minutes: The police arrived and started investigative and medical relief efforts.

PREHOSPITAL AND HOSPITAL TIMELINE - CASE 107

T+ 1min: Ambulance receives call to respond.

T+ 5min: Ambulance arrives at scene. Initial field assessment reveals a blood pressure of 160/100, a heart rate of 80, a respiratory rate of 15, and a Glascow Coma Score of 15. Prehospital care includes fluid resuscitation with the administration of 400cc of crystalloid. The patient required extrication from the vehicle.

T+ 31min: Patient departs scene for MIEMSS/Shock Trauma by ambulance.

T+ 45min: Patient arrives at MIEMSS. Initial physiologic assessment of the patient reveals a blood pressure of 164/89, a heart rate of 95, a respiratory rate of 28, and a Glascow Coma Score of 15. The patient's ISS (Injury Severity Score) = 18. Toxicology screen results were negative. Initial hospital care provided includes:

- -Evaluation by a MIEMSS trauma team,
- -Fluid resuscitation,
- -Diagnostic peritoneal lavage with positive results,
- -Full diagnostic evaluation including x-rays of the cervical spine, chest and pelvis. In addition to the toxicology screen, an arterial blood gas, a CBC (complete blood count), an SMA-6 (routine blood chemistry) and UA (urinalysis) were performed.

Initial clinical findings included the following:

- -First right-sided rib fracture
- -Laceration of the right posterior lobe of liver (>5 cm in length)

Operative procedures include:

- -Repair of liver

T+24hours - 23 days: Patient spends 4 days in intensive care and 19 days in intermediate care. No complications occurred during the patient's acute care phase.

T+ 23days: Patient discharged from MIEMSS to home.

COGNITIVE-COMMUNICATIVE ASSESSMENT - CASE 107

The patient was initially evaluated on T + 8 days. The patient was repeatedly amnesic for the accident but did not have a diagnosis for a closed head injury. The primary diagnosis included lacerations of the liver and rib fractures. The patient's cognitive- communicative skills appeared within normal limits. Hearing was assessed and a mild-moderate left-sided hearing loss was detected. Swallowing skills were within normal limits. A Rancho Los Amigos Score was not assigned to the patient due to the lack of closed head injury. The patient was discharged from this service and no follow-up is indicated.

PSYCHOSOCIAL FOLLOW-UP - CASE 107

6 Months

Patient remains separated from wife and living with girlfriend whose phone number unavailable. Wife reports patient back to work part-time.

1 Year

Unable to locate patient.

CRASH AND INJURY PREVENTION IDEAS - CASE 107

This case exhibits some of the characteristic symptoms of driver inattention. The driver of Vehicle 1 either misjudged or never saw the approach of Vehicle 2. No environmental or man-made restrictions exist at the accident location. Continuing education at the time of relicensing of drivers as to the need to continuously check traffic situations may have helped. This condition also could have been corrected with an onboard computer warning system such as most aircraft are equipped with. While the cost of electronic equipment is high, modern technology exists that would have warned this driver of the approaching vehicle's speed as he turned his vehicle into its path. Since he would have had to respond to this warning, given his lack of attention at the time of the accident, even this system may not have solved the problem -- driver inattention. Had this driver been restrained by an automatic restraint system, the probability is very high he would have escaped serious injury. Current standards will take care of this in new cars, but to my knowledge, nothing is being done for older cars or resold cars.

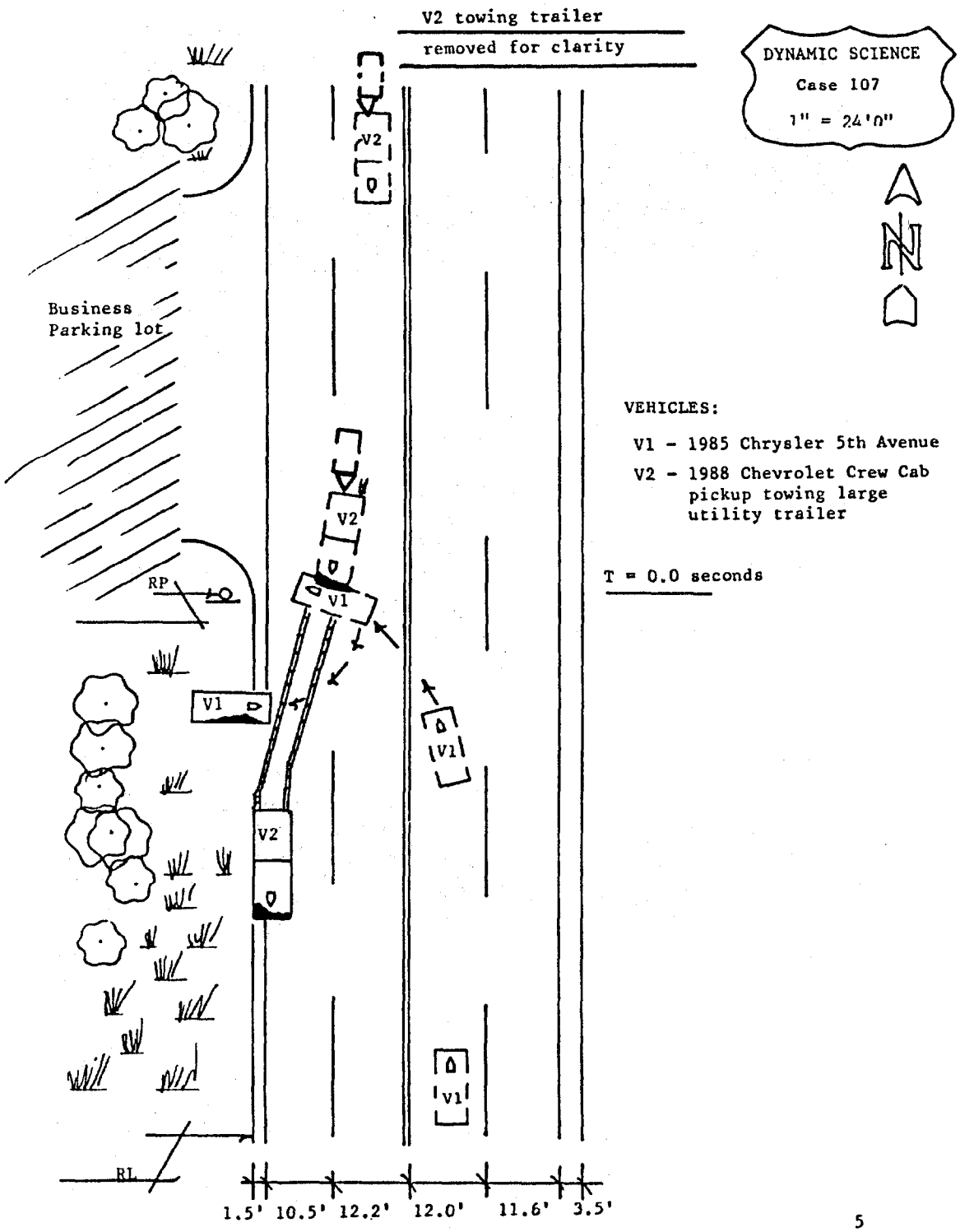
V2 towing trailer
removed for clarity
DYNAMIC SCIENCE
Case 107
1" = 24'0"
N
Business
Parking lot
RP
RL
V1
V2
VEHICLES:
V1 - 1985 Chrysler 5th Avenue
V2 - 1988 Chevrolet Crew Cab pickup towing large utility trailer
T = 0.0 seconds
1.5'
10.5'
12.2'
12.0'
11.6'
3.5'

SELECTED PHOTOGRAPHS, CASE 107

1.

Scene photograph showing northbound approach of V1. Apparently V1 turned left into path of southbound vehicles.

2.



Southbound path; V1 and V2 point of impact. V1 rotated counter-clockwise and was pushed 23 feet to final rest position.

SELECTED PHOTOGRAPHS, CASE 107

3.



V1; 1985 Chrysler Fifth Avenue. Maximum crush 19.5". Direct and induced damage, 142.0". 90 degree side impact.

4.



V2; 1988 Chevrolet C2500 Crew Cab pickup towing large utility trailer. 61.0" direct & induced damage; no interior damage.

SELECTED PHOTOGRAPHS, CASE 107

5.

Unbelted V1 driver was displaced across front seat sustaining AIS-3 injuries of 1st right rib fracture and laceration

6.



of right posterior lobe of liver when he contacted right side interior surfaces & also sustained multiple right arm lacerations from contact with right window and windshield glass.

NOTE:

No Injury Photographs
Available For This Case

SUMMARY - CASE 080 (033)

This single vehicle collision occurred on a clear, summer, weekday afternoon. The vehicle was a 1984 Chevrolet Celebrity 2 door sedan with one 57-year-old male occupant (our case). Our case was positioned in the driver's seat and was not using the available manual lap and shoulder belt.

The roadway is a major, asphalt, interstate highway which has 3 northbound lanes and 3 southbound lanes each approximately 12 feet in width. The movements are divided by an 85.4 foot wide sloped grass median. The posted speed limit is 55 miles per hour, and in the area of the collision, the roadway has a curve radius of approximately 5,625 feet. At the time of the collision, the roadway was dry and had no apparent defects.

Just before losing control, the Chevrolet was southbound in the outside southbound lane at an estimated speed of between 66 and 70 miles per hour. The Chevrolet began counterclockwise rotation, crossed the middle and inside southbound lanes, and entered the grass median. The vehicle traveled southeast across the median while correcting its counterclockwise yaw. It then rolled across the northbound lanes and continued traveling southeast down a negative 25 percent grassy slope east of the roadway. The Chevrolet impacted a barbed wire fence which ran parallel to and 42 feet to the east of the roadway. The vehicle then rolled south over the fence for an additional 42.2 feet before impacting and coming to rest against a 7.5 inch diameter tree. Maximum longitudinal crush to the front of the Chevrolet was measured to be 36.9 inches. Estimated speed change at impact was 29.5 miles per hour. The driver's toepan intruded 8.5 inches and as a result, our case sustained 4 AIS-2 lower extremity fractures. He also sustained 2 other AIS-2 lower extremity fractures and 1 AIS-3 pelvic fracture from the left instrument panel. He was transported to a trauma center for treatment and the vehicle was towed from the scene due to damage. A complete list of injuries for this case is included below in OIC format:

BODY CONTACTS AND INJURIES TABLE-CASE

57 year old male; Driver; 1984 Chevrolet Celebrity; Frontal impact

OIC/AIS CODE	ICD-9	BODY CONTACTS AND INJURIES	CONTACT POINT
1. 2FILI1 042100	873.43	Laceration, Left Lower Lip	Steering rim?
2. 2PLZJ3 092200	808.0	Fracture, Left Transverse Posterior Acetabulum and..	Instrument panel
	835.01	Dislocation	left knee load?
3. 2LRFS2 091100	823.00	Fracture, Right Tibial Plateau	Instrument panel left
4. 2LRFS2 091100	823.01	Fracture, Proximal Head Right Fibula	Instrument panel left
5. 2LLFS2 561201	823.82	Fracture, Left Distal Tibia	Toepan

6.	2LLFS2 561201	823.82	Fracture, Left Fibula	Toepan
7.	2QLFS2 561101	824.8	Fracture, Left Ankle Pilon	Toepan
8.	2QRFS2 561101	825.0	Fracture, Right Calcaneus	Toepan

PSYCHOLOGICAL TIMELINE - CASE 080

Brief Crash and Injury Summary:

This is a 57 year old white male admitted to Shock Trauma with multiple extremity fractures after the car in which he was the only occupant went out of control. The patient was unbelted and the vehicle in question was a 1985 Celebrity. Patient felt the steering "went out", he crossed a grassy median strip and opposite lanes, impacting into a tree at approximately 60+ mph. The patient was awake, alert, and able to recall details of crash although unsure of why or how crash occurred, as it was early afternoon on a clear day. At the time of crash, patient was had been driving some 7 hours and was enroute to the airport where he intended to fly to his destination due to severe back pain.

CRASH TIMELINE - CASE 080

T - 10 seconds: This was a single vehicle collision which occurred on a clear weekday afternoon. The vehicle was a 1984 Chevrolet Celebrity 2 door sedan (V1) with one 57 year old male occupant (our case). Our case was positioned in the driver's seat and was not using the available manual lap and shoulder belt. The roadway is a major asphalt interstate highway which has 3 northbound and 3 southbound lanes each approximately 12 feet in width. The movements are divided by an 85.4 foot wide sloped grass median. The median is sloped at 19 percent with the lowest point being in the center of the median. The posted speed limit 55 miles per hour, and in the area of the collision, the roadway has a curve radius of approximately 5,625 feet. At the time of the collision, the roadway was dry and had no apparent defects. V1 was southbound in the outside southbound lane at an estimated speed of between 66 and 70 miles per hour.

T - 8.79 seconds: V1 began counterclockwise rotation and crossed the center and inside southbound lanes and the inside southbound shoulder. After approximately 93 feet of lateral skidding, V1 departed the southbound lanes to the east as its counterclockwise rotation gradually increased. V1's speed upon departing the southbound lanes was estimated at between 48 and 52 miles per hour.

T - 7.72 seconds: V1 entered the sloped grass median and slid to the southeast for approximately 100 feet. As V1 slid, the counterclockwise rotation was corrected. Upon departing the grass median, V1's estimated speed was between 30 and 34 miles per hour.

T - 6.07 seconds: V1 rolled to the southeast across the

inside northbound shoulder, the inside, center, and outside northbound travel lanes, and the outside northbound shoulder. There was no evidence of braking by the driver of V1. V1 was traveling an estimated speed of between 29 and 33 miles per hour as it departed the east road edge.

T - 3.38 seconds: V1 rolled across and down the grassy slope to the east of the roadway. This was a 25 percent negative grade. V1 traveled approximately 107.8 feet to the southeast. Just prior to the first impact, V1 was traveling an estimated speed of between 28 and 32 miles per hour.

T - .97 seconds: V1 contacted a barbed wire and mesh fence. This impact caused scratching of the paint to V1's entire left side. This impact had very little effect on V1's forward velocity, however, the impact did cause a slight counterclockwise rotation. V1 continued south for approximately 42.2 feet. At this point V1 was traveling an estimated speed of between 27 and 31 miles per hour.

T - 0: V1 impacted a 7.5 inch diameter tree. Maximum longitudinal crush to V1's front bumper was 36.9 inches. Estimated speed change at impact was 29.5 miles per hour. The principal direction of the force acting on V1 was from approximately 10 degrees to the right of straight ahead (driver's perspective). At impact, the left toepan intruded longitudinally 8.5 inches. The driver (our case) sustained associated right calcaneus, left ankle pilon, and distal left tibia/fibula fractures. Our case also sustained proximal right tibia/fibula fractures and a fracture and dislocation of the left transverse posterior acetabulum (knee loading). These injuries resulted from contact by both knees to the left instrument panel. Our case sustained a left lower lip laceration which was probably due to steering rim contact, however, the upper steering rim was removed by rescue personnel. The driver's door was also removed by rescue personnel. The "A" pillars were cut and the roof was folded back at the "B" pillars, and the windshield was also removed for rescue. Additionally, the rescue team used a chain to alter the position of the steering column. V1 came to rest while still fully engaged with the tree.

T + 30 seconds: Police were notified of the collision.

T + 10 minutes: Police arrived at the scene.

PREHOSPITAL AND HOSPITAL TIMELINE - CASE 080

T+ 5min: Ambulance receives call to respond.

T+ 13min: Ambulance arrives at scene. Initial field assessment reveals a blood pressure of 100/palp., a heart rate of 90, a respiratory rate of 18, and a Glascow Coma Score of 15. Prehospital care includes fluid resuscitation with the administration of 1500cc of crystalloid. The patient required extrication from the vehicle.

T+ 58min: Patient departs scene for MIEMSS/Shock Trauma by police medevac helicopter.

T+ 77min: Patient arrives at MIEMSS. Initial physiologic assessment of the patient reveals a blood pressure of 129/95, a heart rate of 111, a respiratory rate of 16, and a Glascow Coma Score of 15. Toxicology screen results were negative. The patient's ISS (Injury Severity Score) = 21.

Initial hospital care provided includes:

- -Evaluation by a MIEMSS trauma team,
- -Fluid resuscitation,
- -Diagnostic resuscitation with negative results,
- -Full diagnostic evaluation including x-rays of the cervical spine, chest and pelvis. In addition to the toxicology screen, an arterial blood gas, a CBC (complete blood count), an SMA-6 (routine blood chemistry) and UA (urinalysis) were performed.

Initial clinical findings included the following:

- -Left lower lip laceration
- -Rule out cardiac contusion
- -Left acetabular transverse posterior fracture with dislocation
- -Left distal tibia- fibular fracture
- -Right tibial plateau fracture
- -Right proximal head fibular fracture
- -Right calcaneal fracture
- -Left ankle pilon fracture

Operative care includes:

- -Open reduction/internal fixation of right tibia
- -Open reduction/internal fixation of left tibia
- -Open reduction/internal fixation of left fibula

T+24hours - 30 days: Patient spends 17 days in intensive care and 13 days in intermediate care.

T+ 30 days: Patient discharged from MIEMSS to an in-state rehabilitation hospital.

COGNITIVE-COMMUNICATIVE ASSESSMENT - CASE 080

The patient was initially evaluated on T + 8 days. The patient had a positive loss of consciousness but did not have a diagnosed closed head injury. Primary diagnosis included multiple lower extremity injuries. The patient's cognitive-communicative skills appeared within normal limits. Hearing was assessed and a mild-moderate bilateral hearing loss was diagnosed. Swallowing skills were within normal limits. As the patient had no diagnosed closed head injury, no Rancho Los Amigos score was assigned. The patient was discharged from this service and no follow-up is indicated.

CRASH COMPARISON - CASE 080

The cases used for comparison are covered in our simulation write up. The simulation engineer retrieved and analyzed the crash

curves.

Significance of the Crash:

We have no information on this case. A case history was not received and the timeline file is no longer available.

PSYCHOSOCIAL FOLLOW-UP - CASE 080

6 Months

Patient discharged to inpatient rehabilitation facility 29 days post trauma. He remained at inpatient rehabilitation only 7 days as unable to participate in therapy program due to extent of injuries and was discharged home, out-of-state. Patient remains at home 6 months post trauma with home physical therapy 3 times weekly. He is unable to ambulate independently and can only take a few steps from bed to chair. Patient uses wheelchair around house although has not been outside. Patient's son plans to build ramp for patient to increase his mobility. Patient's casts removed at 3 months; although continuing with range of motion exercises, patient is in constant pain.

Wife having difficulty caring for patient due to his dependence and demands as well as her own poor health.

Medical follow-up and rehabilitation needed. However, as patient resides out-of-state follow-up difficult. Medical referral indicated.

Patient has no health insurance coverage at present, preventing in-hospital care or rehabilitation. Insurance was terminated prior to hospitalization at Shock Trauma and costs continue to be outstanding. Family has delayed in making medical assistance application and at 6 months still has not done so, awaiting outcome of workmen's compensation settlement. Costs exceed $77,299 not including transportation to home state, physical therapy, attendant care by wife, follow-up medical care, medications and home modification and equipment.

1 Year

Patient continues to live with son and his family, totally wheelchair bound and dependent in activities of daily living. Despite numerous attempts to seek VA care, all efforts unsuccessful. Family and patient describe life as nightmare since crash. Patient depressed and angry, as is family, about lack of treatment and appropriate care. Patient has not yet received any Social Security benefits. Patient doing poorly.

PREVENTION AND INJURY REDUCTION - CASE 080

The reason that the driver of V1 lost control of his vehicle could not be determined. He was diabetic, and it is possible that he had a mild seizure that affected his state of awareness. This

type of seizure was the primary cause of case 088 which occurred on a similar highway and involved a similar control loss situation. In both cases 080 and 088, a vehicle crossed the median strip and entered opposing traffic at highway speeds. A barrier in the median strip would have prevented the vehicle from entering opposing traffic, and in this case, a barrier impact might have produced less serious injury to our Case than the tree impact did. Given V1's rotation as it departed the southbound lanes, a frontal impact with a barrier located just to the east of the inside southbound shoulder would have caused V1's right side to rotate into, and sweep southward against the barrier.

As it happened, it is pure luck that V1 crossed the opposing lanes of a heavily traveled, high speed, interstate highway, on a weekday afternoon without contacting another vehicle.

A "Net" barrier might be a good idea for median strip installations. Aircraft carriers have used Net barriers for years to catch disabled aircraft as they land. A Net barrier would certainly be easier to install than the concrete Jersey barrier, at least from the perspective of the amount of heavy machinery needed to carry out the installation. The Net barrier would also be easier to replace and maintain.

The real advantage of a Net barrier with respect to its ability to protect people is that it would greatly increase the time during energy dissipation at impact. This of course reduces the forces which are acting on a vehicle occupant at any one instant.

--- Jerry Jackson

COLLISION SCHEMATIC, CASE 080

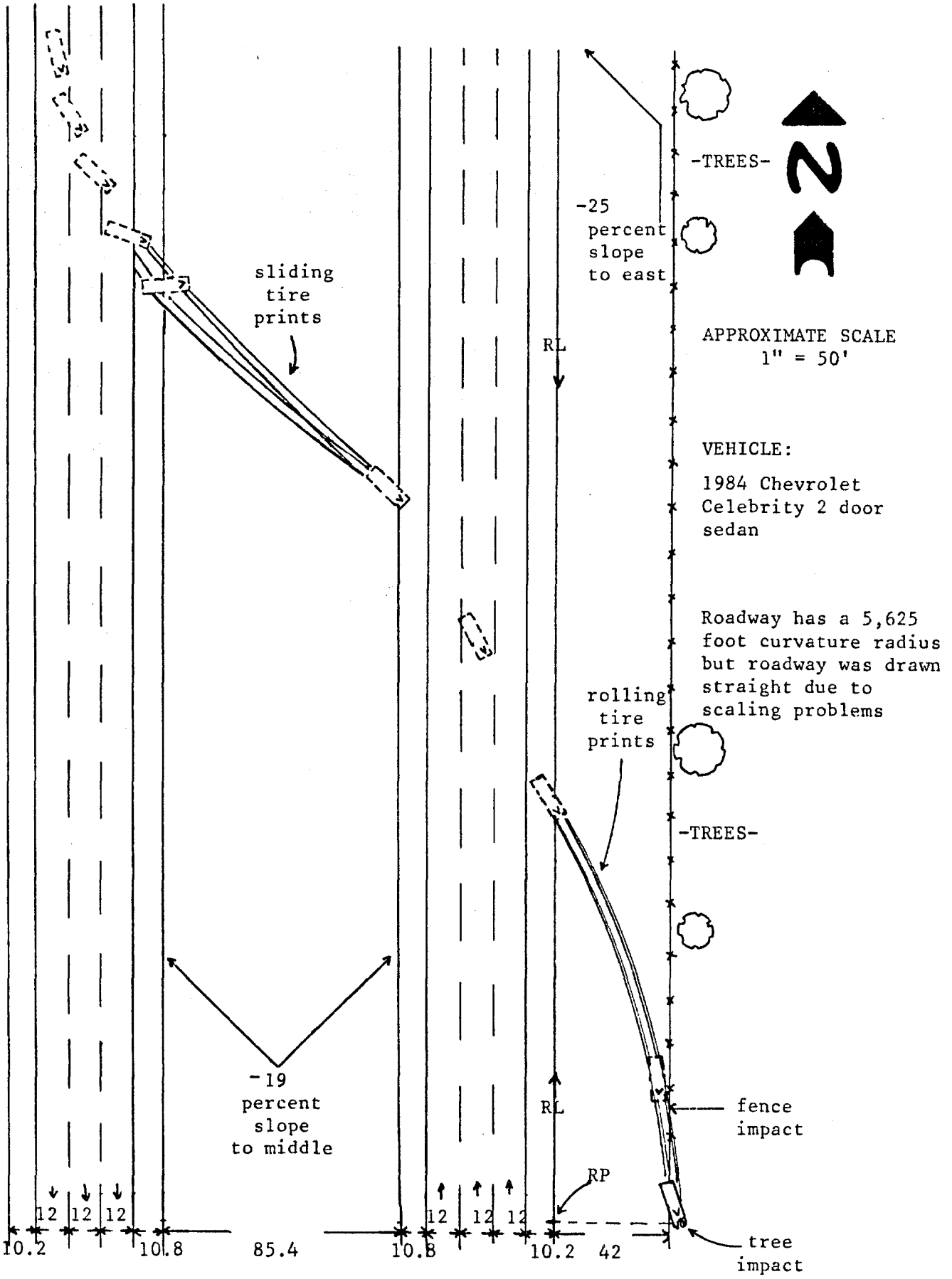

SELECTED PHOTOGRAPHS, CASE 080

1.



Scene. Major, asphalt interstate highway. V1 direction of travel. V1 crossed roadway and entered wooded area to the left.

2.

Tree impacted by V1 after going through a barbed wire fence. Tree is 7.5 inches in diameter and about 500 feet from V1's 1st skids.

SELECTED PHOTOGRAPHS, CASE 080

3.



V1. 1984 Chevrolet Celebrity 2 door. Max crush = 36.9 inches. Frontal. Delta V =29.5 m.p.h. Left toepan intrusion =8.5 inches.

4.



V1 interior. Steering column, driver's door, roof, windshield all altered during rescue. Our case; AIS-3 pelvis, AIS-2 leg/foot.

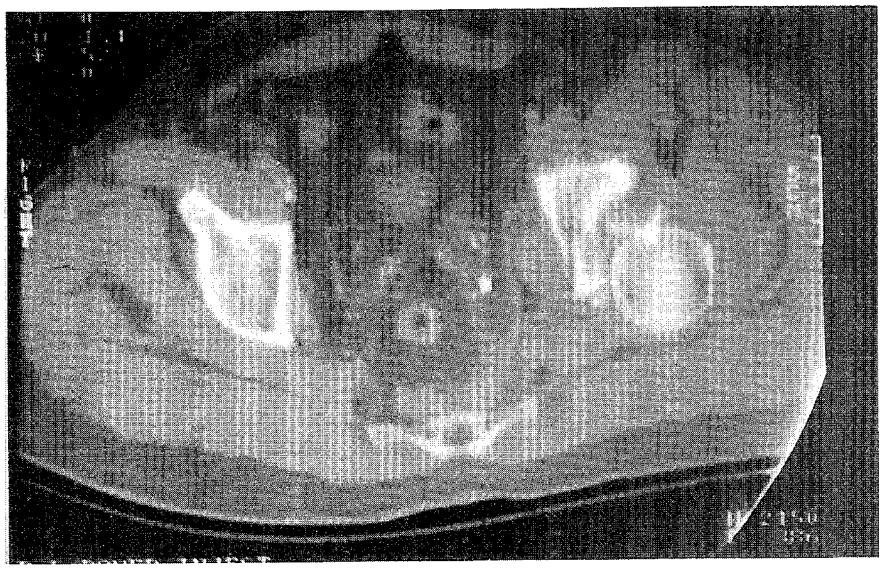

080A X-Ray revealing a transerve posterior fracture of the left acetabulum with dislocation.

Contact Point- Left Instrument Panel. Knee load?
Type of Crash- Frontal

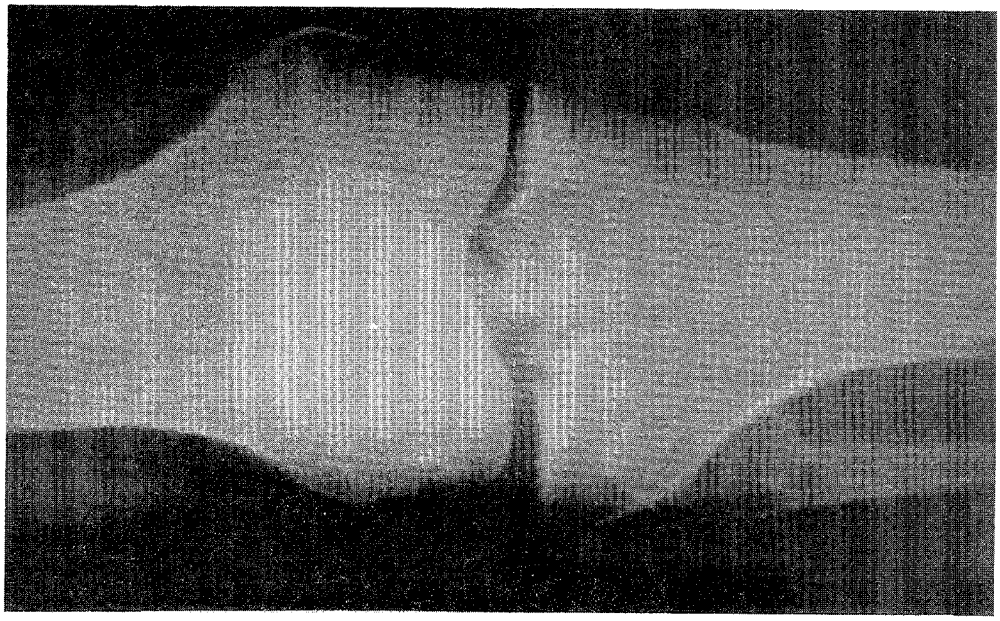

080B X-Ray revealing both a comminuted right tibial plateau and right oblique proximal fibular head fractures.

Contact Point- Left Instrument Panel
Type of Crash- Frontal

080C X-Ray revealing a transverse right ankle pilon fracture.

Contact Point- Toepan
Type of Crash- Frontal

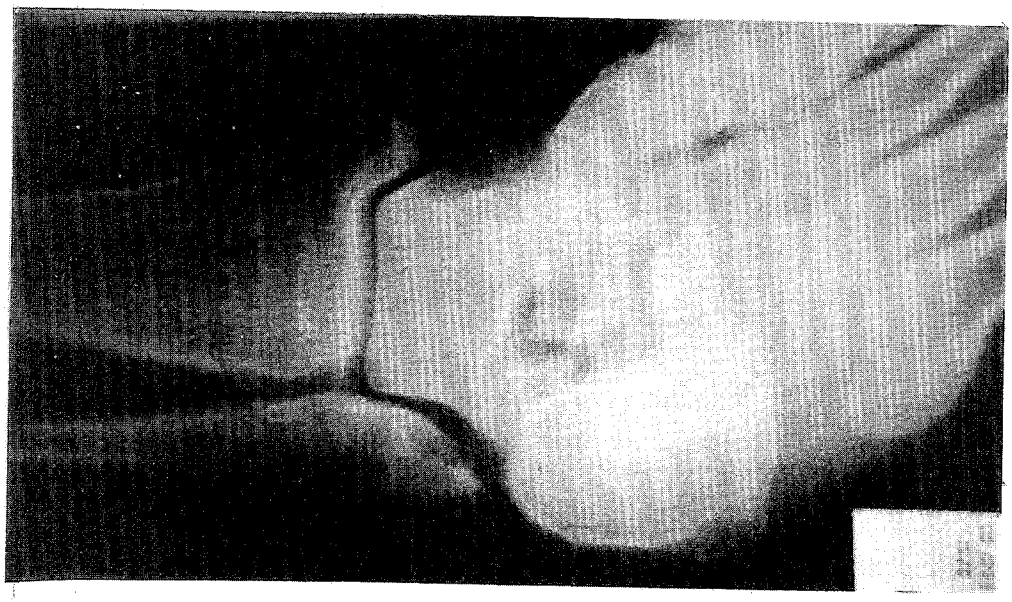

080D X-Ray revealing a comminuted fracture of the right calcaneus.

Contact Point- Toepan
Type of Crash- Frontal

SUMMARY - CASE 156 (034)

This was a 2 vehicle collision which occurred on a cloudy summer weekday afternoon. The collision involved a 1979 Honda Civic 1200, 3-door hatchback with one 18-year-old male occupant (our case), and a 1984 Pontiac Firebird 2-door sedan with one 61-year-old female occupant.

The roadway is a rural, asphalt, arterial street which has 1 northbound lane and 1 southbound lane. The travel lanes are each approximately 12 feet in width and the movements are separated by a double yellow paint stripe. The lanes are bordered to the east and west by 10-foot-wide paved asphalt shoulders. The roadway was dry and in excellent condition at the time of the collision, and the estimated roadway coefficient of friction was .75.

The Honda was northbound at an estimated speed of between 39 and 43 miles per hour, and had exited a right-hand curve several hundred feet to the south of the impact point. The Pontiac was southbound at an estimated speed of between 42 and 46 miles per hour, and had also exited a right-hand curve prior to impact. The posted speed limit was 50 miles per hour. The Honda straddled the centerline of the roadway and continued traveling north in the southbound lane. The driver of the Pontiac applied the brakes and the Pontiac skidded 17.6 feet prior to impact. The left 5.5 inches of the Honda's front bumper impacted the left side of the Pontiac's front bumper. Both vehicles rotated counterclockwise during the collision, and the entire front of the Pontiac eventually engaged the left side of the Honda. Maximum longitudinal crush to the front of the Honda was measured to be 20.4 inches, and its estimated speed change at impact was 32.3 miles per hour. Maximum longitudinal crush to the front of the Pontiac was measured to be 32.1 inches, and its estimated speed change at impact was 19.6 miles per hour. There was no evidence of any braking by the Honda before impact.

The driver of the Honda (our case) was forced forward and into the intruded "A" pillar at impact. He sustained 5 head injuries up to AIS-5 in severity as a result of "A" pillar contact. He also sustained 4 AIS-1 facial lacerations and contusions as a result of windshield contact, and AIS-1 lacerations and abrasions to the upper left arm due to flying glass. The drivers of both vehicles were transported to hospitals for treatment, and both vehicles were towed from the scene with disabling damage. The driver of the Pontiac was using the available manual lap and shoulder belt. The driver of the Honda was not using the available manual lap and shoulder belt. A complete list of injuries for this case is included below in OIC format:

BODY CONTACTS AND INJURIES TABLE-CASE 156
18 year old male; Driver; 1979 Honda Civic; Frontal/corner impact

OIC/AIS CODE	ICD-9	BODY CONTACTS AND INJURIES	CONTACT POINT

1.	2HUUB3	221101	854.0	Diffuse Cerebral Edema	Left A Pillar
2.	2HUCB3	221101	851.06	Diffuse Cerebral Hemorrhagic Contusions	Left A Pillar
3.	2HWKB2	221101	852.26	Loss of Consciousness	Left A Pillar
4.	2HLCI1	221101	851.46	Left Parietal-Occipital Hematoma	Left A Pillar
5.	2HICB5	221101	851.46	Brain Stem Hemorrhagic Contusion	Left A Pillar
6.	2FLLO1	011100	870.0	Left Eyelid Laceration	Windshield
7.	2FLCO1	011100	921.1	Left Eyelid Hematoma	Windshield
8.	2FLLI1	011100	873.41	Left Cheek Laceration	Windshield
9.	2FILD1	979799	873.74	Right Degloving of the Max-lingual frenum/lip	UNKNOWN
10.	2FILI1	011100	873.43	Left Lip Laceration	Windshield
11.	2ALAI1	912300	880.09	Multiple Abrasions, Left Upper Arm	Flying Glass?
12.	2ALLI1	912300	912.0	Multiple Lacerations <5cm Left Upper Arm	Flying Glass?
	UNKNOWN IF INJURED			Abraded plastic, fabric transfer	Driver's Armrest
	UNKNOWN IF INJURED			Abraded plastic, fabric transfer	Steering Rim Upper
	UNKNOWN IF INJURED			Deformed Rim	Steering Rim Lower
	UNKNOWN IF INJURED			Deformed plastic, skin deposit	Instrument Panel, Left
	UNKNOWN IF INJURED			Deformed toepan/side panel	Left Toepan/ side panel
	UNKNOWN IF INJURED			Broken radio knob, fabric thread deposits	Instrument Panel, Center
	UNKNOWN IF INJURED			Deformed metal, blood deposits	Upper Right Door Panel

CRASH TIMELINE - CASE 156

T - 2 seconds: This was a 2 vehicle collision which occurred on a cloudy weekday afternoon. The collision involved a 1979 Honda Civic 1200, 3 door hatchback (V1) with one 18 year old male occupant (our case), and a 1984 Pontiac Firebird 2 door sedan (V2) with one 61 year old female occupant.

The roadway is a rural, asphalt, arterial street which has 1 northbound lane and 1 southbound lane. The travel lanes are each approximately 12 feet in width, and the movements are separated

by a double yellow paint stripe. The lanes are bordered to the east and west by 10 foot wide paved asphalt shoulders. The posted speed limit is 50 miles per hour. The roadway was dry and in excellent condition at the time of the collision, and had an estimated coefficient of friction of .75.

V1 was northbound at an estimated speed of between 39 and 42 miles per hour, and had exited a right-hand curve several hundred feet to the south of the impact point. V2 was southbound at an estimated speed of between 42 and 46 miles per hour, and had also exited a right-hand curve prior to impact. V1 straddled the centerline and continued traveling north in the southbound lane.

T - .28 seconds: The driver of V2 applied the brakes, and V2 skidded 17.6 feet prior to impact. During the skid, V2 rotated slightly counterclockwise. Just prior to impact, V2 was traveling an estimated speed of between 38 and 42 miles per hour, and was skidding due south with a negative 4 degree slip angle. V1 was still traveling due north in the southbound lane at an estimated speed of between 39 and 42 miles per hour.

T - 0: The left 5.5 inches of V1's front bumper impacted the left side of V2's front bumper. Both vehicles rotated counterclockwise during the collision, and the entire front of V2 eventually engaged the left side of V1. Maximum longitudinal crush to the left front bumper corner of V1 was measured to be 20.4 inches. Estimated speed change at impact was 32.3 miles per hour. V1's left "A" pillar intruded longitudinally 11.5 inches. Due to the pocketing of V2's left front wheel with V1's left front wheel, V2's front rotated into V1's left side. This caused 11.5 inches of lateral intrusion to the left "A" pillar as well as 6.5 inches of lateral intrusion to the driver's door panel.

Our case was forced forward and to the left and sustained the following head injuries from contact to the left "A" pillar: diffuse cerebral edema (AIS-3), diffuse cerebral hemorrhagic contusions (AIS-3), unspecified loss of consciousness (AIS-2), a left parietal-occipital hematoma to the scalp (AIS-1), and a hemorrhagic contusion to the brain stem (AIS-5). He also sustained the following four injuries from contact to the lower left windshield near the left "A" pillar: a laceration and a contusion to the left eyelid (both AIS-1), a laceration to the lip (AIS-1), and a laceration to the left cheek (AIS-1). He sustained a tear (degloving) of the right max-lingual frenum/lip (AIS-1), but no positive injury source could be located. This injury my have been caused by our case's teeth when he rebounded into the right door panel after impact. 2 small dents were found in the upper right door panel. Our case was not using the available manual lap and shoulder belt.

The left instrument panel and the left toepan intruded longitudinally 6.1 and 5.4 inches respectively. Our case's left knee impacted the left instrument panel, and his left lower leg contacted the left toepan/side panel area. No injuries were recorded as a result of these contacts. Our case sustained multiple abrasions and lacerations to the left upper arm. These injuries were probably the result of flying glass fragments from

the windshield and left front window. The steering rim was deformed, abraded, and had a fabric transfer, but no injuries were recorded as a result of this contact. The radio in the center instrument panel had a broken knob and fabric thread deposits, but again, no injuries were noted as a result.

At impact, V2 sustained a maximum longitudinal front bumper crush of 32.1 inches. Estimated speed change at impact for V2 was 19.6 miles per hour. The left toepan intruded longitudinally 3.9 inches. V2's driver was forced forward and to the left at impact, and there was a knee impact to the left instrument panel as well as deformation and abrasion to the steering rim and hub. The driver was using the available manual lap and shoulder belt, and she reportedly sustained incapacitating injuries.

T + 1.25 seconds: After impact, V2 continued counterclockwise rotation and skidded south 17.8 feet to final rest. At final rest, V2 was facing due east. V2's driver was eventually transported to a hospital for treatment.

T + 1.68 seconds: V1 also continued counterclockwise rotation after impact and skidded 31.7 feet to final rest. At final rest, V1 was facing due south. V1's driver (our case) was eventually transported to a trauma center for treatment. Both vehicles were towed from the scene with disabling damage.

T + 1 minute: Police were notified of the collision.

T + 12 minutes: Police arrived at the scene.

PREHOSPITAL AND HOSPITAL TIMELINE - CASE 156

T+ 1min: Ambulance receives call to respond.

T+ 6min: Ambulance arrives at scene. Initial field assessment reveals a blood pressure of 140/70, a heart rate of 80, a respiratory rate of 10, and a Glascow Coma Score of 3. Prehospital care includes fluid resuscitation with the administration of 200cc of crystalloid. The patient required extrication from the vehicle.

T+ 36min: Patient departs scene for MIEMSS/Shock Trauma by police medevac helicopter.

T+ 72min: Patient arrives at MIEMSS. Initial physiologic assessment of the patient reveals a blood pressure of 168/103, a heart rate of 130, a respiratory rate of 20, and a Glascow Coma Score of 3. The patient's ISS (Injury Severity Score) = 29. Toxicology screen results are negative. Initial hospital care provided includes:

- Evaluation by a MIEMSS trauma team,
- Fluid resuscitation,
- Peritoneal lavage with positive results,
- Full diagnostic evaluation including x-rays of the cervical spine, chest and pelvis. In addition to the toxicology screen, an arterial blood gas, a CBC (complete blood count), an SMA-6 (routine blood chemistry) and UA (urinalysis) performed.

Initial clinical findings included the following:

- -Diffuse cerebral edema
- -Brain stem hemorrhagic contusion
- -Diffuse cerebral hemorrhagic contusions
- -Positive loss of consciousness
- -Left parietal- occipital hematoma
- -Left cheek laceration
- -Left eyelid laceration and hematoma
- -Left lip laceration
- -Right degloving of the max-lingual frenum
- -Multiple abrasions and lacerations of the right upper extremity

Operative care included:

- -Placement of ICP (Intra-cranial Pressure) monitor

T+24hours - 35 days: Patient spends 22 days in intensive care and 13 days in intermediate care. Complications during the acute care phase include: pneumonia.

T+ 35 days: Patient discharged from MIEMSS to an out-of-state rehabilitation facility.

COGNITIVE-COMMUNICATIVE ASSESSMENT - CASE 156

The patient was initially evaluated on T + 6 days. The patient was orally intubated at the time of the evaluation. The patient exhibited spontaneous eye opening with some purposeful limb movements. Patient did not visually track, auditory localize or follow commands. The patient was felt to be functioning on an RLAS II Generalized Response Level (Rancho Los Amigos) with a Glasgow Coma Score of 9. The patient was unable to ingest anything orally and his hearing could not be assessed due to his decreased cognitive functioning. He was recommended to receive daily treatments.

The patient was administered a discharge evaluation on T + 25 days as he was being transferred to an inpatient rehabilitation facility. The patient was breathing independently and was not trached. The patient exhibited appropriate localizing responses and was able to follow 1 step psychomotor commands. The patient was unable to verbalize although he inconsistently made incomprehensible sounds. No other communicative responses were noted. The patient was felt to be functioning at an RLAS III- Localized Response level with a Glasgow Coma Score of 12. As during the initial assesssment, the patient was unable to respond to the assessment protocol. Although hearing could not formally assessed, audiology felt that his hearing was adequate for the reception of speech. The patient continued to be unable to ingest anything orally. It was recommended that the patient continue to receive aggressive therapy in rehabilitation.

PSYCHOSOCIAL FOLLOW-UP - CASE 156

6 Months

Eighteen (18)-year-old college student discharged from Shock Trauma after 30 days acute care to inpatient rehabilitation facility for continued cognitive therapy. At discharge patient was non-ambulatory and following commands inconsistently. Patient remained in rehabilitation for 2 months and discharged home with outpatient therapy 2 times weekly. At 5 months post-trauma, patient returned to college part-time although not yet driving independently. Patient continues to exhibit mood swings, extreme fatigue and nervousness. He also admits to problems with concentration and memory. He exhibits slight problems with balance and some vision problems.

1 Year

Patient continued his college education on a part time basis due to mild-to-moderate attention problems and long-term memory problems. Both patient and parents admit to some judgement errors although at times he has good perception skills. He expresses a good sense of humor and has no ambulation problems.

PREVENTION AND INJURY REDUCTION - CASE 156

Ten of the twelve injuries sustained by our Case occurred from "A" pillar or windshield contact (where the windshield meets the "A" pillar). The "A" pillar intruded longitudinally 11.5 inches and laterally 11.5 inches, so in effect, the "A" pillar moved toward the driver 16.26 inches. Had the driver been restrained by the available manual lap and shoulder belt, he still may have contacted the "A" pillar, however, his injuries might have been less severe. Given the size of our Case with respect to the size of the case vehicle, the available restraints would probably not have kept his head from rebounding into the right door panel either. A 4 or 5 point harness would have prevented driver contact to the right door panel. Had the "A" pillar been substantially stronger (from the roof to the floor pan), much of the intrusion might not have occurred. Given the 32 mile per hour delta V, our Case may have escaped serious injury had he been restrained and had the "A" pillar not intruded so severely.

This collision might have been no more serious than a sideswipe had the left front wheels of both vehicles not overlapped. This overlapping provided a rotational pivot for V2. V2's front rotated into V1's left side which caused the lateral component of the "A" pillar intrusion to V1 (our case vehicle). It is possible that wheel designs could be taken into consideration when addressing the problem of wheel snagging. For instance, a wheel made from an alloy that provided for safe operation in "worst case" normal driving conditions, yet gave way in high energy impact situations might help to eliminate this

snagging.

The obvious preventative measure in this case would be to prevent a vehicle from entering into opposing traffic movements.

--- Jerry Jackson

COLLISION SCHEMATIC, CASE 156

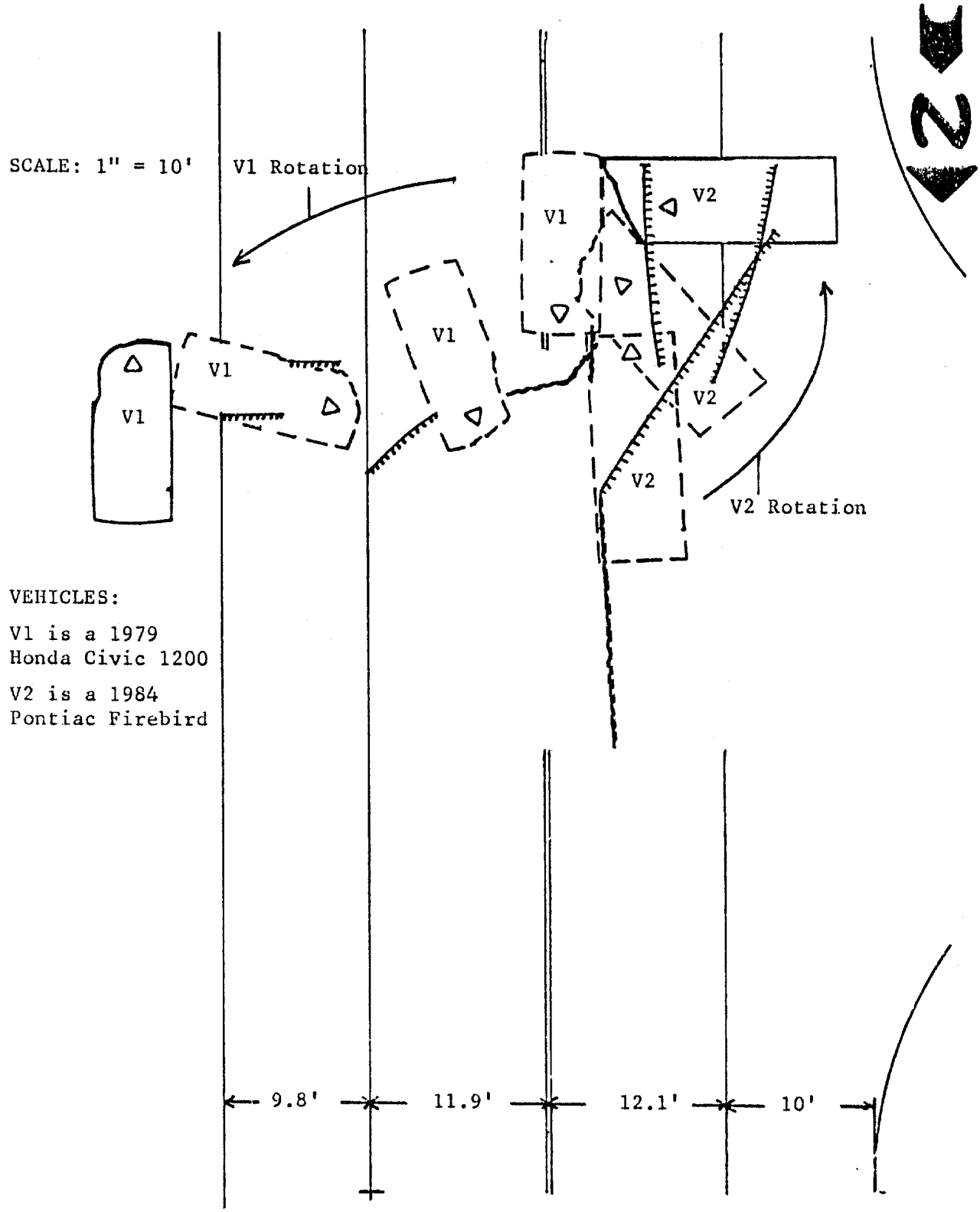

SELECTED PHOTOGRAPHS, CASE 156

1.



Scene. V1 direction of travel, V2 approach (north). POI in center of photo. V1 FRP is to the right, V2 FRP is to the left.

2.



V1 exterior. Max frontal crush =20.4 inches. Delta V =32.3 m.p.h. Left front wheel snag caused V2 to rotate into left side.

SELECTED PHOTOGRAPHS, CASE 156

3.



V1 interior. A pillar intrusion = 11.5 inches longitudinal, 11.5 inches lateral. A pillar = 5 head injuries to AIS-5 (Brain Stem).

4.



V2 exterior. Max frontal crush =32.1 inches. Delta V =19.6 m.p.h. Left front wheel snag caused V2 to rotate into left side of V1.

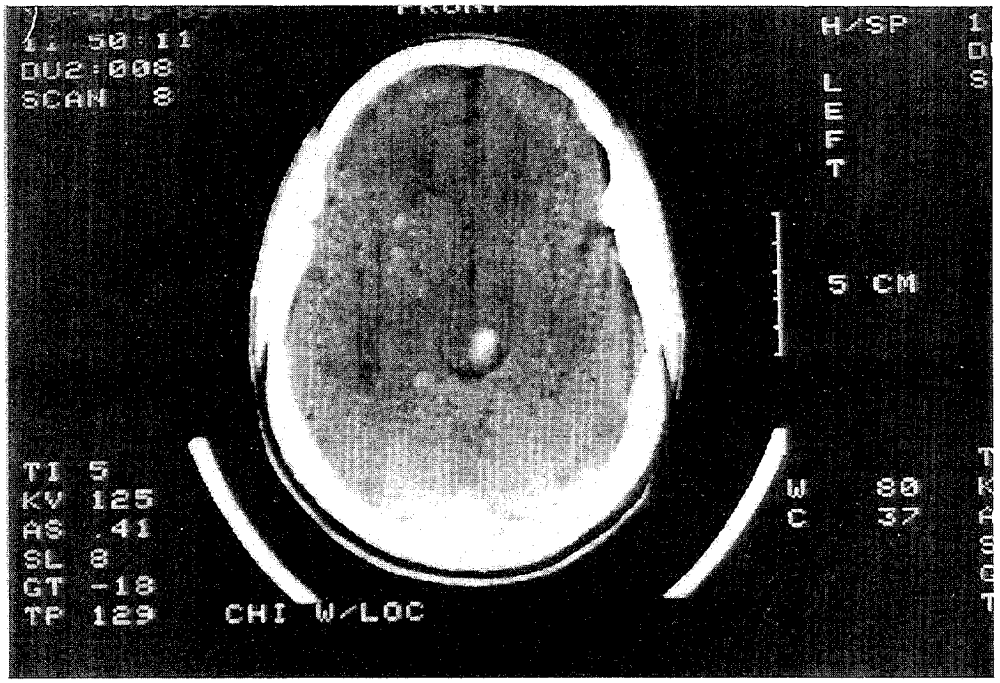

156A CT Scan revealing brainstem and diffuse cerebral hemorrhagic contusions.

Contact Point- Left "A" Pillar
Type of Crash- Frontal/Left corner impact

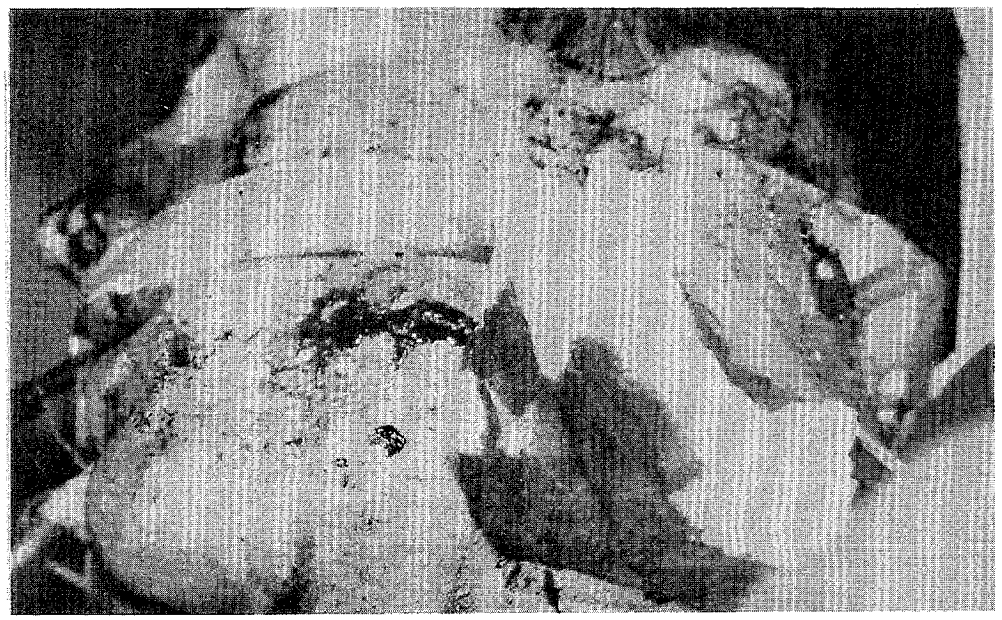

156B Left cheek laceration with multiple facial abrasions (< 5 cm). The patient has been endotracheally intubated and is being ventilated by a respirator. The rear section of a Philadelphia collar is still in place.

Contact Point- Windshield
Type of Crash- Frontal/Left Corner impact

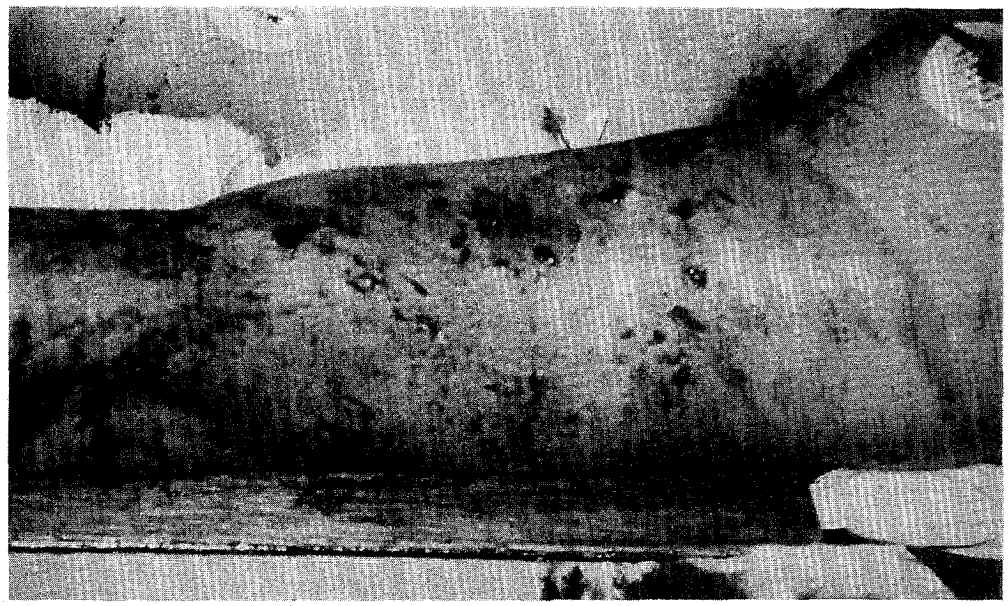

156C Multiple abrasions and lacerations (< 5 cm) to the left upper arm.

Contact Point- Flying glass?
Type of Crash- Frontal/Left corner impact

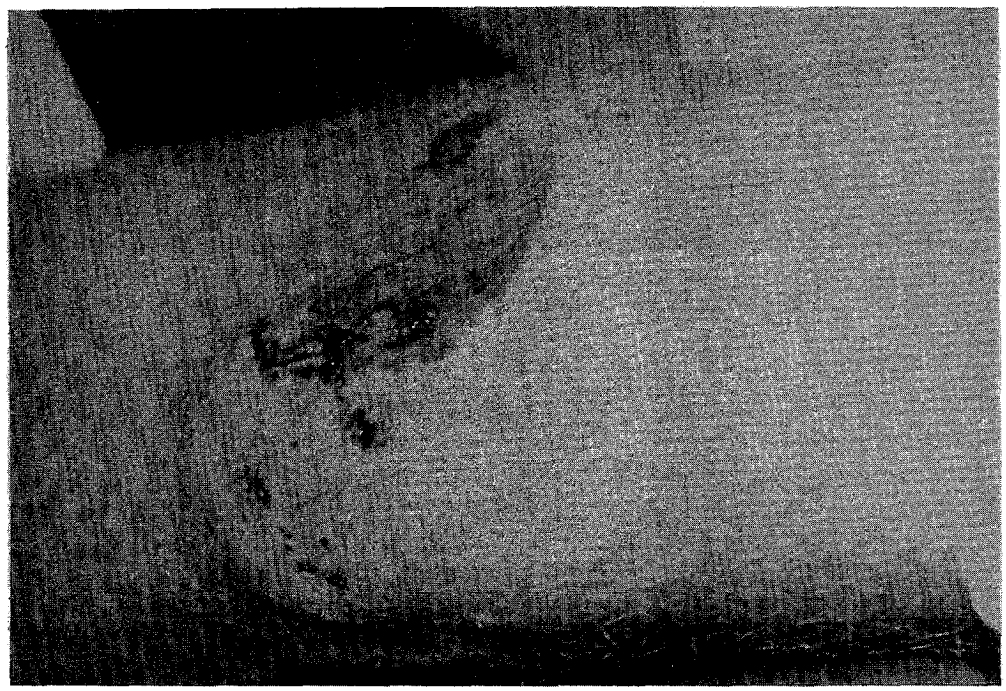

156D Right knee laceration.

Contact Point- Frontal/Left corner impact
Type of Crash- Center Instrument panel, Radio?

SUMMARY - CASE 486 (035)

This three vehicle accident occurred on a cloudy weekday in the summer. Vehicle 1, a 1979 Datsun B210 station wagon, was being driven eastbound at an estimated speed of 40-50 miles per hour. The driver, a 30 year old female, was not wearing the available lap/shoulder belt and the vehicle is not equipped with an air cushion restraint system. Vehicle 2, a 1982 Chevrolet hi-cube type truck, was being driven westbound followed by Vehicle 3, a 1984 Chevrolet Cavalier 4 door at speeds estimated as 40-45 miles per hour. The accident report indicates the driver of Vehicle 2 was wearing his available seat belt. The driver of Vehicle 3, a 53 year old female was not wearing the available lap/shoulder belt and this vehicle was not equipped with an air cushion restraint system. Prior to impact number 1, the driver of Vehicle 1 allowed her vehicle to cross the center line and struck Vehicle 2 in a side swiping type action. The left frontal plane of Vehicle 1 contacted the left side plane of Vehicle 2. This damage was masked by damage from impact number 2. At impact number 2, the entire frontal plane of Vehicle 1 struck the frontal plane of Vehicle 2. This impact produced 41.5 inches of direct and induced damage to Vehicle 1 and a maximum crush of 31.5 inches located at the right front bumper corner. Vehicle 3 sustained 44 inches of direct and induced damage and a maximum crush of 19.25 inches which was also located at C6, the right front bumper corner. The unbelted driver was displaced right of the steering column and forward striking the windshield with her forehead. As the driver moved right and forward, her torso contacted the steering hub, spoke and rim on the three o'clock side severely deforming and breaking the wheel which produced multiple left rib fractures, a lacerated spleen and liver, and left retroperitoneal hemotoma. As the driver's head struck the windshield and rear view mirror, she sustained a large laceration and abrasion. As the vehicle rotated counterclockwise to final rest, the driver struck the center instrument panel producing a fractured alveolar process and a large laceration to her lip and chin. The driver's movement toward the right also produced a laceration to the left leg which contacted the lower instrument panel. The highest AIS for the case is AIS-4. She was treated at the scene, transported and admitted for further treatment at a major trauma hospital. Both Vehicles 1 and 3 were towed due to damage.

BODY CONTACTS AND INJURIES TABLE-CASE 486
30 year old female; Driver; 1979 Datsun B210; Frontal impact

OIC/AIS CODE	ICD-9	BODY CONTACTS & INJURIES	CONTACT POINT
1. 2FALI2 161100	873.42	Laceration, Forehead	Combination windshield & rear view mirror
2. 2FAAI2 161100	910.0	Abrasion, Forehead	

3.	2FIFS2	101100	873.44	Fracture, Intra Alveolar	Center instrument panel & below
4.	2FILI2	101100	802.27	Laceration, Chin & Lip (6 cm)	
5.	2CLFS2	051100	807.09	Fractures, multiple left rib	steering wheel, hub & spoke (possible center instrument panel & below)?
6.	2MLLO3	051100	865.02	Laceration, spleen	
7.	2MRLL4	051100	864.02	Laceration, left liver	
8.	2MIUU3	051100	868.04	Contusion, left retro-peritoneal	
9.	2KLLJ3	101100	891.0	Laceration, left knee	Center instrument panel & below

CRASH TIMELINE - CASE 486

T - 2.0 Seconds: Vehicle 1, a 1979 Datsun B310 station wagon was being driven eastbound by a 30 year old female at a speed estimated at 40 to 50 miles per hour. Vehicle 2, a 1982 Chevrolet truck, being driven by a 53 year old male and Vehicle 3, a 1984 Chevrolet Cavalier, being driven westbound by a 53 year old female at speeds estimated at 40-45 miles per hour. The driver of Vehicle 2 was the only driver wearing the available belt restraint system and neither vehicle is equipped with an air cushion restraint system. The roadway is two lane paved asphalt with a coefficient of friction estimated as .70. The weather was cloudy, the roadway was dry and the traffic was light to moderate. The accident location is rural residential and no unusual roadway or environmental conditions existed.

T - 1.0 Seconds (estimated): The driver of Vehicle 1 allowed the vehicle to cross the center line of westbound traffic and strike Vehicle 2 in a side swiping type configuration causing unknown damage to the left side of both vehicles.

T - 0.0 Seconds: No corrective or evasive action was taken by the driver of Vehicle 1 and her vehicle continued in a near straight path to impact number 2 with Vehicle 3. The driver of Vehicle 3 attempted evasive action consisting of maximum braking and steering right. This action was unsuccessful and Vehicle 1 struck Vehicle 3 frontal plane to frontal plane. At impact with Vehicle 3, the unbelted driver of Vehicle 1 possibly already displaced slightly right of the steering wheel by the previous impact with Vehicle 2, was thrown into contact with the right side of the steering hub, spoke and rim with a force sufficient to deform and break the wheel. This contact probably caused the multiple left rib fractures, lacerated spleen and liver, and left retroperitoneal hemotoma. Further forward and

right movement caused windshield and rear view mirror contact resulting in large lacerations and abrasions to the forehead of the driver of Vehicle 1. As the vehicle rotated and decelerated, the driver contacted the center instrument plane resulting in a large laceration to the chin and lip and an alveolar fractire. The driver's movement towards the right also produced a laceration to her left knee as a result of contact with the left lower instrument panel.

T + 1.2 Seconds (estimate): Vehicle 1 rotated counterclockwise and came to rest facing north on the north side of the road. Vehicle 2 rotated clockwise and slid to rest facing south southwest.

T + 1.0 Minutes: The police were notified.

T + 4.0 Minutes: The police arrived and began investigative and medical relief efforts.

PREHOSPITAL AND HOSPITAL TIMELINE - CASE 486

T+ 1min: Ambulance receives call to respond.

T+ 9min: Ambulance arrives at scene. Initial field assessment reveals a blood pressure of 90/palp., a heart rate of 100, a respiratory rate of 22, and a Glascow Coma Score of 15. Prehospital care includes fluid resuscitation with the administration of 1600 cc of crystalloid. The patient required extrication from the vehicle.

T+ 43min: Patient departs scene for MIEMSS/Shock Trauma by police medevac helicopter.

T+ 72min: Patient arrives at MIEMSS. Initial physiologic assessment of the patient reveals a blood pressure of 90/60, a heart rate of 110, a respiratory rate of 24, and a Glascow Coma Score of 15. The patient's ISS (Injury Severity Score) = 33. Toxicology screen results were negative.

Initial hospital care provided includes:

- -Evaluation by a MIEMSS trauma team,
- -Fluid resuscitation,
- -Diagnostic peritoneal lavage with positive results,
- -Full diagnostic evaluation including x-rays of the cervical spine, chest and pelvis. In addition to the toxicology screen, an arterial blood gas, a CBC (complete blood count), an SMA-6 (routine blood chemistry) and UA (urinalysis) were performed.

Initial clinical findings included the following:

- -Forehead laceration
- -Intra-alveolar fracture
- -Full thickness chin laceration (> 5cm)
- -Full thickness lip laceration
- -Multiple left sided rib fractures
- -Splenic laceration
- -Liver laceration
- -Retroperitoneal hematoma

-Intra-articular left knee laceration
-Injury to left lateral ligament of knee (retinaculum)
-Fracture of right metatarsal (transverse, middle 1/3)

Operative procedures include:

-Repair of injury to the ligament of the left knee
-Surgical repair of spleen
-Surgical repair of liver

T+24hours - 9 days: Patient spends 5 days in intensive care and 4 days in intermediate care. There were no complications during the patient's acute care phase of treatment.

T+ 9 days: Patient discharged from MIEMSS to home.

COGNITIVE-COMMUNICATIVE ASSESSMENT - CASE 486

The patient was initially evaluated on T + 4 days. Suffering from abdominal injuries, facial lacerations, and a mandibular fracture, the cognitive-communicative evaluation indicated auditory comprehension, verbal expression, written expression, and cognitive skills to be within normal limits. The patient's speech production skills were slightly reduced due to the mandibular fracture. The patient had a Glasgow Coma Score of 15, and no Rancho Los Amigos Score (RLAS) was assigned due to the lack of closed head injury. The patient was unable to be fed orally due to her oral status and was beiong fed through a nasogastric tube. The patient's hearing was screened and found to be within normal limits bilaterally. No further follow-up was recommended.

The patient was briefly encountered on T + 6 days and was on a full liquid diet and had had the nasogastric tube removed.

PSYCHOSOCIAL FOLLOW-UP - CASE 486

Information not obtained.

CRASH AND INJURY PREVENTION IDEAS - CASE 486

This accident occurred when a driver apparently fell asleep and crossed the center line. The development of electronic "smart" highways, with the ability to analyze impending dangerous situations, and speed regulators would greatly enhance the safety aspect of collision avoidance. The ability to overcome human error through the use of electronics will greatly reduce accidents such as this one. As in most of our case study frontal impacts, automatic seat belts and air cushion restraint systems would have greatly reduced the severity of injuries.

--The Crash Investigation Team

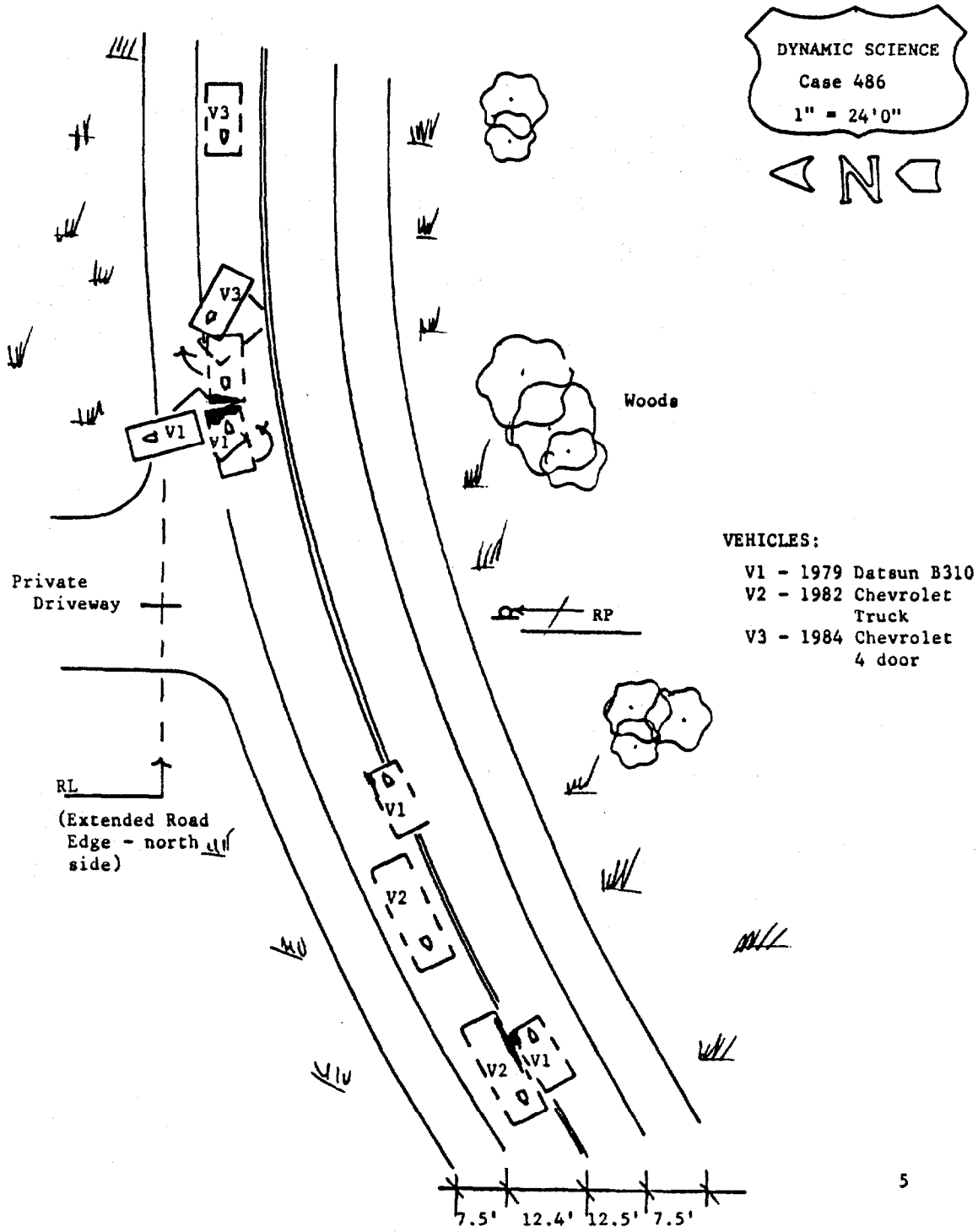
DYNAMIC SCIENCE
Case 486
1" = 24'0"
N
V3
V3
V1
V1
Woods
Private
Driveway
RP
RL
(Extended Road
Edge - north
side)
V1
V2
V2
V1
7.5'
12.4'
12.5'
7.5'
VEHICLES:
V1 - 1979 Datsun B310
V2 - 1982 Chevrolet
Truck
V3 - 1984 Chevrolet
4 door

SELECTED PHOTOGRAPHS, CASE 486

1.



Scene; V1's easterly path of travel and sideswipe POI area with V2 (1982 Chevrolet hi-cube type truck).

2.



Scene; V1 (1979 Datsun B310 station wagon) point of impact with V3.

SELECTED PHOTOGRAPHS, CASE 486

3.



V1 impact #2 with V3; frontal plane to frontal plane; V1 maximum crush 31.5" (right front bumper). Direct & induced damage 41.5".

4.



Unbelted driver's torso contacted steering hub, spoke & rim which deformed & broke steering wheel. Driver sustained left rib fractures (AIS-2), lacerated spleen (AIS-3)/liver (AIS-4), etc.

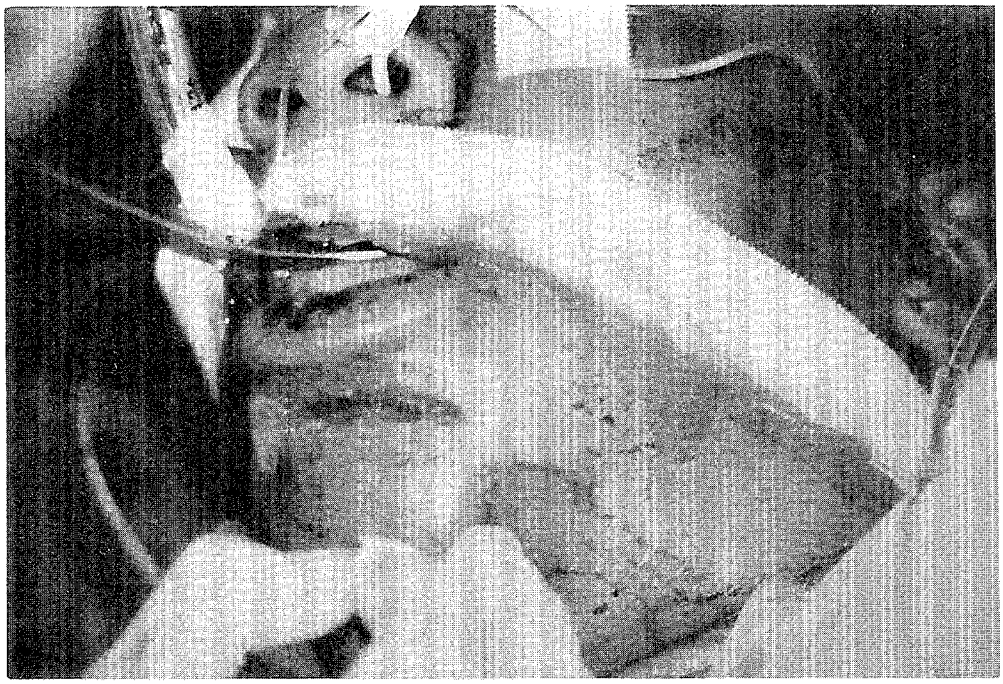

486A Full thickness chin laceration (>5 cm) and full thickness lower lip laceration. The patient has been endotracheally intubated and is being ventilated by a respirator.

Contact Point- Center instrument panel and below
Type of Crash- Frontal

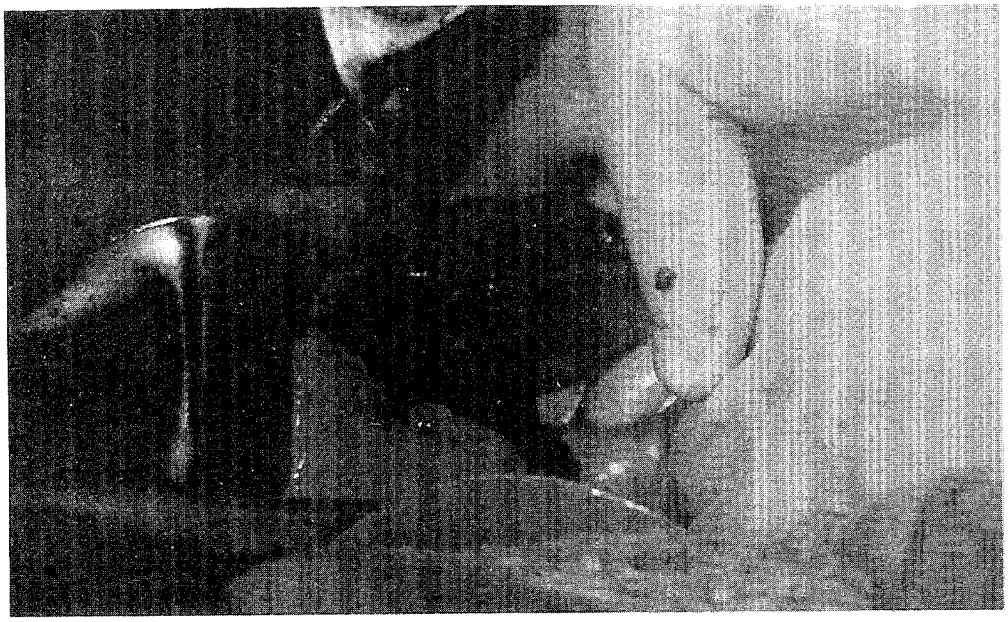

486B Operative photo of laceration to left lateral liver lobe with tissue destruction.

Contact Point- Steering wheel, hub and spoke
Type of Crash- Frontal

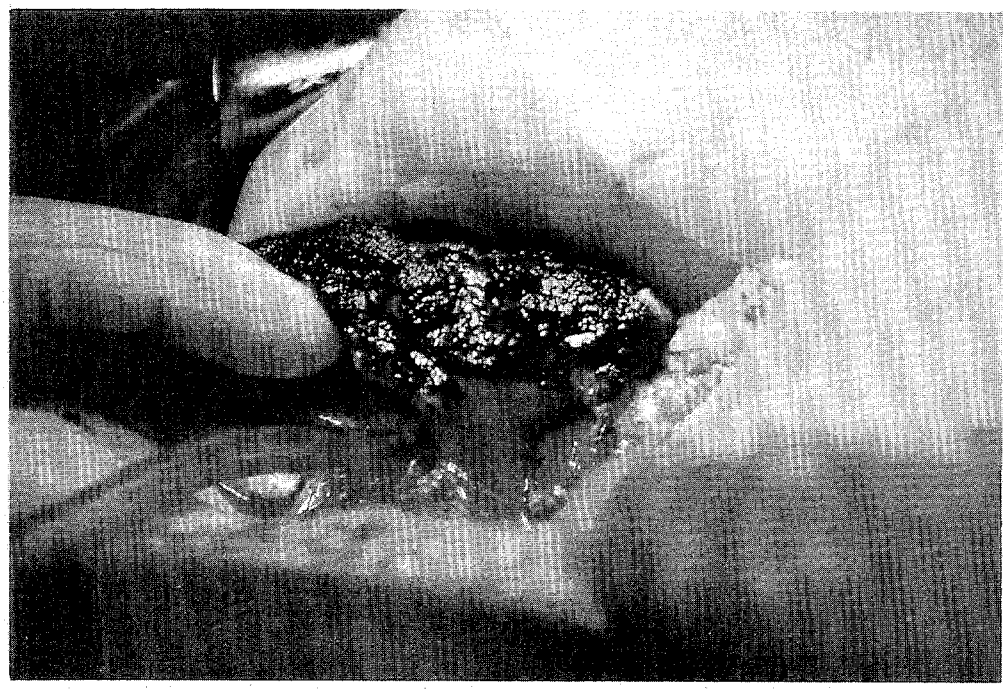

486C Operative photo of splenic laceration with tissue loss.

Contact Point- Steering wheel, hub and spoke
Type of Crash- Frontal

486D Left knee laceration extending into the joint space.

Contact Point- Center instrument panel and below
Type of Crash- Frontal

SUMMARY - CASE 129 (036)

This 2 vehicle collision occurred on a clear, fall, weekday afternoon. The collision involved a 1988 Honda Accord, 4 door sedan with one 44 year old male occupant (our Case), and a 1987 GMC 3500 Vandura passenger van which was equipped with a hydraulic boom arm system. The van (a commercial vehicle) was being driven by a 28 year old male. According to reference materials, the maximum GVWR for this van is 8,600 pounds, however, the owner reported that the van has a "work ready" curb weight of 10,500 pounds.

The roadway is a rural, asphalt, collector street which has 1 northbound lane and 1 southbound lane. The travel lanes are each approximately 12 feet in width and the movements are separated by a solid yellow paint stripe for northbound traffic, and an intermittant yellow paint stripe for southbound traffic. The travel lanes are bordered to the east and west by grassy fields. The roadway was dry and in good condition at the time of the collision, and the estimated coefficient of friction was .7. The posted speed limit is 40 miles per hour.

The Honda was northbound at an estimated speed of between 43 and 53 miles per hour. The GMC was southbound in the southbound lane at an estimated speed of between 39 and 49 miles per hour, and had exited a right-hand curve just prior to impact. The curve has a radius of approximately 1,042 feet at the centerline. The Honda straddled the centerline of the roadway and impacted the front of the GMC head-on in the southbound lane. Direct damage width to the front of the Honda was 36.5 inches. Direct damage width to the front of the GMC was 26.5 inches. Maximum longitudinal crush to the left front bumper corner of the Honda was measured to be 31.9 inches. Estimated speed change at impact was between 26 and 32 miles per hour. Maximum longitudinal crush to the front of the GMC was estimated to be 20 inches. Crush measurements were not obtained from the GMC because its weight is beyond the scope of CRASHPC. There was no evidence of braking by either vehicle before impact. The driver of the Honda (our Case) was forced forward and to the left at impact. He was using the available manual lap and shoulder belt and he sustained 1 AIS-1 abrasion from seatbelt contact. Our case also sustained an AIS-1 scalp laceration (possible "A" pillar contact), an AIS-2 right clavicle fracture (probable steering rim contact), an AIS-3/2 left humerus fracture/avulsion (probable left "A" pillar), an AIS-2 right tibia fracture (steering column), and an AIS-2 left trimalleolar fracture (left toepan). V1's windshield (AS1) was in place and holed in the lower left corner by impact forces. Other impact related windshield damage is unknown since the roof was removed for rescue. The left front and left rear side glass (AS2) were disentigrated by impact forces. There was no other impact related glazing damage.

Both vehicles rotated counterclockwise during impact. The Honda rotated approximately 216 degrees before coming to rest 31 feet to the northeast of the impact point. The GMC rotated

approximately 64 degrees and rolled onto its right side before coming to rest 81 feet to the south of the impact point. The drivers of both vehicles were transported to hospitals for treatment, and both vehicles were towed from the scene with disabling damage. A complete list of injuries for our Case is included below in OIC format:

BODY CONTACTS AND INJURIES TABLE-CASE 129
44 year old male; Driver; 1988 Honda Accord 4 door; Frontal impact

OIC/AIS CODE	ICD-9	CONTACTS & INJURIES	CONTACT POINT
1. 2HLLI1 223101	873.0	Laceration, Left Scalp 2cm, full thickness	A pillar??
2. 2SRFS2 042100	810.00	Fracture, Left Clavicle	Steering rim?
3. 2CLAI1 412100	911.0	Abrasions, Left Chest	Shoulder belt?
4. 2ALFS3 222101	812.10	Fracture, Proximal Left Humerus, open	A pillar?
5. 2ALVI2 222101	880.13	Avulsion, Left Proximal Upper Arm	A pillar?
6. 2TLAI1 202100	916.0	Abrasions, Left Thigh	Door panel?
7. 2LRFS2 071100	823.00	Fracture, Right Tibial Plateau	Lower steering column
8. 2QLFS2 561103	824.6	Fracture, Left Trimalleolar	Left toepan
UNKNOWN IF INJURED		Arm hair, blood	Windshield, lower left
UNKNOWN IF INJURED		Broken plastic	Instrument panel, lower left
UNKNOWN IF INJURED		Broken plastic, blood, hair, fabric fibers	Instrument panel, upper left

CRASH TIMELINE - CASE 129

T - 2 Seconds: This was a 2 vehicle collision which occurred on a clear weekday afternoon. The collision involved a 1988 Honda Accord, 4 door sedan (V1) with one 44 year old male occupant (our Case), and a 1987 GMC 3500 Vandura passenger van (V2) which was equipped with a hydraulic boom arm system. V2 (a commercial vehicle) was being driven by a 28 year old male. According to reference materials, the maximum GVWR for this van is 8,600 pounds, however, the owner reported that the van has a "work ready" curb weight of 10,500 pounds.

The roadway is a rural, asphalt, collector street which has 1 northbound lane and 1 southbound lane. The travel lanes are each approximately 12 feet in width and the movements are separated by

a solid yellow paint stripe for the northbound traffic, and an intermittant yellow paint stripe for southbound traffic. The travel lanes are bordered to the east and west by grassy fields. The roadway was dry and in good condition at the time of the collision, and the estimated coefficient of friction was .7. The posted speed limit is 40 miles per hour.

V1 was northbound at an estimated speed of between 43 and 53 miles per hour. V2 was southbound in the southbound lane at an estimated speed of between 39 and 49 miles per hour, and had exited a right-hand curve just prior to impact. The curve has a radius of approximately 1,042 feet at the centerline. V1 straddled the centerline of the roadway and continued traveling north.

T - 0: The front of V1 impacted the front of V2 head-on in the southbound lane. Direct damage width to the front of V1 was 36.5 inches. Direct damage width to the front of V2 was 26.5 inches. Maximum longitudinal crush to the left front bumper corner of V1 was measured to be 31.9 inches. V1's estimated speed change at impact was between 26 and 32 miles per hour. At impact, V1's left "A" pillar intruded longitudinally 18.5 inches and laterally 5.5 inches. Our Case was forced forward and to the left at impact, and he sustained a 2 centimeter, full thickness scalp laceration. The left "A" pillar was coded as a possible injury source, although no residual evidence was noted. The left side panel forward of the "A" pillar intruded laterally 10.4 inches, and the left toepan intruded longitudinally 10.5 inches. Our case sustained an associated left trimalleolar fracture. The instrument panel's left side intruded longitudinally 12.4 inches. Our Case sustained an open fracture of the left proximal humerus, and an avulsion to the upper arm from probable contact to the left "A" pillar, however, contact was also made to the left central instrument panel. Broken plastic, hair, blood, and fabric fibers were noted at the instrument panel. The steering rim was deformed and abraded. The upper rim is the probable source of our Case's right clavicle fracture. Our Case's right knee contacted the lower steering column, and he sustained an associated right tibial plateau fracture. Our Case also sustained abrasions to the left chest and left thigh. It is probable that the chest injury resulted from seatbelt loading. The manual lap and shoulder belt had stretched and torn webbing which indicates that the restraint was being used by our Case at the time of the collision.

Maximum longitudinal crush to the front of V2 was estimated to be 20 inches. Crush measurements were not obtained from V2 because it's weight is beyond the scope of CRASHPC.

T + 1.91 seconds: V1 rotated counterclockwise approximately 216 degrees before coming to rest 31 feet to the northeast of the impact point. Our Case was eventually transported by helicopter to a trauma center for treatment, and V1 was towed from the scene with disabling damage.

T + 3.57 seconds: V2 rotated counterclockwise approximately 64 degrees and rolled onto its right side before coming to rest 81 feet to the south of the impact point. The driver of V2

reportedly sustained incapacitating injuries and was eventually transported by ambulance to a hospital for treatment. The driver of V2 was also reported as using a lap and shoulder belt. V2 was towed from the scene with disabling damage.

T + 2 minutes: Police were notified of the collision.

T + 11 minutes: Police arrived at the scene.

PREHOSPITAL AND HOSPITAL TIMELINE - CASE 129

T+ 1min: Ambulance receives call to respond.

T+ 8min: Ambulance arrives at scene. Initial field assessment reveals a blood pressure of 104/80, a heart rate of 64, a respiratory rate of 14, and a Glascow Coma Score of 15. Prehospital care includes fluid resuscitation with the administration of 1000 cc of crystalloid. The patient required extrication from the vehicle.

T+ 69min: Patient departs scene for MIEMSS/Shock Trauma by police medevac helicopter.

T+ 71min: Patient arrives at MIEMSS. Initial physiologic assessment of the patient reveals a blood pressure of 106/65, a heart rate of 54, a respiratory rate of 14, and a Glascow Coma Score of 15. The patient's ISS (Injury Severity Score) = 21. Toxicology screen results were negative.

Initial hospital care provided includes:

- -Evaluation by a MIEMSS trauma team,
- -Fluid resuscitation,
- -Diagnostic peritoneal lavage with positive results,
- -Full diagnostic evaluation including x-rays of the cervical spine, chest and pelvis. In addition to the toxicology screen, an arterial blood gas, a CBC (complete blood count), an SMA-6 (routine blood chemistry) and UA (urinalysis) were performed.

Initial clinical findings included the following:

- -Contusion of left frontal scalp,
- -Laceration of left frontal scalp (<5 cm),
- -Fracture of left humerus (transverse, surgical neck, open/Grade II),
- -Fracture left humerus (transverse, distal articular surface, open/Grade III),
- -Contusion right anterior chest,
- -Fracture left ribs 1-8,
- -Multiple fractures of the right clavicle,
- -Left pneumothorax,
- -Contusion right anterior upper abdomen,
- -Contusion left anterior lower abdomen,
- -Fracture right tibia (oblique, proximal articular surface),
- -Fracture right fibula (oblique, proximal articular surface),
- -Fracture left tibia (oblique, distal articular surface),
- -Fracture left fibula (oblique, distal articular surface),

Operative procedures include:

-Open reduction/internal fixation right tibia,
-Open reduction/internal fixation left tibia,
-Open reduction/internal fixation right fibula,
-Open reduction/internal fixation left fibula,
-Delayed open reduction/internal fixation left humerus,
-Delayed skin graft on left humerus

T+24hours - 22 days: Patient spends 16 days in intensive care and 6 days in intermediate care. This patient did not develop any complications during his acute care hospitalization.

T+ 22 days: Patient discharged from MIEMSS to an in-state rehabilitation hospital.

COGNITIVE-COMMUNICATIVE ASSESSMENT - CASE 129

The patient was initially evaluated on T + 2 days. The patient was found to have mild high level cognitive-communicative deficits (word fluency, letter organization). The patient had a Glasgow Coma Score of 15 and a Rancho Los Amigos Score of VII- VIII. The patient was reported to have decreased alertness possibly secondary to medication. Monitoring was recommended.

The patient was re-evaluated on T + 8 days in the specific deficit areas. Results indicated skills to be within normal limits. An RLAS VIII level was assigned with no further intervention indicated. The patient was able to ingest orally. Audiology assessed his hearing and diagnosed a mild hearing loss in the right ear.

PSYCHOSOCIAL FOLLOW-UP - CASE 129

6 Months

Forty-four (44)-year-old retired police officer was hospitalized 21 days in acute care and discharged to inpatient rehabilitation facility where he remained for 3 months; sent home with outpatient physical therapy for 1 month. Patient ambulating independently and determined to use arm in order to return to golf which was his way of life. Patient experiencing emotional outbursts, irritability, and memory problems.

1 Year

Patient has made remarkable physical progress and fully independent in all activities of daily living. His arm mobility has returned to about 85% and he has returned to amateur golfing, doing well. He continues to exhibit some memory gaps and family describes his condition as "dyslexia". He is in constant motion and keeps a frantic schedule. Previously described as "moderate" in behavior, eating, dress, and drinking, he now exhibits extreme behavior and drinking to excess. He began to drive 7 months

post-trauma and drinks while driving. Patient totally denies any problem with alcohol. Outbursts and irritability persist.

PREVENTION AND INJURY REDUCTION - CASE 129

Driver inattention might be the main reason that this crash occurred. A witness at the scene stated that our Case's right arm appeared to have been pinned near the center instrument panel. Upon inspection of the vehicle, no entrapment mechanism could be located in this area, and our Case sustained no injuries that would suggest that his right arm had been pinned. However, it is possible that our Case was adjusting the radio or climate controls at impact. This would have provided a distraction that might have led our Case to allow his vehicle to cross the centerline of the roadway.

The severe deformation to the case vehicle's left "A" pillar was the probable cause of our Case's left upper arm injury. The injury consisted of an open fracture of the proximal left humerus with an associated tissue avulsion. Follow-up suggests that there was also nerve damage to the left arm, and it is possible that this will be a long term, or even a permanently disabling injury. No definite evidence of occupant contact was noted to the left "A" pillar, however, the "A" pillar and roof were cut and modified by rescue personnel. Even in the modified condition, one can easily see the extent of the impact damage to the "A" pillar (crash team photo number 129-21).

The possibility was explored that our Case contacted the exterior of the other vehicle during impact. No evidence was found to support this idea. The probability is high that the case vehicle's intruded "A" pillar was the cause of our Case's severe arm injury. A stronger "A" pillar might have prevented this injury since our Case was using the available manual lap and shoulder belt. A stronger "A" pillar might also have prevented his ankle fracture that occurred as a result of toepan intrusion.

The manner in which our case used his shoulder harness may have contributed to his injuries. There was no positive evidence that he used the restraint improperly, however, the abrasions to his chest were unusual in that they indicate that our Case's left arm may have been positioned outside of the harness at impact. In other words, the shoulder strap may have been worn between our case's arm and chest with the strap being positioned in the arm pit. This configuration would have freed our Case's left shoulder and arm to move toward the impact. It would also have moved the shoulder harness down on his torso allowing his right clavicle to contact the steering rim.

--- Crash Investigation Team

COLLISION SCHEMATIC, CASE 129

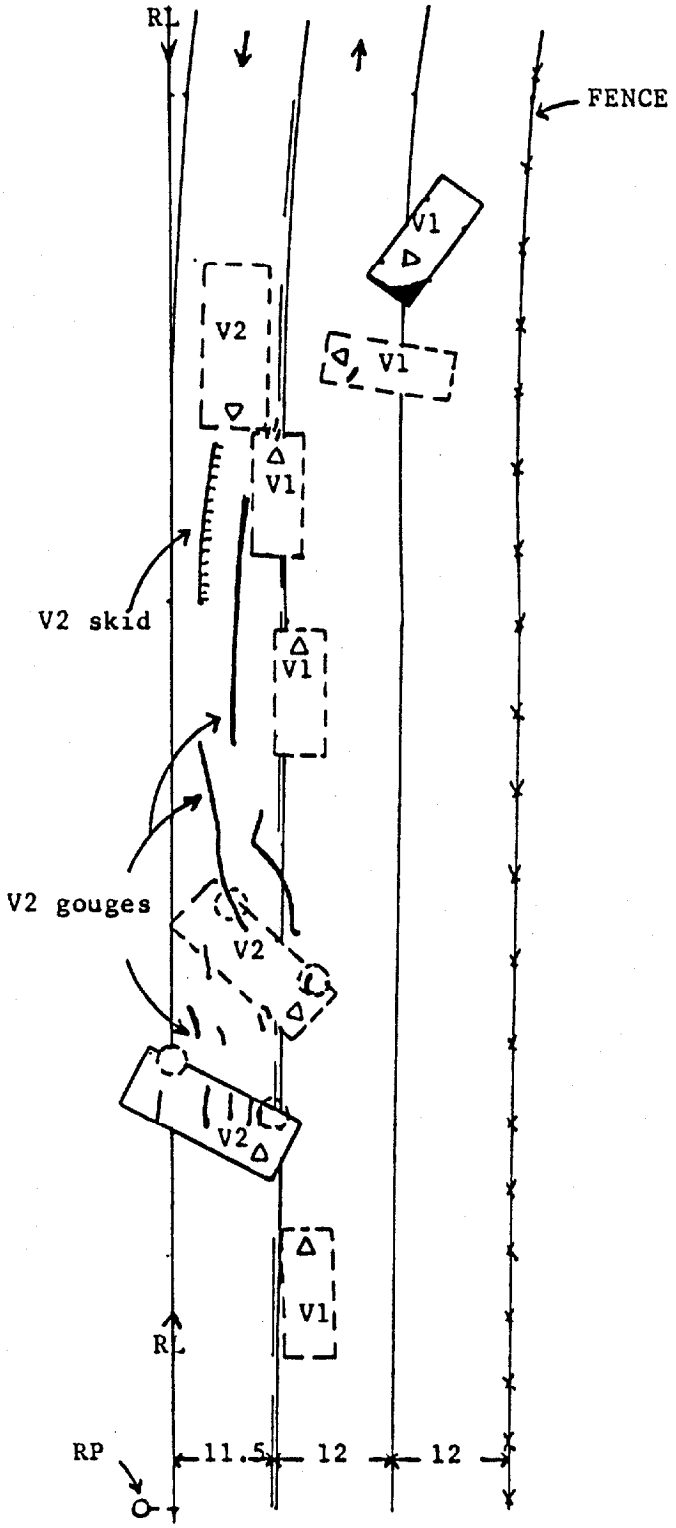

SCALE:

1" = 20'

VEHICLES:

V1 is a 1988 Honda Accord, 4 door sedan

V2 is a 1987 GMC 3500 passenger van (curb weight reported to be 10,500 pounds)

CURVE RADIUS:

1,042 feet

SELECTED PHOTOGRAPHS, CASE 129

1.



Scene. POI from V1's perspective. V1's FRP is to the right. POI is in the lower center of the photo.

2.



V1. A 1988 Honda Accord, 4 door sedan. Max crush = 31.9 inches at the left front bumper corner. Delta V = 26 to 32 miles per hour.

SELECTED PHOTOGRAPHS, CASE 129

3.



V1 driver's compartment. Contact to left instrument panel = AIS-3 left humerus fracture. Steering rim = AIS-2 right clavicle fracture. Lower column = AIS-2 right tibia fracture. Toepan = AIS-2 left trimalleolar fracture. Seatbelt = AIS-1 abrasions.

4.



V2. A 1987 GMC 3500 Vandura passenger van. Owner reported "work ready" curb weight = 10,500 pounds. Max crush about is 20 inches.

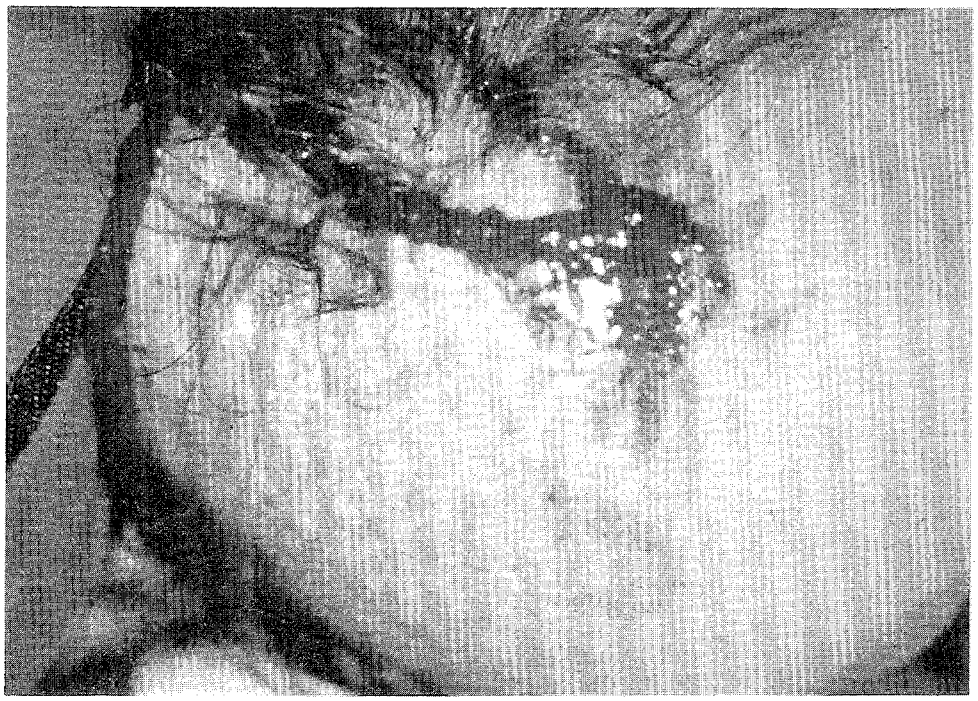

129-A **Admitting Area Photo:** Laceration Left Scalp (2cm)- Full Thickness

Contact Point--"A" Pillar
Type of Crash--Frontal Impact

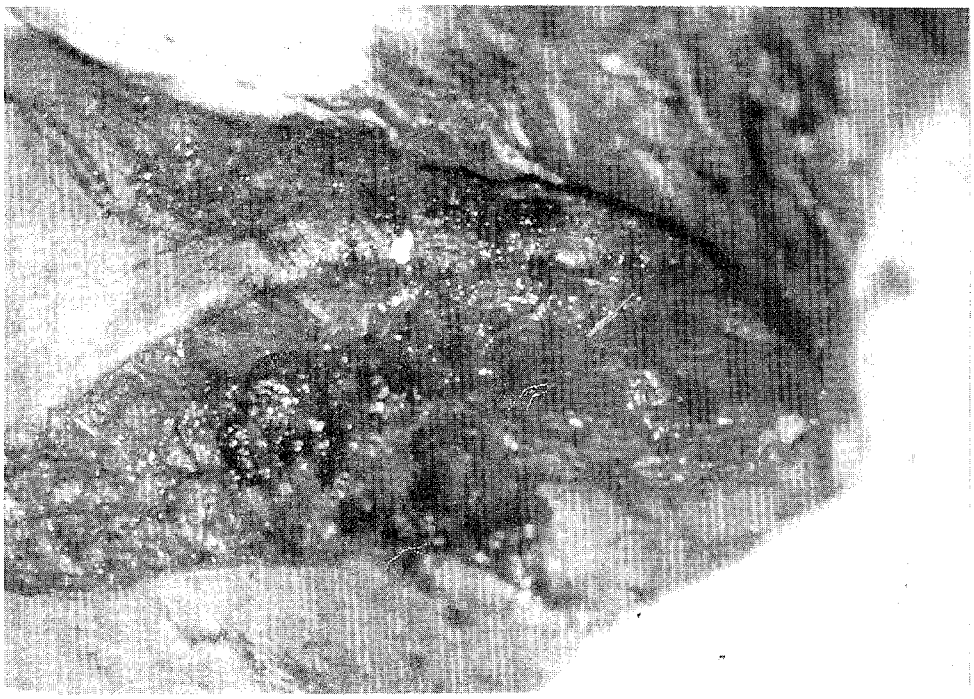

129-B **Admitting Area Photo:** Skin Avulsion Left Distal Upper Arm

Contact Point--Left Instrument Panel
Type of Crash--Frontal Impact

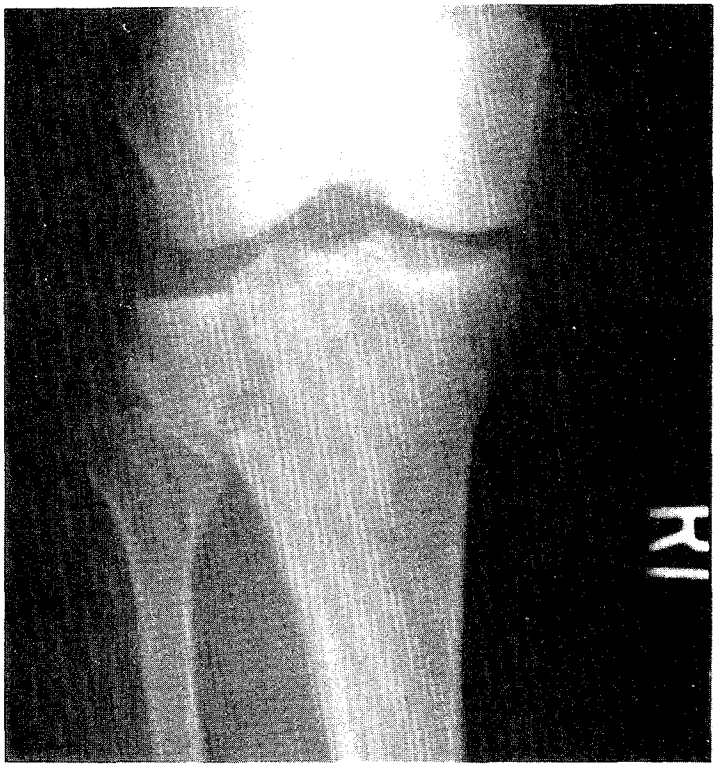

129-C **X-Ray Right Lower Extremity:** Fracture Right Tibial Plateau and Proximal Fibula

Contact Point--Lower Steering Column
Type of Crash--Frontal Impact

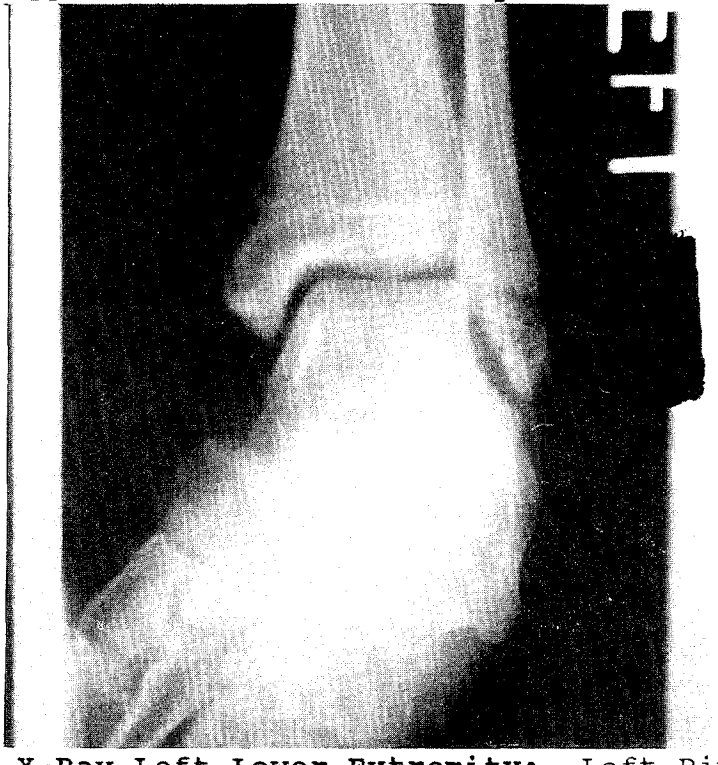

129-D **X-Ray Left Lower Extremity:** Left Bimalleolar Fracture

Contact Point--Left Toepan
Type of Crash--Frontal Impact

SUMMARY - CASE 356 (037)

This two vehicle accident occurred in the fall in a rural area. Vehicle 1, a 1983 Honda Civic 1300 3-door hatchback, was being driven southbound at a speed estimated to be between 53 and 65 miles per hour. The driver, an 18-year-old male, was not wearing the available lap/shoulder belt and the vehicle is not equipped with an air cushion restraint system. Vehicle 2, a 1972 Chevrolet C-10 pickup, was being driven northbound at a speed estimated to be between 33 and 41 miles per hour. The driver, a 58-year-old male, was not wearing the available lap belt and this vehicle is not equipped with an air cushion restraint system.

The driver of Vehicle 1 was southbound on a 2-lane asphalt paved road in a rural environment. The road was wet with a coefficient of friction estimated at .50, with standing water on some portions of the road and shoulders. As the driver and vehicle departed the south end of a bridge, a slight depression in the roadway with standing water approximately one inch deep was encountered and the driver lost control due to hydroplaning. The condition of the vehicle's two front tires, almost bald, contributed to this loss of control. The driver of Vehicle 2 took evasive action consisting of turning right onto the shoulder but was unable to avoid the impact with Vehicle 1.

At impact, frontal plane to frontal plane, Vehicle 1 sustained a total of 58.0 inches of direct and induced damage and a maximum crush of 56.25 inches located at C6 - the right front bumper corner. The forces involved in this impact shortened the normal 88.6 inch wheel base to 55.7 inches (32.9 inch reduction). The delta-V for Vehicle 1 was computed using Crash III PC as 59.3 miles per hour with a principal direction of force of 025 degrees. Driver contact points had been contaminated by debris or erased by the rain occurring as the roof was removed for occupant extraction. Our case occupant/driver sustained multiple lacerations to the face and a contusion to the scalp as a result of the unbelted driver striking the windshield. The fractures of the left humerus, right ulnas and femur were probably caused when intrusion to the floor area and instrument panel occurred. This driver was pinned in the vehicle by sheet metal and required 45 minutes to extricate. The ruptured spleen was attributed to contact with the steering wheel. The driver was transported to a major shock trauma unit and admitted for further treatment. Vehicle 2 sustained 76.0 inches of direct and induced damage and a maximum crush of 20.0 inches. The delta-V for Vehicle 2 was 25.5 miles per hour with a principal direction of force of 010 degrees. The driver of Vehicle 2 sustained non-capacitating injuries and was also transported to a hospital.

BODY CONTACTS & INJURY TABLE -- CASE 356

18 year old male; Driver; 1983 Honda Civic; Frontal impact

OIC/AIS CODE	ICD-9	BODY CONTACTS & INJURIES	CONTACT POINT
1. FSLI2 011111	873.42	Laceration, Forehead	Windshield
2. FCLI2 011111	873.30	Laceration, Nose	Windshield

3.	FRLO2	011111	870.0	Laceration, Right Eyelid	Windshield
4.	FRLI2	011111	873.41	Laceration, Right Cheek	Windshield
5.	FSCI2	011111	920.	Contusion, Scalp	Windshield
6.	ALFS2	061111	812.21	Fracture, Left Humerus-Midshaft	Steering Wheel Combination
7.	RRFS3	101111	813.82	Fracture, Right Ulna-Comminuted	Ctr. Instrument Panel & Below
8.	TRFS3	101111	821.01	Fracture, Right Femur-Midshaft	Ctr. Instrument Panel & Below
9.	WRAI1	911211	914.0	Abrasions, Multiple, Right Hand	Flying Glass
10.	WRLI1	911211	882.0	Lacerations, Multiple, Right Hand	Flying Glass
11.	WRLI2	912211	883.0	Laceration, Right Metacarpal	Flying Glass
12.	MLRQ4	061111	865.04	Ruptured Spleen	Steering Wheel Combination

CRASH TIMELINE - CASE 356

T - 5.0 Seconds: Vehicle 1, a 1983 Honda Civic 1300 3-door hatchback, was southbound on a 2 lane, asphalt paved road in a rural environment. The driver, an 18 year old male, was not wearing the available lap/shoulder belt and the vehicle is not equipped with an air cushion restraint system. Vehicle 2, a 1972 Chevrolet C-10 pickup, was being driven northbound at a speed estimated between 33 and 41 miles per hour by a 58 year old male. This driver was not wearing the available lap belt and the vehicle is not equipped with an air cushion restraint system.

T - 2.0 Seconds (estimate): Vehicle 1, exited the south end of a bridge and travelled onto a depressed section of the roadway which had approximately 1.0" of standing water. Control of Vehicle 1, was lost as the vehicle began hydroplaning. The condition of the front tires, "bald", contributed to the hydroplaning action.

T 0.0 Seconds: Vehicle 1 was struck by Vehicle 2, frontal plane to frontal plane. Intrusion into the driver/front seat positions pinned the driver as the instrument panel was displaced rearward and downward. Direct and induced damage was 58.0 inches with a maximum crush of 56.25 inches located at C6, the right front bumper corner. The forces involved also shortened the wheel base from the normal 88.6 to 55.7 inches (32.9 inches) on the right side. Vehicle 2 sustained 76.0 inches of direct and induced damage and a maximum crush of 20.0 inches located at the

right front bumper. Vehicle 1's forward motion was overcome by Vehicle 2 and pushed rearward approximate 10.0". Intrusion of the instrument panel, 9.0" longitudinally and vertically pinned the driver in the vehicle requiring the removal of the roof and the cutting of other sheet metal components. The case occupant sustained multiple facial lacerations and abrasions and a scalp contusion as a probable result of striking the windshield and subsequent glass contact during impact. As the instrument panel was intruded rearward and downward, the toe pan was intruded rearward causing the reported fractured left humerus and right femur. The right ulnas fracture probably was caused by steering wheel and instrument panel contact. The ruptured spleen was attributed to steering wheel assembly contact.

T + 1.10 Seconds (estimated): Vehicle 2 pushed Vehicle 1 rearward approximately 10 feet in a counterclockwise rotational slide. Both vehicles 1 and 2 came to final rest facing the east side of the road partially on the improved shoulder.

T + 9:00 Minutes: The police were notified.

T + 12:00 Minutes: The police arrived and started investigative and medical relief efforts.

T + 45:00 Minutes (estimate): The driver of Vehicle 1 was extricated from the vehicle and taken to a major trauma hospital for admittance and further treatment.

PREHOSPITAL AND HOSPITAL TIMELINE - CASE 356

T+ 1min: Ambulance receives call to respond.

T+ 10min: Ambulance arrives at scene. Initial field assessment reveals a blood pressure of 136/palp., a heart rate of 120, a respiratory rate was not obtained, and a Glasgow Coma Score of 15. Prehospital care includes fluid resuscitation with the administration of 500 cc of crystalloid. The patient was trapped for 45 minutes and required extrication from the vehicle.

T+ 71min: Patient departs scene for MIEMSS/Shock Trauma by ground ambulance.

T+ 91min: Patient arrives at MIEMSS. Initial physiologic assessment of the patient reveals a blood pressure of 80/palp., a heart rate of 130, a respiratory rate of 26, and a Glasgow Coma Score of 15. The patient's ISS (Injury Severity Score) = 26. Toxicology screen results were negative.

Initial hospital care provided includes:

- -Evaluation by a MIEMSS trauma team,
- -Fluid resuscitation,
- -Diagnostic peritoneal lavage with grossly positive results,
- -Full diagnostic evaluation including x-rays of the cervical spine, chest and pelvis. In addition to the toxicology screen, an arterial blood gas, a CBC (complete blood count), an SMA-6 (routine blood chemistry) and UA (urinalysis) were performed.

Initial clinical findings included the following:

-Right and left frontal scalp contusions
-Right eyelid contusion
-Minor avulsion of nasal tissue
-Fracture left humerus (transverse, middle 1/3)
-Fracture right ulna (transverse, middle 1/3)
-Fracture right femur (transverse, upper 1/3)
-Right pneumothorax
-Tear of the cecum
-Laceration of spleen

Operative procedures include:

-Intramedullary rodding of left humerus
-Intramedullary rodding of right ulna
-Intramedullary rodding of right femur

T+24hours - 17 days: Patient spends 9 days in intensive care and 8 days in intermediate care. No complications were reported during the acute care hospitalization of this patient.

T+ 17 days: Patient discharged from MIEMSS to home unable to ambulate.

COGNITIVE-COMMUNICATIVE ASSESSMENT - CASE 356

The patient was evaluated on T + 8 days. The patient was verbal and appeared appropriate. the patient was able to respond to the assessment protocol. All areas assessed (auditory & written comprehension, veral expression, speech and cognition) were within normal limits. Written expression could not be assessed due to a right arm injury. The patient had a Rancho Los Amigos Score of VIII and a Glasgow Coma Score of 15. Swallowing and hearing skills were within normal limits as well. No further follow-up was indicated.

PSYCHOSOCIAL FOLLOW-UP - CASE 356

6 Months

Eighteen (18)-year-old high school graduate discharged home with outpatient physical therapy, which is continuing at 6 months. Patient ambulatory and independent in activities of daily living. Extensive therapy required for patient to regain full use of arm but patient working hard to accomplish this. Patient dropped out of college due to physical limitations and continuing therapy. Patient bored at home, experiencing depressive episodes.

1 Year

Patient dropped out of college this past year, returning to his studies at 1 year post-trauma. Function of arm has almost fully returned. Both patient and mother involved in advocacy issues around safe driving. Patient doing well and gradually making return to pre-injury activities. Skin grafts have prevented his return to sailing at present.

CRASH PREVENTION AND INJURY REDUCTION - CASE 356

This accident occurred as a result of speed which was too fast for both environmental and mechanical conditions. The case's vehicle, a 1983 Honda Civic, had 2 almost treadless front tires. The roadway at the accident site was engineered in a manner which allowed water to stand across the lanes to a depth of .5 inches or more in the event of rain. This combination of circumstances coupled with the speed at which our case driver entered a right hand curve, resulted in his vehicle hydroplaning and crossing into oncoming traffic. Yearly vehicle inspections would probably have caught this tire condition and made the owner correct it prior to the continued use of the vehicle.

The installation of air bags and automatic restraint systems would have probably lessened the severity of our case's injuries. Intrusion was noted and believed to have caused entrapment of our case. Increased occupant compartment protection measures such as stiffening panels may have reduced or eliminated the entrapment.

--The Crash Investigation Team

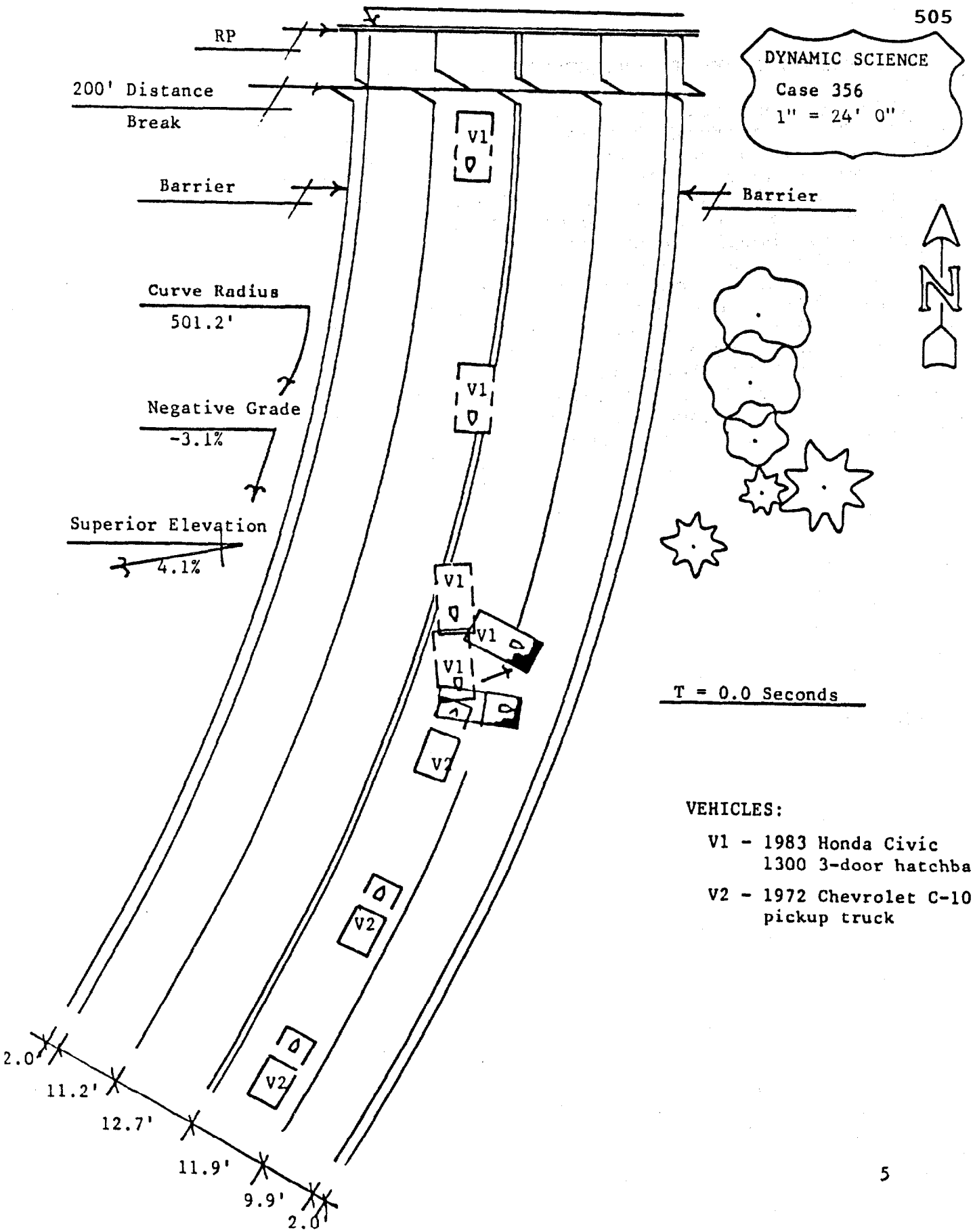

VEHICLES:

V1 - 1983 Honda Civic
1300 3-door hatchback

V2 - 1972 Chevrolet C-10
pickup truck

SELECTED PHOTOGRAPHS, CASE 356

356-02

1.



Scene; V1's southbound direction of travel toward point of impact at far side of bridge.

2.



Scene; Impact area with Vehicle 2.

SELECTED PHOTOGRAPHS, CASE 356

3.



V1 and V2 shown in approximate impact positions. V2 - 1972 Chevrolet C-10 pickup.

4.

V1-1983 Honda Civic 1300 3-door Hatchback; frontal plane to frontal plane impact. Direct & induced damage-58" and maximum crush of 56.25" at C6 (right front bumper).

SELECTED PHOTOGRAPHS, CASE 356

5.



1" of standing water on roadway in combination with V1's bald tires caused hydroplaning and loss of vehicular control.

6.



Driver was pinned by sheet metal and required 45 minutes to extricate. Contact points were eradicated by rain and debris.

356-A **Admitting Area Photo:** Multiple Lacerations to Right Forehead, Nose, Eyelid, and Cheek***

Contact Point--Windshield
Type of Crash--Frontal Impact

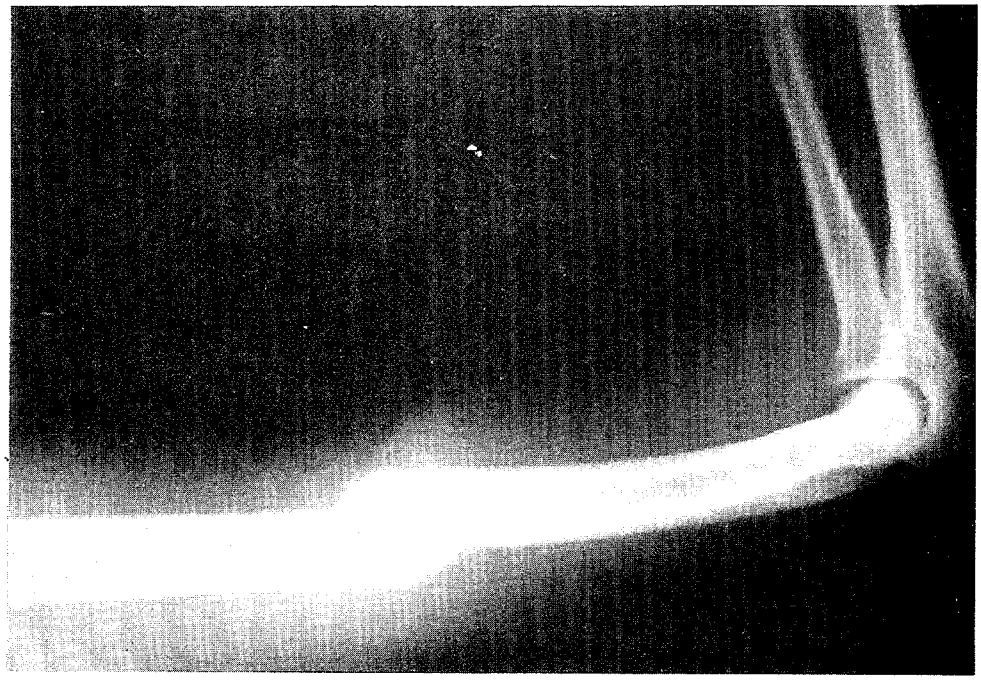

356-B **X-Ray Left Upper Extremity:** Fracture Mid-Shaft Left Humerus, Closed

Contact Point--Steering Wheel Combination
Type of Crash--Frontal Impact

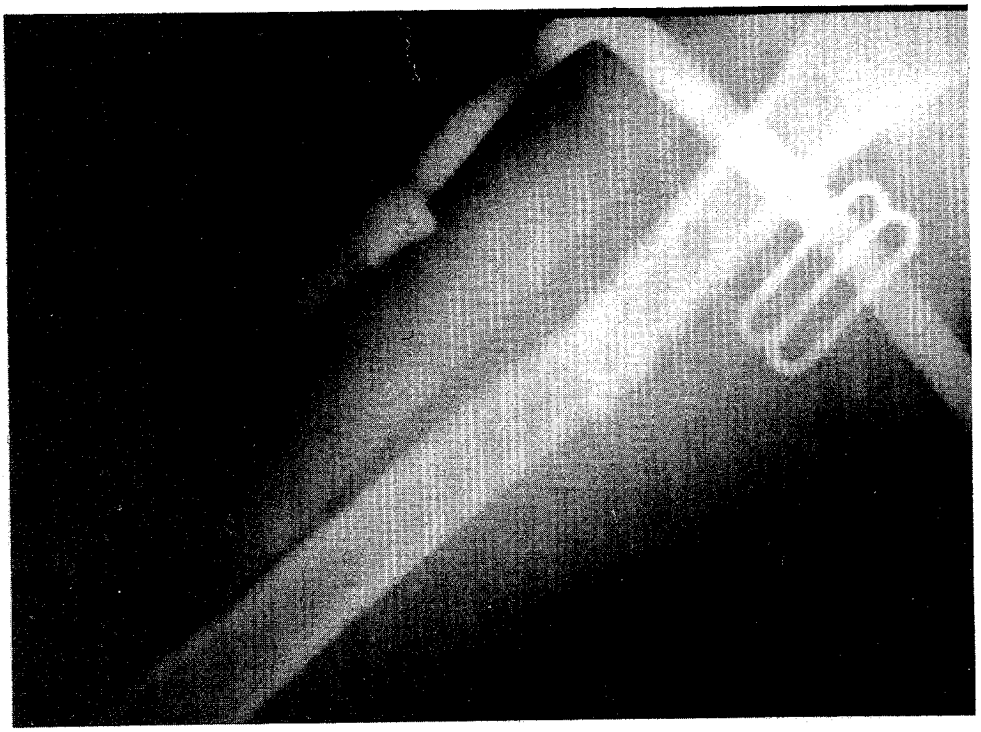

356-C **X-Ray Right Femur:** Fracture Mid-Shaft Right Femur

Contact Point--Center Instrument Panel and Below
Type of Crash--Frontal Impact

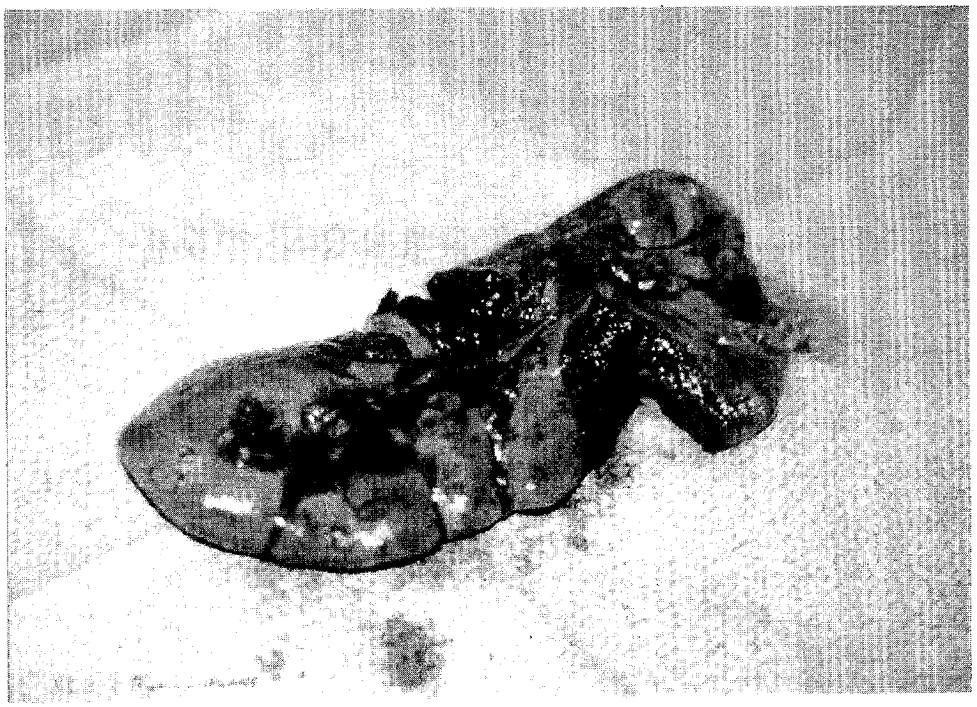

356-D **Intraoperative Photo:** Ruptured Spleen

Contact Point--Steering Wheel Combination
Type of Crash--Frontal Impact

☆ U.S. GOVERNMENT PRINTING OFFICE: 1994 — 524- 176/ 81415